



**UnitedHealthcare® Community Plan: *Radiology Imaging Coverage Determination Guideline***

**Pediatric Oncology Imaging  
Guidelines (For Ohio Only)**

**V1.0.2023**

**Guideline Number: CSRAD021OH.A**

**Effective Date: June 1, 2023**

**Application (for Ohio Only)**

*This Medical Policy only applies to the state of Ohio. Any requests for services that are stated as unproven or services for which there is a coverage or quantity limit will be evaluated for medical necessity using Ohio Administrative Code 5160-1-01.*

Pediatric Oncology Imaging Guidelines (For Ohio Only): CSRAD012OH.A      Effective June 1, 2023  
UnitedHealthcare Community Plan Coverage Determination Guideline      Page 1 of 214  
Proprietary Information of United Healthcare. Copyright © 2023 United HealthCare Services, Inc.

# Table of Contents

## Guideline

---

### **Related Community Plan Policies Application (For Ohio Only)**

**Guideline Development (Preface-1)**  
**Benefits, Coverage Policies, and Eligibility Issues (Preface-2)**  
**Clinical Information (Preface-3)**  
**Coding Issues (Preface-4)**  
**Whole Body Imaging (Preface-5)**  
**References (Preface-6)**  
**Copyright Information (Preface-7)**  
**Trademarks (Preface-8)**

### **Pediatric and Special Populations Oncology Imaging Guidelines**

#### **Abbreviations for Pediatric and Special Populations Oncology Imaging Guidelines**

**General Guidelines (PEDONC-1)**  
**Screening Imaging in Cancer Predisposition Syndromes (PEDONC-2)**  
**Pediatric Leukemias (PEDONC-3)**  
**Pediatric CNS Tumors (PEDONC-4)**  
**Pediatric Lymphomas (PEDONC-5)**  
**Neuroblastoma (PEDONC-6)**  
**Pediatric Renal Tumors (PEDONC-7)**  
**Pediatric Soft Tissue Sarcomas (PEDONC-8)**  
**Bone Tumors (PEDONC-9)**  
**Pediatric Germ Cell Tumors (PEDONC-10)**  
**Pediatric Liver Tumors (PEDONC-11)**  
**Retinoblastoma (PEDONC-12)**  
**Pediatric Nasopharyngeal Carcinoma (PEDONC-13)**  
**Pediatric Adrenocortical Carcinoma (PEDONC-14)**  
**Pediatric Melanoma and Other Skin Cancers (PEDONC-15)**  
**Pediatric Salivary Gland Tumors and Thyroid Tumors (PEDONC-16)**  
**Pediatric Breast Masses (PEDONC-17)**  
**Histiocytic Disorders (PEDONC-18)**  
**Long Term Pediatric Cancer Survivors (PEDONC-19)**

### **Policy History and Instructions for Use**

# Related Community Plan Policies

Related Community Plan Policies  
v1.0.2023

## General Policies

- General Oncology Imaging Guidelines
- General Musculoskeletal Imaging Guidelines

## Pediatric Policies

- Pediatric Musculoskeletal Imaging Guidelines
- Pediatric Cardiac Imaging Guidelines

# Application (For Ohio Only)

---

## Guideline

---

Application (for Ohio only)

# Application (For Ohio Only)

---

Application for Ohio OH UHC  
v1.0.2023

- This Medical Policy only applies to the state of Ohio. Any requests for services that are stated as unproven or services for which there is a coverage or quantity limit will be evaluated for medical necessity using Ohio Administrative Code 5160-1-01.

Application (For Ohio Only)

# Guideline Development (Preface-1)

---

## Guideline

---

Guideline Development (Preface-1.1)

# Guideline Development (Preface-1.1)

PRF.GG.0001.1.UOH

v1.0.2023

- The UnitedHealthcare's evidence-based, proprietary clinical guidelines evaluate a range of advanced imaging and procedures, including NM, US, CT, MRI, PET, Radiation Oncology, Sleep Studies, as well as Cardiac, musculoskeletal and Spine interventions.
- UnitedHealthcare reserves the right to change and update the guidelines. The guidelines undergo a formal review annually. United HealthCare's guidelines are based upon major national and international association and society guidelines and criteria, peer-reviewed literature, major treatises as well as, input from health plans, and practicing academic and community-based physicians.
- These Guidelines are not intended to supersede or replace sound medical judgment, but instead, should facilitate the identification of the most appropriate imaging or other designated procedure given the individual's clinical condition. These guidelines are written to cover medical conditions as experienced by the majority of individuals. However, these guidelines may not be applicable in certain clinical circumstances, and physician judgment can override the guidelines.
- Clinical decisions, including treatment decisions, are the responsibility of the individual and his/her provider. Clinicians are expected to use independent medical judgment, which takes into account the clinical circumstances to determine individual management decisions.
- UnitedHealthcare supports the Choosing Wisely initiative (<https://www.choosingwisely.org/>) by the American Board of Internal Medicine (ABIM) Foundation and many national physician organizations, to reduce the overuse of diagnostic tests that are low value, no value, or whose risks are greater than the benefits.

# Benefits, Coverage Policies, and Eligibility Issues (Preface-2)

---

## Guideline

---

Benefits, Coverage Policies, and Eligibility Issues (Preface-2.1)

References (Preface-2)



# Benefits, Coverage Policies, and Eligibility Issues (Preface-2.1)

---

PRF.BC.0002.1.UOH

v1.0.2023

## **Investigational and Experimental Studies**

- Certain advanced imaging studies, or other procedures, may be considered investigational and experimental if there is a paucity of supporting evidence; if the evidence has not matured to exhibit improved health parameters or; the advanced imaging study/procedure lacks a collective opinion of support.

## **Clinical and Research Trials**

- Similar to investigational and experimental studies, clinical trial imaging requests will be considered to determine whether they meet UnitedHealthcare's evidence-based guidelines.
- Imaging studies which are inconsistent with established clinical standards, or are requested for data collection and not used in direct clinical management are not supported.

## **Legislative Mandate**

- State and federal legislations may need to be considered in the review of advanced imaging requests.

# References (Preface-2)

---

**v1.0.2023**

1. Coverage of Clinical Trials under the Patient Protection and Affordable Care Act; 42 U.S.C.A. § 300gg-8

# Clinical Information (Preface-3)

---

## Guideline

---

Clinical Information (Preface-3.1)

References (Preface-3)

# Clinical Information (Preface-3.1)

PRF.CL.0003.1.UOH

v1.0.2023

## Clinical Documentation and Age Considerations

- UnitedHealthcare’s guidelines use an evidence-based approach to determine the most appropriate procedure for each individual, at the most appropriate time in the diagnostic and treatment cycle. UnitedHealthcare’s guidelines are framed by:
  - Clinical presentation of the individual, rather than the studies requested
  - Adequate clinical information that must be submitted to UnitedHealthcare in order to establish medical necessity for advanced imaging or other designated procedures includes, but is not limited to the following:
    - Pertinent clinical evaluation should include a recent detailed history, physical examination<sup>20</sup> since the onset or change in symptoms, and/or laboratory and prior imaging studies.
      - Condition-specific guideline sections may describe additional clinical information which is required for a pertinent clinical evaluation.
      - The Spine and Musculoskeletal guidelines require x-ray studies from when the current episode of symptoms has started or changed; x-ray imaging does not have to be within the past 60 days.
      - Advanced imaging or other designated procedures should not be ordered prior to clinical evaluation of an individual by the physician treating the individual. This may include referral to a consultant specialist who will make further treatment decisions.
      - Other meaningful technological contact (telehealth visit, telephone or video call, electronic mail or messaging) since the onset or change in symptoms by an established individual can serve as a pertinent clinical evaluation.
        - Some conditions may require a face-to-face evaluation as discussed in the applicable condition-specific guideline sections.
    - A recent clinical evaluation may be unnecessary if the individual is undergoing a guideline-supported, scheduled follow-up imaging or other designated procedural evaluation. Exceptions due to routine surveillance indications are addressed in the applicable condition-specific guideline sections.
  - UnitedHealthcare’s evidence-based approach to determine the most appropriate procedure for each individual requires submission of medical records pertinent to the requested imaging or other designated procedures.

- Many conditions affecting the pediatric population are different diagnoses than those occurring in the adult population. For those diseases which occur in both pediatric and adult populations, minor differences may exist in management due to individual age, comorbidities, and differences in disease natural history between children and adults.
  - Individuals who are 18 years old or younger<sup>19</sup> should be imaged according to the Pediatric Imaging Guidelines if discussed in the condition-specific guideline sections. Any conditions not specifically discussed in the Pediatric Imaging Guidelines should be imaged according to the General Imaging Guidelines. Individuals who are >18 years old should be imaged according to the General Imaging Guidelines, except where directed otherwise by a specific guideline section.
- The terms “male” and “female” used in these guidelines refer to anatomic-specific diseases and disease predispositions associated with individuals’ sex assigned at birth rather than their gender identity. It should be noted that gender identity and anatomic-specific diseases as well as disease predispositions are not always linked. As such, these guidelines should be applied to the individual’s corresponding known or suspected anatomic-specific disease or disease predisposition. At UnitedHealthcare, we believe that it is important to understand how all individuals, including those who are gender-diverse, choose to identify themselves. To ensure that gender-diverse individuals are treated with respect and that decisions impacting their healthcare are made correctly and with sensitivity, UnitedHealthcare recognizes all individuals with the following gender marker options: Male, Female, Transgender male, Transgender female, “X,” and “Not specified.”

### **General Imaging Information**

- “Standard” or “conventional” imaging is most often performed in the initial and subsequent evaluations of malignancy. Standard or conventional imaging includes plain film, CT, MRI, or US.
  - Often, further advanced imaging is needed when initial imaging, such as ultrasound, CT, or MRI does not answer the clinical question. Uncertain, indeterminate, inconclusive, or equivocal may describe these situations.
- Appropriate use of contrast is a very important component of evidence-based advanced imaging use.
  - The appropriate levels of contrast for an examination (i.e. without contrast, with contrast, without and with contrast) is determined by the evidence-based guidance reflected in the condition-specific guideline sections.
  - If, during the performance of a non-contrast imaging study, there is the unexpected need to use contrast in order to evaluate a possible abnormality, then that is appropriate.<sup>1</sup>

## **Ultrasound**

- Diagnostic ultrasound uses high frequency sound waves to evaluate soft tissue structures and vascular structures utilizing greyscale and Doppler techniques.
- Ultrasound allows for dynamic real-time imaging at the bedside
  - Ultrasound is limited in areas where there is dense bone or other calcification.
  - Ultrasound also has a relatively limited imaging window so may be of limited value to evaluate very large abnormalities
  - In general, ultrasound is highly operator-dependent, and proper training and experience are required to perform consistent, high-quality evaluations.
- Indications for ultrasound may include, but are not limited to:
  - Obstetric and gynecologic imaging
  - Soft tissue and visceral imaging of the chest, abdomen, pelvis, and extremities
  - Brain and spine imaging when not obscured by dense bony structures
  - Vascular imaging when not obscured by dense bony structures
  - Procedural guidance when not obscured by dense bony structures
  - Initial evaluation of ill-defined soft tissue masses or fullness and differentiating adenopathy from mass or cyst. Prior to advanced imaging, ultrasound can be very beneficial in selecting the proper modality, body area, image sequences, and contrast level that will provide the most definitive information for the individual.
- More specific guidance for ultrasound usage, including exceptions to this general guidance, can be found throughout the condition-specific guidelines.

### **Computed Tomography (CT):**

- The AMA CPT® manual does not describe nor assign any minimum or maximum number of sequences for any CT study. CT imaging protocols are often influenced by the individual clinical situation of the individual and additional sequences are not uncommon. There are numerous CT protocols that may be performed to evaluate specific clinical questions, and this technology is constantly undergoing development.
- CT utilizes ionizing radiation to create cross-sectional and volumetric images of the body.
  - Advantages over ultrasound include a much larger field of view, and faster completion time in general. Disadvantages compared to ultrasound include lack of portability and exposure to ionizing radiation.
  - Advantages over MRI include faster imaging, and a more spacious scanner area limiting claustrophobia. Disadvantages compared to MRI include decreased soft tissue definition, especially with non-contrast imaging, and exposure to ionizing radiation.

- CT can be performed without, with, or without and with intravenous (IV) contrast depending on the clinical indication and body area.
  - In general, non-contrast imaging is appropriate for evaluating structures with significant tissue density differences such as lung parenchyma and bony structures, or when there is a contraindication to contrast.
  - In general, CT with contrast is the most common level of contrast and can be used when there is need for improved vascular or soft tissue resolution, including better characterization of known or suspected malignancy, as well as, infectious and inflammatory conditions.
  - CT without and with contrast has a limited role as the risks of doubling the ionizing radiation exposure rarely outweigh the benefits of multiphasic imaging, though there are some exceptions which include but are not limited to:
    - Characterization of a mass
    - Characterization of arterial and venous anatomy
    - CT with contrast may be used to better characterize findings on a very recent (within two weeks) inconclusive non-contrast CT where the guidelines would support CT without and with contrast.
  - More specific guidance for CT contrast usage, including exceptions to this general guidance can be found throughout the condition-specific guidelines.
- Shellfish allergy:
  - It is commonly assumed that an allergy to shellfish indicates iodine allergy, and that this implies an allergy to iodinated contrast media used with CT. However, this is NOT true. Shellfish allergy is due to tropomyosins. Iodine plays no role in these allergic reactions. Allergies to shellfish do not increase the risk of reaction to iodinated contrast media any more than that of other allergens.<sup>1</sup>
- Enteric contrast (oral or rectal) is sometimes used in abdominal imaging. There is no specific CPT<sup>®</sup> code which refers to enteric contrast.
- The appropriate contrast level and anatomic region in CT imaging is specific to the clinical indication, as listed in the condition-specific guideline sections.
- CT should not be used to replace MRI in an attempt to avoid sedation unless it is listed as a recommended study the appropriate condition-specific guideline.
- There are significant potential adverse effects associated with the use of iodinated contrast media. These include hypersensitivity reactions, thyroid dysfunction, and contrast-induced nephropathy (CIN). Individuals with impaired renal function are at increased risk for CIN.<sup>2</sup>
- Both contrast CT and MRI may be considered to have the same risk profile with renal failure (GFR <30 mL/min).
- The use of CT contrast should proceed with caution in pregnant and breastfeeding individuals. There is a theoretical risk of contrast toxicity to the fetal and infant thyroid. The procedure can be performed if the specific need for that contrast-enhanced procedure outweighs risk to the fetus. Breastfeeding individuals may reduce this risk by choosing to pump and discard breast milk for 12-24 hours after the contrast injection.

- CT without contrast may be appropriate if clinical criteria for CT with contrast are met AND the individual has:
  - Elevated blood urea nitrogen (BUN) and/or creatinine
  - Renal insufficiency
  - Allergies to iodinated contrast
  - Thyroid disease which could be treated with I-131
  - Diabetes
  - Very elderly
  - Urgent or emergent settings due to availability
  - Trauma
- CT is superior to other imaging modalities in certain conditions, including but not limited to the following:
  - Screening following trauma
  - Imaging pulmonary disease
  - Imaging abdominal and pelvic viscera
  - Imaging of complex fractures
  - Evaluation of inconclusive findings on Ultrasound or MRI, or if there is a contraindication to MRI
- More specific guidance for CT usage, including exceptions to this general guidance can be found throughout the condition specific guidelines.

#### **Magnetic Resonance Imaging (MRI):**

- The AMA CPT® manual does not describe nor assign any minimum or maximum number of sequences for any MRI study. MRI protocols are often influenced by the individual clinical situation of the individual and additional sequences are not uncommon. There are numerous MRI sequences that may be performed to evaluate specific clinical questions, and this technology is constantly undergoing development.
- Magnetic Resonance Imaging (MRI) utilizes the interaction between the intrinsic radiofrequency of certain Molecules in the body (hydrogen in most cases) and a strong external magnetic field.
  - MRI is often superior for advanced imaging of soft tissues and can also define physiological processes in some instances [e.g. edema, loss of circulation (AVN), and increased vascularity (tumors)].
  - MRI does not use ionizing radiation, and even non-contrast images have much higher soft tissue definition than CT or Ultrasound
  - MRI typically takes much longer than either CT or Ultrasound, and for some individuals may require sedation. It is also much more sensitive to individual motion that can degrade image quality than either CT or Ultrasound.
- MRI Breast and MRI Chest are not interchangeable, as they focus detailed sequences on different adjacent body parts.
- MRI may be utilized either as the primary advanced imaging modality, or when further definition is needed based on CT or ultrasound imaging.



- Most orthopedic and dental implants are not magnetic. These include hip and knee replacements; plates, screws, and rods used to treat fractures; and cavity fillings. Yet, all of these metal implants can distort the MRI image if near the part of the body being scanned.
  - Other implants, however, may have contraindications to MRI. These include:
    - Pacemakers
    - ICD or heart valves
    - Metal implants in the brain
    - Metal implants in the eyes or ears
    - Infusion catheters and bullets or shrapnel.
  - CT can therefore be an alternative study to MRI in these scenarios.
- The contrast level and anatomic region in MRI imaging is specific to the clinical indication, as listed in the specific guideline sections.
- MRI is commonly performed without, without and with contrast.
  - Non-contrast imaging offers excellent tissue definition
  - Imaging without and with contrast is commonly used when needed to better characterize tissue perfusion and vascularization.
    - Most contrast is gadolinium based and causes T2 brightening of the vascular and extracellular spaces.
    - Some specialized gadolinium and non-gadolinium contrast agents are available, and most commonly used for characterizing liver lesions.
  - MRI with contrast only is rarely appropriate and is usually used to better characterize findings on a recent inconclusive non-contrast MRI, commonly called a completion study.
  - MRI contrast is contraindicated in pregnant individuals
  - More specific guidance for MRI contrast usage, including exceptions to this general guidance can be found throughout the condition specific guidelines.
- MRI may be preferred in individuals with renal failure, and in individuals allergic to intravenous CT contrast.
  - Both contrast CT and MRI may be considered to have the same risk profile with renal failure (GFR <30 mL/min).<sup>2</sup>
  - Gadolinium can cause Nephrogenic Systemic Fibrosis (NSF). The greater the exposure to gadolinium in individuals with a low GFR (especially if on dialysis), the greater the chance of individuals developing NSF.
  - Multiple studies have demonstrated potential for gadolinium deposition following the use of gadolinium-based contrast agents (GBCAs) for MRI studies.<sup>3,4,5,6,7</sup> The U.S. Food and Drug Administration (FDA) has noted that there is currently no evidence to suggest that gadolinium retention in the brain is harmful and restricting gadolinium-based contrast agents (GBCAs) use is not warranted at this time. It has been recommended that GBCA use should be limited to circumstances in which additional information provided by the contrast agent is necessary and the necessity of repetitive MRIs with GBCAs should be assessed.<sup>8</sup>

- A CT may be approved in place of an MRI when clinical criteria are met for MRI AND there is a contraindication to having an MRI (pacemaker, ICD, insulin pump, neurostimulator, etc.)
  - When replacing MRI with CT, contrast level matching should occur as follows:
    - MRI without contrast → CT without contrast
    - MRI without and with contrast → CT with contrast or CT without and with contrast
- The following situations may impact the appropriateness for MRI and or MR contrast
  - Caution should be taken in the use of gadolinium in individuals with renal failure
  - The use of gadolinium contrast agents is contraindicated during pregnancy unless the specific need for that procedure outweighs risk to the fetus.
  - MRI can be performed for non-ferromagnetic body metals (i.e. titanium), although some imaging facilities will consider it contraindicated if recent surgery, regardless of the metal type
- MRI should not be used as a replacement for CT for the sole reason of avoidance of ionizing radiation when MRI is not supported in the condition-based guidelines, since it does not solve the problem of overutilization.
- MRI is superior to other imaging modalities in certain conditions, including but not limited to the following:
  - Imaging the brain and spinal cord
  - Characterizing visceral and musculoskeletal soft tissue masses
  - Evaluating musculoskeletal soft tissues including ligaments and tendons
  - Evaluating inconclusive findings on ultrasound or CT
  - Individuals who are pregnant or have high radiation sensitivity
  - Suspicion, diagnosis of or surveillance of infections
- More specific guidance for MRI usage, including exceptions to this general guidance can be found throughout the condition-specific guidelines.

### **Positron Emission Tomography (PET):**

- PET is a nuclear medicine study that uses a positron emitting radiotracer to create cross-sectional and volumetric images based on tissue metabolism.
- Conventional imaging (frequently CT, sometimes MRI or bone scan) of the affected area(s) drives much of initial and restaging and surveillance imaging for malignancy and other chronic conditions. PET is not indicated for surveillance imaging unless specifically stated in the condition-specific guideline sections.
- PET/MRI is generally not supported, See **PET-MRI (Preface-5.3)**
- PET is rarely performed as a single modality, but is typically performed as a combined PET/CT.
  - The unbundling of PET/CT into separate PET and diagnostic CT CPT® codes is not supported, because PET/CT is done as a single study.
- PET/CT lacks the tissue definition of CT or MRI, but is fairly specific for metabolic activity based on the radiotracer used
  - Fluorodeoxyglucose (fluorine-18-2-fluoro-2-deoxy-D-glucose [FDG]) is the most common PET radiotracer and images glucose metabolism
  - Some specialized radiotracers including Gallium-68 DOTATATE, C-11 Choline,

F-18 Fluciclovine (AXUMIN®), 68Ga PSMA-11, and 18F Piflufolastat PSMA (Pylarify®) are supported in evaluation for some oncologic conditions, while the use of other radiotracers including but not limited to F-18 Sodium Fluoride is not supported.

- Indications for PET/CT may include
  - Oncologic Imaging for evaluation of tumor metabolic activity
  - Cardiac Imaging for evaluation of myocardial metabolic activity
  - Brain Imaging for evaluation of metabolic activity for procedural planning
- More specific guidance for PET usage, including exceptions to this general guidance can be found throughout the condition-specific guidelines.

**Overutilization of Advanced Imaging:**

- A number of recent reports describe overutilization in many areas of advanced imaging and other procedures, which may include:
  - High level testing without consideration of less invasive, lower cost options which may adequately address the clinical question at hand
  - Excessive radiation and costs with unnecessary testing
  - Defensive medical practice
  - CT without and with contrast (so called “double contrast studies) requests, which have few current indications.
  - MRI requested in place of CT to avoid radiation without considering the primary indication for imaging
  - Adult CT settings and protocols used for smaller people and children
  - Unnecessary imaging procedures when the same or similar studies have already been conducted.
- A review of the imaging or other relevant procedural histories of all individuals presenting for studies has been recognized as one of the more important processes that can be significantly improved. By recognizing that a duplicate or questionably indicated examination has been ordered for individuals, it may be possible to avoid exposing them to unnecessary risks.<sup>9, 10</sup> To avoid these unnecessary risks, the precautions below should be considered.
  - The results of initial diagnostic tests or radiologic studies to narrow the differential diagnosis should be obtained prior to performing further tests or radiologic studies.
  - The clinical history should include a potential indication such as a known or suspected abnormality involving the body part for which the imaging study is being requested. These potential indications are addressed in greater detail within the applicable guidelines.
  - The results of the requested imaging procedures should be expected to have an impact on individual management or treatment decisions.
  - Repeat imaging studies are not generally necessary unless there is evidence of disease progression, recurrence of disease, and/or the repeat imaging will affect an individual’s clinical management.
- Preoperative imaging/pre-surgical planning imaging/pre-procedure imaging is not indicated if the surgery/procedure is not indicated. Once the procedure has been approved or if the procedure does not require prior authorization, the appropriate pre-procedural imaging may be approved.

## References (Preface-3)

v1.0.2023

1. Bettmann MA. Frequently Asked Questions: Iodinated Contrast Agents. *RadioGraphics*. 2004;24(suppl\_1):S3-S10. doi:10.1148/rg.24si045519
2. Andreucci M, Solomon R, Tasanarong A. Side Effects of Radiographic Contrast Media: Pathogenesis, Risk Factors, and Prevention. *BioMed Research International*. 2014;2014:1-20. <https://doi.org/10.1155/2014/741018>
3. McDonald RJ, McDonald JS, Kallmes DF, et al. Intracranial Gadolinium Deposition after Contrast-enhanced MR Imaging. *Radiology*. 2015;275(3):772-782. doi:10.1148/radiol.15150025
4. Kanda T, Ishii K, Kawaguchi H, Kitajima K, Takenaka D. High Signal Intensity in the Dentate Nucleus and Globus Pallidus on Unenhanced T1-weighted MR Images: Relationship with Increasing Cumulative Dose of a Gadolinium-based Contrast Material. *Radiology*. 2014;270(3):834-841. doi:10.1148/radiol.13131669
5. Olchow C, Cebulski K, Łasecki M, et al. The presence of the gadolinium-based contrast agent depositions in the brain and symptoms of gadolinium neurotoxicity - A systematic review. Mohapatra S, ed. *PLOS ONE*. 2017;12(2):e0171704. doi:10.1371/journal.pone.0171704
6. Ramalho J, Castillo M, AIObaidy M, et al. High Signal Intensity in Globus Pallidus and Dentate Nucleus on Unenhanced T1-weighted MR Images: Evaluation of Two Linear Gadolinium-based Contrast Agents. *Radiology*. 2015;276(3):836-844. doi:10.1148/radiol.2015150872
7. Radbruch A, Weberling LD, Kieslich PJ, et al. Intraindividual Analysis of Signal Intensity Changes in the Dentate Nucleus After Consecutive Serial Applications of Linear and Macrocyclic Gadolinium-Based Contrast Agents. *Investigative Radiology*. 2016;51(11):683-690. doi:10.1097/rli.0000000000000308
8. FDA Warns That Gadolinium-Based Contrast Agents (GBCAs) Are Retained in the Body; Requires New Class Warnings. <https://www.fda.gov/media/109825/download>
9. Amis ES, Butler PF, Applegate KE, et al. American College of Radiology White Paper on Radiation Dose in Medicine. *Journal of the American College of Radiology*. 2007;4(5):272-284. doi:10.1016/j.jacr.2007.03.002
10. Powell AC, Long JW, Kren EM, Gupta AK, Levin DC. Evaluation of a Program for Improving Advanced Imaging Interpretation. *Journal of Patient Safety*. 2019;15(1):69-75. doi:10.1097/PTS.0000000000000345
11. FDA. White Paper: Initiative to Reduce Unnecessary Radiation Exposure from Medical Imaging. Page Last Updated: 06/14/2019. <https://www.fda.gov/Radiation-EmittingProducts/RadiationSafety/RadiationDoseReduction/ucm199994.htm>
12. Update on FDA approach to safety issue of gadolinium retention after administration of gadolinium-based contrast agents. <https://www.fda.gov/media/116492/download>
13. Blumfield E, Swenson DW, Iyer RS, Stanescu AL. Gadolinium-based contrast agents — review of recent literature on magnetic resonance imaging signal intensity changes and tissue deposits, with emphasis on pediatric patients. *Pediatric Radiology*. 2019;49(4):448-457. doi:10.1007/s00247-018-4304-8
14. ACR – SPR –SRU PRACTICE PARAMETER FOR THE PERFORMING AND INTERPRETING DIAGNOSTIC ULTRASOUND EXAMINATIONS Revised 2017 (Resolution 32) <https://www.acr.org/-/media/ACR/Files/Practice-Parameters/US-Perf-Interpret.pdf>
15. ACR–SPR PRACTICE PARAMETER FOR PERFORMING FDG-PET/CT IN ONCOLOGY Revised 2021 (Resolution 20) <https://www.acr.org/-/media/ACR/Files/Practice-Parameters/FDG-PET-CT.pdf>
16. ACR PRACTICE PARAMETER FOR PERFORMING AND INTERPRETING MAGNETIC RESONANCE IMAGING (MRI) Revised 2017 (Resolution 10) <https://www.acr.org/-/media/ACR/Files/Practice-Parameters/MR-Perf-Interpret.pdf>
17. ACR PRACTICE PARAMETER FOR PERFORMING AND INTERPRETING DIAGNOSTIC COMPUTED TOMOGRAPHY (CT) Revised 2017 (Resolution 22) <https://www.acr.org/-/media/ACR/Files/Practice-Parameters/CT-Perf-Interpret.pdf>
18. Lohrke J, Frenzel T, Endrikat J, et al. 25 Years of Contrast-Enhanced MRI: Developments, Current Challenges and Future Perspectives. *Advances in Therapy*. 2016;33(1):1-28. doi:10.1007/s12325-015-0275-4
19. Implementation Guide: Medicaid State Plan Eligibility Eligibility Groups Mandatory Coverage Infants and Children under Age 19 at <https://www.hhs.gov/guidance/document/implementation-guide-medicaid-state-plan-eligibility-eligibility-groups-aeu-mandatory-2>
20. History and Physicals - Understanding the Requirements at <https://www.jointcommission.org/standards/standard-faqs/critical-access-hospital/medical-staff-ms/000002272/?p=1>

# Coding Issues (Preface-4)

---

## Guideline

---

- 3D Rendering (Preface-4.1)
- CT-, MR-, or Ultrasound-Guided Procedures (Preface-4.2)
- Unlisted Procedures/Therapy Treatment Planning (Preface-4.3)
- Unilateral versus Bilateral Breast MRI (Preface-4.4)
- CPT® 76380 Limited or Follow-up CT (Preface-4.5)
- SPECT/CT Imaging (Preface-4.6)
- CPT® 76140 Interpretation of an outside study (Preface-4.7)
- Quantitative MR analysis of tissue composition (Preface-4.8)
- HCPCS Codes (Preface-4.9)
- References (Preface-4)

# 3D Rendering (Preface-4.1)

PRF.CD.0004.1.UOH

v1.0.2023

## **CPT® 76376 and CPT® 76377:**

- Both codes require concurrent supervision of the image post-processing 3D manipulation of the volumetric data set and image rendering.
  - Concurrent supervision is defined as active physician participation in and monitoring of the reconstruction process including design of the anatomic region that is to be reconstructed; determination of the tissue types and actual structures to be displayed (e.g., bone, organs, and vessels); determination of the images or cine loops that are to be archived; and monitoring and adjustment of the 3D work product. The American College of Radiology (ACR) recommends that it is best to document the physician's supervision or participation in the 3D reconstruction of images.
- These two codes differ in the need for and use of an independent workstation for post-processing.
  - CPT® 76376 reports procedures not requiring image post-processing on an independent workstation.
  - CPT® 76377 reports procedures that require image post-processing on an independent workstation.
- These 3D rendering codes should not be used for 2D reformatting.
- Two-dimensional reconstruction (e.g. reformatting an axial scan into the coronal plane) is now included in all cross-sectional imaging base codes and is not separately reimbursable.
- The codes used to report 3D rendering for ultrasound and echocardiography are also used to report the 3D post processing work on CT, MRI, and other tomographic modalities.
- Providers may be required to obtain prior authorization on these 3D codes even if prior authorization is not required for the echocardiography and/or ultrasound procedure codes. It may appear that UnitedHealthcare pre-authorizes echocardiography and/or ultrasound when, in fact, it may only be the 3D code that needs the prior authorization.
- CPT® codes for 3D rendering should not be billed in conjunction with computer-aided detection (CAD), MRA, CTA, nuclear medicine SPECT studies, PET, PET/CT, Mammogram, MRI Breast, US Breast, CT Colonography (virtual colonoscopy), Cardiac MRI, Cardiac CT, or Coronary CTA studies.

- CPT® 76377 (3D rendering requiring image post-processing on an independent workstation) or CPT® 76376 (3D rendering not requiring image post-processing on an independent workstation) can be considered in the following clinical scenarios:
  - Bony conditions:
    - Evaluation of congenital skull abnormalities in newborns, infants, and toddlers (usually for preoperative planning)
    - Complex fractures (comminuted or displaced)/dislocations of any joint (For preoperative planning when conventional imaging is insufficient)
    - Spine fractures, pelvic/acetabulum fractures, intra-articular fractures (For preoperative planning when conventional imaging is insufficient)
    - Preoperative planning for other complex surgical cases
    - Complex facial fractures
  - Preoperative planning for other complex surgical cases
  - Cerebral angiography
  - Pelvis conditions:
    - Uterine intra-cavitary lesion when initial US is equivocal (See **Abnormal Uterine Bleeding (AUB) (PV-2.1)** and **Leiomyoma/Uterine Fibroids (PV-12.1)** in the Pelvis Imaging Guidelines)
    - Hydrosalpinxes or peritoneal cysts when initial US is indeterminate (See **Complex Adnexal Masses (PV-5.3)** in the Pelvis Imaging Guidelines)
    - Lost IUD (inability to feel or see IUD string) with initial US (See **Intrauterine Device (PV-10.1)** in the Pelvis Imaging Guidelines)
    - Uterine anomalies with initial US (See **Uterine Anomalies (PV-14.1)** in the Pelvis Imaging Guidelines)
    - Infertility (See **Initial Infertility Evaluation, Female (PV-9.1)** in the Pelvis Imaging Guidelines)
  - Abdomen conditions:
    - CT Urogram (See **Hematuria and Hydronephrosis (AB-39)** in the Abdomen Imaging Guidelines)
    - MRCP (See **MR Cholangiopancreatography (MRCP) (AB-27)** in the Abdomen Imaging Guidelines)

# CT-, MR-, or Ultrasound-Guided Procedures (Preface-4.2)

PRF.CD.0004.2.UOH

v1.0.2023

- CT, MR, and Ultrasound guidance procedure codes contain all the imaging necessary to guide a needle or catheter. It is inappropriate to routinely bill a diagnostic procedure code in conjunction with a guidance procedure code.
- Imaging studies performed as part of a CT-, MR-, or Ultrasound-guided procedure should be reported using the CPT® codes in the following table.

**TABLE: Imaging Guidance Procedure Codes**

CPT®	Description
76942	Ultrasonic guidance for needle placement
77022	MR guidance for, and monitoring of parenchymal tissue ablation
77021	MR guidance for needle placement
77013	CT guidance for, and monitoring of parenchymal tissue ablation
77012	CT guidance for needle placement
77011	CT guidance for stereotactic localization
75989	Imaging guidance for percutaneous drainage with placement of catheter (all modalities)
19086	Biopsy, breast, with placement of breast localization device(s), when performed, and imaging of the biopsy specimen, when performed, percutaneous; each additional lesion, including MR guidance
19085	Biopsy, breast, with placement of breast localization device(s), when performed, and imaging of the biopsy specimen, when performed, percutaneous; first lesion, including MR guidance

**CPT® 19085 and CPT® 19086:**

- The proper way to bill an MRI guided breast biopsy is CPT® 19085 (Biopsy, breast, with placement of breast localization device(s), when performed, and imaging of the biopsy specimen, when performed, percutaneous; first lesion, including MR guidance). Additional lesions should be billed using CPT® 19086.
  - **CPT® 77021** (MR guidance for needle placement) is not an appropriate code for a breast biopsy.

**CPT® 75989:**

- This code is used to report imaging guidance for a percutaneous drainage procedure in which a catheter is left in place.
- This code can be used to report whether the drainage catheter is placed under fluoroscopy, ultrasound, CT, or MR guidance modality.



### **CPT® 77011:**

- A stereotactic CT localization scan is frequently obtained prior to sinus surgery. The dataset is then loaded into the navigational workstation in the operating room for use during the surgical procedure. The information provides exact positioning of surgical instruments with regard to the individual's 3D CT images.<sup>3</sup>
- In most cases, the preoperative CT is a technical-only service that does not require interpretation by a radiologist.
  - The imaging facility should report CPT® 77011 when performing a scan not requiring interpretation by a radiologist.
  - If a diagnostic scan is performed and interpreted by a radiologist, the appropriate diagnostic CT code (e.g., CPT® 70486) should be used.
  - It is not appropriate to report both CPT® 70486 and CPT® 77011 for the same CT stereotactic localization imaging session.
  - 3D Rendering (CPT® 76376 or CPT® 76377) should not be reported in conjunction with CPT® 77011 (or CPT® 70486 if used). The procedure inherently generates a 3D dataset.

### **CPT® 77012 (CT) and CPT® 77021 (MR):**

- These codes are used to report imaging guidance for needle placement during biopsy, aspiration, and other percutaneous procedures.
- They represent the radiological supervision and interpretation of the procedure and are often billed in conjunction with surgical procedure codes.
  - For example, CPT® 77012 is reported when CT guidance is used to place the needle for a conventional arthrogram.
  - Only codes representing percutaneous surgical procedures should be billed with CPT® 77012 and CPT® 77021. It is inappropriate to use with surgical codes for open, excisional, or incisional procedures.
  - **CPT® 77021** (MR guidance for needle placement) is not an appropriate code for breast biopsy.
    - CPT® 19085 would be appropriate for the first breast biopsy site, and CPT® 19086 would be appropriate for additional concurrent biopsies.

### **CPT® 77013 (CT) and CPT® 77022 (MR):**

- These codes include the initial guidance to direct a needle electrode to the tumor(s), monitoring for needle electrode repositioning within the lesion, and as necessary for multiple ablations to coagulate the lesion and confirmation of satisfactory coagulative necrosis of the lesion(s) and comparison to pre-ablation images.
  - **NOTE:** CPT® 77013 should only be used for non-bone ablation procedures.
    - CPT® 20982 includes CT guidance for bone tumor ablations.
  - Only codes representing percutaneous surgical procedures should be billed with CPT® 77013 and CPT® 77022. It is inappropriate to use with surgical codes for open, excisional, or incisional procedures.
- CPT® 77012 and CPT® 77021 (as well as guidance codes CPT® 76942 [US], and CPT® 77002 - CPT® 77003 [fluoroscopy]) describe radiologic guidance by different modalities.
  - Only one unit of any of these codes should be reported per individual encounter (date of service). The unit of service is considered to be the individual encounter, not the number of lesions, aspirations, biopsies, injections, or localizations.

# Unlisted Procedures/Therapy Treatment Planning (Preface-4.3)

PRF.CD.0004.3.UOH

v1.0.2023

CPT®	Description
78999	Unlisted procedure, diagnostic nuclear medicine
76498	Unlisted MR procedure (e.g., diagnostic or interventional)
76497	Unlisted CT procedure (e.g., diagnostic or interventional)

- These unlisted codes should be reported whenever a diagnostic or interventional CT or MR study is performed in which an appropriate anatomic site-specific code is not available.
  - A Category III code that describes the procedure performed must be reported rather than an unlisted code if one is available.
- CPT® 76497 or CPT® 76498 (Unlisted CT or MRI procedure) can be considered in the following clinical scenarios:
  - Studies done for navigation and planning for neurosurgical procedures (i.e. Stealth or Brain Lab Imaging)<sup>1,2</sup>
  - Custom joint Arthroplasty planning (not as Alternative Recommendation) (See **Osteoarthritis (MS-12.1)** in the Musculoskeletal Imaging Guidelines)
  - Any procedure/surgical planning if thinner cuts or different positional acquisition (than those on the completed diagnostic study) are needed. These could include navigational bronchoscopy. See **Navigational Bronchoscopy (CH-1.7)** in the Chest Imaging Guidelines

## **Therapy Treatment Planning**

- Radiation Therapy Treatment Planning: See **Unlisted Procedure Codes in Oncology (ONC-1.5)** In the Oncology Imaging Guidelines

# CPT® 76380 Limited or Follow-up CT (Preface-4.5)

PRF.CD.0004.5.UOH

v1.0.2023

- CPT® 76380 describes a limited or follow-up CT scan. The code is used to report any CT scan, for any given area of the body, in which the work of a full diagnostic code is not performed.
- Common examples include (but are not limited to):
  - Limited sinus CT imaging protocol
  - Limited or follow-up slices through a known pulmonary nodule
  - Limited slices to assess a non-healing fracture (such as the clavicle)
- Limited CT (CPT® 76380) is not indicated for treatment planning purposes. Please See **Unlisted Procedure Codes in Oncology (ONC-1.5)** in the Oncology Imaging Guidelines.
- It is inappropriate to report CPT® 76380, in conjunction with other diagnostic CT codes, to cover 'extra slices' in certain imaging protocols.
  - There is no specific number of sequences or slices defined in any CT CPT® code definition.
  - The AMA, in *CPT® 2019*, does not describe nor assign any minimum or maximum number of sequences or slices for any CT study.
    - A few additional slices or sequences are not uncommon.
    - CT imaging protocols are often influenced by the individual clinical situation of the individual. Sometimes the protocols require more time and sometimes less.

# SPECT/CT Imaging (Preface-4.6)

---

PRF.CD.0004.6.UOH

v1.0.2023

- SPECT/CT involves SPECT (Single Photon Emission Computed Tomography) nuclear medicine imaging and CT for optimizing location, accuracy, and attenuation correction and combines functional and anatomic information.
  - Common studies using this modality include <sup>123</sup>I- or <sup>131</sup>I- Metaiodobenzylguanidine (MIBG) and octreotide scintigraphy for neuroendocrine tumors.
- Hybrid Nuclear/CT scan can be CPT® 78830 - single area and single day, CPT® 78831 - 2 or more days, or CPT® 78832 - 2 areas with one day and 2-day study.
- A procedure code for SPECT/CT parathyroid nuclear imaging, (CPT® 78072), became effective January 1, 2013.

# CPT® 76140 Interpretation of an Outside Study (Preface-4.7)

---

PRF.CD.0004.7.UOH

v1.0.2023

- It is inappropriate to use diagnostic imaging codes for interpretation of a previously performed exam that was completed at another facility.
  - If the outside exam is being used for comparison with a current exam, the diagnostic code for the current examination includes comparison to the prior study<sup>4</sup>
  - CPT® 76140 is the appropriate code to use for an exam which was completed elsewhere, and a secondary interpretation of the images is requested.<sup>5</sup>

# Quantitative MR Analysis of Tissue Composition (Preface-4.8)

PRF.CD.0004.8.UOH

v1.0.2023

- Category III CPT® codes for quantitative analysis of multiparametric MR (mp-MRI) data with and without an associated diagnostic MRI have been established. Quantitative mp-MRI uses software to analyze tissue physiology of visceral organs and other anatomic structures non-invasively. At present, these procedures are primarily being used in clinical trials and there is no widely recommended indications in clinical practice. As such, these procedures are considered to be investigational and experimental for coverage purposes.
  - CPT® 0648T (without diagnostic MRI) and CPT® 0649T (with diagnostic MRI) refer to data analysis with and without associate imaging of a single organ, with its most common use being LiverMultiScan (LMS)
    - See **Fatty Liver (AB-29.2)** in the Abdomen Imaging Guidelines
  - CPT® 0697T (without diagnostic MRI) and CPT® 0698T (with diagnostic MRI) refer to data analysis with and without associate imaging of a multiple organs, with its most common use being CoverScan.

# HCPCS Codes (Preface-4.9)

PRF.CD.0004.9.UOH

v1.0.2023

- Healthcare Common Procedure Coding System (HCPCS) codes are utilized by some hospitals in favor of the typical Level 3 CPT® Codes. These codes are typically 4 digits preceded by a C, or S<sup>6</sup>
  - Many of these codes have similar code descriptions to level 3 CPT® codes (i.e. C8931 – MRA with dye, Spinal Canal, and 72159-MRA Spinal canal)
  - If cases are submitted with HCPCS codes with similar code descriptions to the typical level 3 CPT® codes, those procedures should be managed in the same manner as the typical CPT® codes
  - HCPCS code management is discussed further in the applicable guideline sections
- Requests for many Healthcare Common Procedure Coding System (HCPCS) codes, including nonspecific codes such as S8042 [Magnetic resonance imaging (MRI), low-field], should be redirected to a more appropriate and specific CPT® code. Exceptions are noted in the applicable guideline sections.

## References (Preface-4)

---

v1.0.2023

1. Society of Nuclear Medicine and Molecular Imaging Coding Corner <http://www.snmmi.org/ClinicalPractice/CodingCornerPT.aspx?ItemNumber=1786>
2. Intraoperative MR. Brainlab. <https://www.brainlab.com/surgery-products/overview-neurosurgery-products/intraoperative-mr/>
3. Experience the Advanced 3D Sinus Surgery Planning with Scopis Building Blocks planning software. Scopis Planning. <http://planning.scopis.com/>
4. ACR Radiology Coding Source™ March-April 2007 Q and A. [www.acr.org](http://www.acr.org). <https://www.acr.org/Advocacy-and-Economics/Coding-Source/ACR-Radiology-Coding-Source-March-April-2007-Q-and-A>
5. Chung CY, Alson MD, Duszak R, Degnan AJ. From imaging to reimbursement: what the pediatric radiologist needs to know about health care payers, documentation, coding and billing. *Pediatric Radiology*. 2018;48(7):904-914. doi:10.1007/s00247-018-4104-1
6. HCPCS - General Information from CMS.gov at <https://www.cms.gov/medicare/coding/medhcpcsgeninfo>



# Whole Body Imaging (Preface-5)

---

## Guideline

---

Whole-Body CT Imaging (Preface-5.1)

Whole-Body MR Imaging (Preface-5.2)

PET-MRI (Preface-5.3)

References (Preface-5)

# Whole Body CT Imaging (Preface-5.1)

---

PRF.WB.0005.1.UOH  
v1.0.2023

- Whole-body CT or LifeScan (CT Brain, Chest, Abdomen, and Pelvis) for screening of asymptomatic individuals is not indicated. The performance of whole-body screening CT examinations in healthy individuals does not meet any of the current validity criteria for screening studies and there is no clear documentation of benefit versus radiation risk.
- Whole-body low dose CT is supported for oncologic staging in Multiple Myeloma (See **Multiple Myeloma and Plasmacytomas (ONC-25)** in the Oncology Imaging Guidelines)

# Whole Body MR Imaging (Preface-5.2)

PRF.WB.0005.2.UOH

v1.0.2023

- Whole-body MRI (WBMRI) is, with the exception of select cancer predisposition syndromes and autoimmune conditions discussed below, generally not supported at this time due to lack of standardization in imaging technique and lack of evidence that WBMRI improves individual outcome for any individual disease state.
  - While WBMRI has the benefit of whole-body imaging and lack of radiation exposure, substantial variation still exists in the number of images, type of sequences (STIR vs. diffusion weighting, for example), and contrast agent(s) used.
- Coding considerations:
  - There are no established CPT® or HCPCS codes for reporting WBMRI.
  - WBMRI is at present only reportable using CPT® 76498. All other methods of reporting whole-body MRI are inappropriate, including:
    - Separate diagnostic MRI codes for multiple individual body parts
    - MRI Bone Marrow Supply (CPT® 77084)
- Disease-specific considerations:
  - Cancer screening:
    - Interval WBMRI is recommended for cancer screening in individuals with select cancer predisposition syndromes. Otherwise, WBMRI has not been shown to improve outcomes for cancer screening. See **Li-Fraumeni Syndrome (LFS) (PEDONC-2.2)**, **Hereditary Paraganglioma-Pheochromocytoma (HPP) Syndromes (PEDONC-2.13)**, **Constitutional Mismatch Repair Deficiency (CMMRD or Turcot Syndrome) (PEDONC-2.15)** in the Pediatric Oncology Imaging Guidelines for additional information
  - Cancer staging and restaging
    - While the feasibility of WBMRI has been established, data remain conflicting on whether WBMRI is of equivalent diagnostic accuracy compared with standard imaging modalities such as CT, scintigraphy, and PET imaging.
    - Evidence has not been published establishing WBMRI as a standard evaluation for any type of cancer.
  - Autoimmune disease
    - WBMRI can be approved in some situations for individuals with chronic recurrent multifocal osteomyelitis. See **Chronic Recurrent Multifocal Osteomyelitis (PEDMS-10.2)** in the Pediatric Musculoskeletal Imaging Guidelines for additional information.

## PET-MRI (Preface-5.3)

PRF.WB.0005.3.UOH

v1.0.2023

- PET-MRI is generally not supported for a vast majority of oncologic and neurologic conditions due to lack of standardization in imaging technique and interpretation. However, it may be appropriate in select circumstances when the following criteria are met:
  - The individual meets guideline criteria for PET-CT **AND** PET-CT is not available at the treating institution **AND**
  - The provider requests PET-MRI in lieu of PET-CT
- When the above criteria are met, PET-MRI may be reported using the code combination of PET Whole-Body (CPT® 78813) and MRI Unlisted (CPT® 76498). All other methods of reporting PET-MRI are inappropriate.
  - When clinically appropriate, diagnostic MRI codes may be indicated at the same time as the PET-MRI code combination.
- See **PET Imaging in Pediatric Oncology (PEDONC-1.4)** in the Pediatric Oncology Imaging Guidelines, **PET Brain Imaging (PEDHD-2.3)**, and **Special Imaging Studies in Evaluation for Epilepsy Surgery (PEDHD-6.3)** in the Pediatric Head Imaging Guidelines for more information

## References (Preface-5)

**v1.0.2023**

1. Villani A, Tabori U, Schiffman J, et al. Biochemical and imaging surveillance in germline TP53 mutation carriers with Li-Fraumeni syndrome: a prospective observational study. *The Lancet Oncology*. 2011;12(6):559-567. doi:10.1016/S1470-2045(11)70119-X
2. Siegel MJ, Acharyya S, Hoffer FA, et al. Whole-Body MR Imaging for Staging of Malignant Tumors in Pediatric Patients: Results of the American College of Radiology Imaging Network 6660 Trial. *Radiology*. 2013;266(2):599-609. doi:10.1148/radiol.12112531
3. Antoch G. Whole-Body Dual-Modality PET/CT and Whole-Body MRI for Tumor Staging in Oncology. *JAMA*. 2003;290(24):3199. doi:10.1001/jama.290.24.3199
4. Lauenstein TC, Semelka RC. Emerging techniques: Whole-body screening and staging with MRI. *Journal of Magnetic Resonance Imaging*. 2006;24(3):489-498. doi:10.1002/jmri.20666
5. Khanna G, Sato TSP, Ferguson P. Imaging of Chronic Recurrent Multifocal Osteomyelitis. *RadioGraphics*. 2009;29(4):1159-1177. doi:10.1148/rg.294085244
6. Ferguson PJ, Sandu M. Current Understanding of the Pathogenesis and Management of Chronic Recurrent Multifocal Osteomyelitis. *Current Rheumatology Reports*. 2012;14(2):130-141. doi:10.1007/s11926-012-0239-5
7. National Comprehensive Cancer Network (NCCN) Guidelines Version 2.2022. – March 19, 2022, Genetic/Familial High Risk Assessment: Breast and Ovarian, available at: [https://www.nccn.org/professionals/physician\\_gls/pdf/genetics\\_bop.pdf](https://www.nccn.org/professionals/physician_gls/pdf/genetics_bop.pdf) Referenced with permission from the NCCN Clinical Practice Guidelines in Oncology (NCCN Guidelines™) for Genetic/Familial High-Risk Assessment: Breast, Ovarian, and Pancreatic V2.2022. – March 19, 2022 ©. 2022 National Comprehensive Cancer Network, Inc. All rights reserved. The NCCN Guidelines™ and illustrations herein may not be reproduced in any form for any purpose without the express written permission of the NCCN. To view the most recent and complete version of the NCCN Guidelines™, go online to NCCN.org

# References (Preface-6)

---

Guideline

---

References (Preface-6.1)

## References (Preface-6.1)

---

PRF.RF.0006.1.UOH  
v1.0.2023

- Complete reference citations for the journal articles are embedded within the body of the guidelines and/or may be found on the Reference pages at the end of some guideline sections.
- The website addresses for certain references are included in the body of the guidelines but are not hyperlinked to the actual website.
- The website address for the American College of Radiology (ACR) Appropriateness Criteria® is <http://www.acr.org>.

# Copyright Information (Preface-7)

---

## Guideline

---

Copyright Information (Preface-7.1)



# Copyright Information (Preface-7.1)

---

PRF.CI.0007.1.UOH

v1.0.2023

- ©2023 United HealthCare Services, Inc. All rights reserved. No part of these materials may be changed, reproduced, or transmitted in any form or by any means, electronic or mechanical, including photocopying or recording, or in any information storage or retrieval system, without the prior express written permission of United HealthCare Services, Inc.

# Trademarks (Preface-8)

---

## Guideline

---

Trademarks (Preface-8.1)

## Trademarks (Preface-8.1)

---

PRF.TM.0008.1.UOH

v1.0.2023

- **CPT® (Current Procedural Terminology)** is a registered trademark of the American Medical Association (AMA). **CPT®** five-digit codes, nomenclature, and other data are copyright 2023 American Medical Association. All Rights Reserved. No fee schedules, basic units, relative values, or related listings are included in the **CPT®** book. AMA does not directly or indirectly practice medicine or dispense medical services. AMA assumes no liability for the data contained herein or not contained herein.

## **Pediatric and Special Populations Oncology Imaging Guidelines**

**Abbreviations for Pediatric and Special Populations Oncology Imaging Guidelines**

**General Guidelines (PEDONC-1)**

**Screening Imaging in Cancer Predisposition Syndromes (PEDONC-2)**

**Pediatric Leukemias (PEDONC-3)**

**Pediatric CNS Tumors (PEDONC-4)**

**Pediatric Lymphomas (PEDONC-5)**

**Neuroblastoma (PEDONC-6)**

**Pediatric Renal Tumors (PEDONC-7)**

**Pediatric Soft Tissue Sarcomas (PEDONC-8)**

**Bone Tumors (PEDONC-9)**

**Pediatric Germ Cell Tumors (PEDONC-10)**

**Pediatric Liver Tumors (PEDONC-11)**

**Retinoblastoma (PEDONC-12)**

**Pediatric Nasopharyngeal Carcinoma (PEDONC-13)**

**Pediatric Adrenocortical Carcinoma (PEDONC-14)**

**Pediatric Melanoma and Other Skin Cancers (PEDONC-15)**

**Pediatric Salivary Gland Tumors and Thyroid Tumors (PEDONC-16)**

**Pediatric Breast Masses (PEDONC-17)**

**Histiocytic Disorders (PEDONC-18)**

**Long Term Pediatric Cancer Survivors (PEDONC-19)**

## Abbreviations for Pediatric and Special Populations Oncology Imaging Guidelines

<b>AFP</b>	Alpha-fetoprotein (tumor marker)
<b>ALCL</b>	Anaplastic large cell lymphoma
<b>ALL</b>	Acute lymphoblastic leukemia
<b>AML</b>	Acute myelogenous leukemia
<b>β-hCG</b>	Human chorionic gonadotropin beta-subunit (tumor marker)
<b>BKL</b>	Burkitt's lymphoma
<b>BWT</b>	Bilateral Wilms tumor
<b>CCSK</b>	Clear cell sarcoma of the kidney
<b>CNS</b>	Central nervous system
<b>COG</b>	Children's Oncology group
<b>CPT®</b>	Current procedural terminology; trademark of the American Medical Association
<b>CSF</b>	Cerebrospinal fluid
<b>CT</b>	Computed tomography
<b>CXR</b>	Chest x-ray
<b>DAWT</b>	Diffuse anaplasia Wilms tumor
<b>ESFT</b>	Ewing sarcoma family of tumors
<b>FAWT</b>	Focal anaplasia Wilms tumor
<b>FHWT</b>	Favorable histology Wilms tumor
<b>HL</b>	Hodgkin lymphoma
<b>HSCT</b>	Hematopoietic stem cell transplant (bone marrow or peripheral blood)
<b>HVA</b>	Homovanillic acid
<b>LL</b>	Lymphoblastic lymphoma
<b>MIBG</b>	Metaiodobenzylguanidine (nuclear scan using <sup>123</sup> I or <sup>131</sup> I)
<b>MPNST</b>	Malignant peripheral nerve sheath tumor
<b>MRI</b>	Magnetic resonance imaging
<b>NBL</b>	Neuroblastoma
<b>NED</b>	No evidence of disease
<b>NHL</b>	Non-hodgkin lymphoma
<b>NPC</b>	Nasopharyngeal carcinoma
<b>NRSTS</b>	Nonrhabdomyosarcomatous soft tissue sarcomas
<b>OS</b>	Osteosarcoma
<b>PET</b>	Positron emission tomography
<b>PMBCL</b>	Primary mediastinal b-cell lymphoma
<b>PNET</b>	Primitive neuroectodermal tumor
<b>RCC</b>	Renal cell carcinoma
<b>RMS</b>	Rhabdomyosarcoma
<b>US</b>	Ultrasound
<b>VMA</b>	Vannilylmandelic acid
<b>WBC</b>	White blood cell count
<b>XRT</b>	Radiation therapy

<b>General Guidelines (PEDONC-1)</b>
<b>General Guidelines (PEDONC-1.0)</b>
<b>Age Considerations (PEDONC-1.1)</b>
<b>Appropriate Clinical Evaluations (PEDONC-1.2)</b>
<b>Modality General Considerations (PEDONC-1.3)</b>
<b>PET Imaging in Pediatric Oncology (PEDONC-1.4)</b>
<b>Diagnostic Radiation Exposure in Pediatric Oncology (PEDONC-1.5)</b>

## **General Guidelines (PEDONC-1.0)**

- A recent clinical evaluation (within 60 days) or meaningful contact (telephone call, electronic mail or messaging) should be performed prior to considering advanced imaging, unless the individual is undergoing guideline-supported scheduled off therapy surveillance evaluation or cancer screening. The clinical evaluation may include a relevant history and physical examination, including biopsy, appropriate laboratory studies, and results of non-advanced or advanced imaging modalities.
  - ◆ Because of the relatively small number of childhood cancer treatment centers, it is common to combine off-therapy visits with imaging and other subspecialist visits to accommodate families traveling long distances for their child's care.
- Unless otherwise stated in the disease-specific guideline, a histological confirmation of malignancy (or recurrence) and the stage of disease is required to perform a medical necessity review of the requested imaging.
- Unless otherwise stated in the disease-specific guideline, advanced imaging of asymptomatic individuals is not routinely supported without signs or symptoms of systemic involvement of cancer.
- Conventional imaging performed prior to diagnosis should not be repeated unless there is a delay of at least 6 weeks since previous imaging and treatment initiation or there are new or significantly worsening clinical signs or symptoms
- Unless otherwise stated in the diagnosis-specific guidelines, imaging for treatment response can be approved after every 2 cycles, which is usually ~6 weeks of therapy for solid tumors and usually ~8 to 12 weeks for CNS tumors
- Unless otherwise specified for a specific cancer type, once PET has been documented to be negative for a given individual's cancer or all PET-avid disease has been surgically resected, PET should not be used for continued disease monitoring or surveillance unless one of the following applies:
  - ◆ Conventional imaging (CT, MRI, US, plain film) reveals findings that are inconclusive or suspicious for recurrence
  - ◆ Residual mass that has not changed in size since the last conventional imaging does not justify PET imaging
  - ◆ PET avidity in a residual mass at the end of planned therapy is not an indication for PET imaging during surveillance

### Clarification of phases of therapy

Phases of Oncology Imaging	Definition
Screening	<ul style="list-style-type: none"> <li>➤ Imaging requested for individuals at increased risk for a particular cancer in the absence of known clinical signs or symptoms</li> <li>➤ Screening using advancing imaging is only supported for conditions listed in <b><u>Screening Imaging in Cancer Predisposition Syndromes (PEDONC-2)</u></b></li> </ul>
Suspected/Initial Staging	<ul style="list-style-type: none"> <li>➤ All imaging studies requested from the time cancer is first clinically suspected until the initiation of specific treatment                             <ul style="list-style-type: none"> <li>◆ CT Chest prior to anesthesia for biopsy or resection of solid tumors and CTs of other involved body areas are generally indicated and should be performed concurrently</li> <li>◆ Metastatic CNS imaging and nuclear medicine imaging are generally deferred until after a histologic diagnosis is made, unless otherwise indicated by diagnosis-specific guideline</li> </ul> </li> </ul>
Treatment Response	<ul style="list-style-type: none"> <li>➤ Imaging performed during any type of active treatment (chemotherapy or other medications, radiation therapy, or surgery), including evaluation at the end of planned active treatment                             <ul style="list-style-type: none"> <li>◆ Unless otherwise stated in the diagnosis-specific guidelines, imaging for treatment response can be approved after every 2 cycles, which is usually ~6 weeks of therapy for solid tumors and usually ~8 to 12 weeks for CNS tumors</li> </ul> </li> </ul>
Surveillance	<ul style="list-style-type: none"> <li>➤ Imaging performed in individuals who are asymptomatic or have chronic stable symptoms and not receiving any active treatment, even if residual imaging abnormalities are present                             <ul style="list-style-type: none"> <li>◆ PET imaging is not supported for surveillance imaging unless specifically stated in elsewhere in the diagnosis-specific guideline sections</li> </ul> </li> </ul>



Phases of Oncology Imaging	Definition
Recurrence	<ul style="list-style-type: none"> <li>➤ All imaging studies completed at the time a recurrence or progression of a known cancer is strongly suspected or documented based on clinical signs or symptoms, laboratory findings, or results of basic imaging studies such as plain radiography or ultrasound</li> <li>➤ Following documented recurrence of childhood cancer, any studies recommended for initial staging of that cancer type in the diagnosis-specific imaging guideline section should be approved                             <ul style="list-style-type: none"> <li>◆ During active treatment for recurrent pediatric cancer, conventional imaging evaluation (CT or MRI, should use the same modality for ongoing monitoring as much as possible) of previously involved areas should be approved according to the treatment response imaging in the diagnosis-specific guideline section                                     <ul style="list-style-type: none"> <li>■ Always refer to the diagnosis specific guideline for PET indications in recurrence.</li> </ul> </li> </ul> </li> </ul>

- Brain imaging is performed for signs or symptoms of brain disease
  - ◆ MRI Brain without and with contrast (CPT® 70553) is the recommended study for evaluation of suspected or known brain metastases. If a non-contrast CT head shows suspicious lesion, MRI Brain may be obtained to further characterize the lesion
  - ◆ CT Head without and with contrast (CPT® 70470) can be approved when MRI is contraindicated or not available, or if there is skull bone involvement
  - ◆ Certain malignancies including, but not limited to melanoma, lung cancer and renal cell cancer have indications for brain imaging for asymptomatic individuals
  - ◆ If stage IV disease is demonstrated elsewhere or if systemic disease progression is noted, refer to disease specific guidelines
  - ◆ Initiation of angiogenesis therapy is not an indication for advanced imaging of the brain in asymptomatic individuals (Avastin/Bevacizumab; <3% risk of bleeding and <1% risk of serious bleeding)
- Bone Scan:
  - ◆ Primarily used for evaluation of bone metastases in individuals with solid malignancies.
  - ◆ Indications for bone scan in individuals with history of malignancy include – bone pain, rising tumor markers, elevated alkaline phosphatase or in individuals with primary bone tumor.
  - ◆ For evaluation of suspected or known bony metastases, CPT® 78306 (Nuclear bone scan whole-body), may be approved.
  - ◆ Radiopharmaceutical Localization scan SPECT (CPT® 78803 or CPT® 78831) or SPECT/CT (CPT® 78830 or CPT® 78832) may be approved as an add-on test for further evaluation of a specific area of interest.

- ◆ CPT® codes 78300 (Nuclear bone scan limited), 78305 (Nuclear bone scan multiple areas) or 78315 do not have any indications in oncology nuclear medicine imaging.
- Bone scan supplemented by plain x-rays are the initial imaging modalities for suspected malignant bone pain. For specific imaging indications, see also:
  - ◆ **Nuclear Medicine (NM) Imaging in Oncology (ONC-1.3)**
  - ◆ **Bone (including Vertebral) Metastases (ONC-31.5)**
  - ◆ **Spinal Cord Compression (ONC-31.6)**
  - ◆ **Carcinoma of Unknown Primary Site (ONC-31.7)**
- Delay PET/CT for at least 12 weeks after completion of radiation treatment, unless required sooner for imminent surgical resection.
- PET/CT may be considered prior to biopsy in order to determine a more favorable site for biopsy when a prior biopsy was nondiagnostic or a relatively inaccessible site is contemplated which would require invasive surgical intervention for biopsy attempt.
- PET/CT may be indicated if:
  - ◆ Conventional imaging (CT, MRI or bone scan) reveals findings that are inconclusive or negative, with continued suspicion for recurrence
- Unless specified in diagnosis-specific guideline section PET/CT Imaging is NOT indicated for:
  - ◆ Infection, inflammation, trauma, post-operative healing, granulomatous disease, rheumatological conditions
  - ◆ Concomitantly with separate diagnostic CT studies
  - ◆ Conclusive evidence of distant or diffuse metastatic disease on recent conventional imaging studies
  - ◆ Metastatic disease in the central nervous system (CNS)
  - ◆ Lesions less than 8 mm in size
  - ◆ Follow up after localized therapy (i.e. radiofrequency ablation, embolization, stereotactic radiation, etc.)
  - ◆ Rare malignancies, due to lack of available evidence regarding the diagnostic accuracy of PET in rare cancers
  - ◆ Surveillance
    - Serial monitoring of individuals who are not currently receiving anti-tumor treatment or are receiving maintenance treatment
    - Serial monitoring of FDG avidity until resolution.
    - PET/CT avidity in a residual mass at the end of planned therapy is not an indication for PET/CT imaging during surveillance.
    - Residual mass that has not changed in size since the last conventional imaging does not justify PET imaging
- Please refer to general guidelines section **PET Imaging in Oncology (ONC-1.4)** and **PET Imaging in Pediatric Oncology (PEDONC-1.4)** for further guidance regarding PET. Those guidelines should be applied with regard to radiotracer coverage.
- Please refer to general guidelines in **Unlisted Procedure Codes in Oncology (ONC-1.5)** for unlisted procedures in pediatric oncology.

## **Clinical Trials**

- Similar to investigational and experimental studies, clinical trial imaging requests will be considered to determine whether they meet Health Plan coverage and eviCore’s evidence-based guidelines.
- Imaging studies which are inconsistent with established clinical standards, or are requested for data collection and not used in direct clinical management are not supported.

## **Age Considerations (PEDONC-1.1)**

- The majority of malignancies occurring in the pediatric population are different diagnoses than those occurring in the adult population.
- For those diseases which occur in both pediatric and adult populations, minor differences may exist in management between pediatric and adult medical oncologists due to the following:
  - ◆ Age of the individual
  - ◆ Comorbidities
  - ◆ Differences in disease natural history between children and adults

<b>AGE APPROPRIATE GUIDELINES</b>	
<b>Age of Individual</b>	<b>Appropriate Imaging Guidelines</b>
≥18 years old at initial diagnosis	➤ General Oncology Imaging Guidelines, except where directed otherwise by a specific guideline section
<18 years old at initial diagnosis	➤ Pediatric Oncology Imaging Guidelines, except where directed otherwise by a specific guideline section
15 to 39 years old at initial diagnosis (defined as Adolescent and Young Adult (AYA) oncology individuals)	<ul style="list-style-type: none"> <li>➤ When unique guidelines for a specific cancer type exist only in either Oncology or Pediatric Oncology, AYA individuals should be imaged according to the guideline section for their specific cancer type, regardless of the individual’s age</li> <li>➤ When unique guidelines for a specific cancer type exist in both Oncology and Pediatric Oncology, AYA individuals should be imaged according to the age rule in the previous bullet</li> </ul>

## **Appropriate Clinical Evaluations (PEDONC-1.2)**

- The majority of pediatric oncology imaging indications are listed in the diagnosis-specific guideline sections
  - ◆ Rare malignancies and other circumstances not specifically addressed elsewhere in the Pediatric Oncology guidelines, the following general principles apply:
    - Routine imaging of brain, spine, neck, chest, abdomen, pelvis, bones, or other body areas is not indicated in the absence of:
      - Localizing symptoms or
      - Abnormalities on plain radiography or ultrasound

- The overwhelming majority of pediatric oncology individuals treated in the United States will be enrolled on or treated according to recent Children’s Oncology Group (COG) protocols
  - ◆ COG is a National Cancer Institute (NCI) supported clinical trials group
  - ◆ These imaging guidelines are consistent with evaluations recommended by COG protocols commonly used for direct individual care (whether formally enrolled on study or not)
- For individuals enrolled on a COG study, imaging recommended by COG protocols should generally be approved unless the imaging is being performed solely to address a study objective and would not be indicated in usual clinical care

**Phases of Pediatric Oncology Imaging:**

- Pediatric malignancies, in general, behave more aggressively than adult cancers, and the time from initial suspicion of cancer to specific therapy initiation can be measured in hours to days for most pediatric cancers
- It is recommended that children with pediatric solid tumors undergo CT evaluation of the chest prior to general anesthesia for biopsy or resection due to the risk of post-operative atelectasis mimicking pulmonary metastasis resulting in inaccurate staging and/or delay in therapy initiation
- Unlike adult cancers, in most pediatric cancers surveillance does not begin until all planned multimodal therapy is completed
- Pediatric cancers where surgical resection is considered curative are listed in the diagnosis-specific guideline sections
- Certain tumor types do not require surveillance with advanced imaging as individual outcomes following relapse are not improved by surveillance imaging. See diagnosis-specific guideline sections for details
- Imaging may be indicated more frequently than recommended by guidelines with clinical documentation that the imaging results are likely to result in a treatment change for the individual, including a change from active treatment to surveillance

Phases of Oncology Imaging	Definition
Screening	<ul style="list-style-type: none"> <li>➤ Imaging requested for individuals at increased risk for a particular cancer in the absence of known clinical signs or symptoms</li> <li>➤ Screening using advanced imaging is only supported for conditions listed in <b><u>Screening Imaging in Cancer Predisposition Syndromes (PEDONC-2)</u></b></li> </ul>

Phases of Oncology Imaging	Definition
Suspected/Initial Staging	<ul style="list-style-type: none"> <li>➤ All imaging studies requested from the time cancer is first clinically suspected until the initiation of specific treatment                             <ul style="list-style-type: none"> <li>◆ CT Chest prior to anesthesia for biopsy or resection of solid tumors and CTs of other involved body areas are generally indicated and should be performed concurrently</li> <li>◆ Metastatic CNS imaging and nuclear medicine imaging are generally deferred until after a histologic diagnosis is made, unless otherwise indicated by diagnosis-specific guideline</li> </ul> </li> </ul>
Treatment Response	<ul style="list-style-type: none"> <li>➤ Imaging performed during any type of active treatment (chemotherapy or other medications, radiation therapy, or surgery), including evaluation at the end of planned active treatment                             <ul style="list-style-type: none"> <li>◆ Unless otherwise stated in the diagnosis-specific guidelines, imaging for treatment response can be approved after every 2 cycles, which is usually ~6 weeks of therapy for solid tumors and usually ~8 to 12 weeks for CNS tumors</li> </ul> </li> </ul>
Surveillance	<ul style="list-style-type: none"> <li>➤ Imaging performed in individuals who are asymptomatic or have chronic stable symptoms and not receiving any active treatment, even if residual imaging abnormalities are present                             <ul style="list-style-type: none"> <li>◆ PET imaging is not supported for surveillance imaging unless specifically stated in elsewhere in the diagnosis-specific guideline sections</li> </ul> </li> </ul>
Recurrence	<ul style="list-style-type: none"> <li>➤ All imaging studies completed at the time a recurrence or progression of a known cancer is strongly suspected or documented based on clinical signs or symptoms, laboratory findings, or results of basic imaging studies such as plain radiography or ultrasound</li> <li>➤ Following documented recurrence of childhood cancer, any studies recommended for initial staging of that cancer type in the diagnosis-specific imaging guideline section should be approved                             <ul style="list-style-type: none"> <li>◆ During active treatment for recurrent pediatric cancer, conventional imaging evaluation (CT or MRI, should use the same modality for ongoing monitoring as much as possible) of previously involved areas should be approved according to the treatment response imaging in the diagnosis-specific guideline section                                     <ul style="list-style-type: none"> <li>■ Always refer to the diagnosis specific guideline for PET indications in recurrence.</li> </ul> </li> </ul> </li> </ul>

### **Radiation Treatment Planning In Pediatric Oncology**

- Imaging performed in support of radiation therapy treatment planning should follow guidelines outlined in **Unlisted Procedure Codes in Oncology (ONC-1.5)**.

**Cardiac Function Assessment in Pediatric Oncology During Active Treatment:**

Indication	Imaging Study
<ul style="list-style-type: none"> <li>➤ Evaluation of cardiac function prior to cardiotoxic chemotherapy, at the discretion of the treating pediatric oncologist based on:                             <ul style="list-style-type: none"> <li>◆ Cumulative cardiotoxic therapy received to date</li> <li>◆ Individual’s age and gender</li> <li>◆ Most recent echocardiogram results</li> <li>◆ New or worsening cardiac symptoms</li> </ul> </li> </ul>	<ul style="list-style-type: none"> <li>➤ Echocardiography (CPT® 93306, CPT® 93307, or CPT® 93308)</li> </ul>
<ul style="list-style-type: none"> <li>➤ For either of the following:                             <ul style="list-style-type: none"> <li>◆ Echocardiography yielded a borderline shortening fraction (&lt;30%) and additional left ventricular function data are necessary to make a chemotherapy decision OR</li> <li>◆ Echocardiography windowing is suboptimal due to body habitus or tumor location</li> </ul> </li> </ul>	<ul style="list-style-type: none"> <li>➤ Multi-gated acquisition (MUGA, CPT® 78472) blood pool nuclear medicine scanning</li> </ul>

***Background and Supporting Information***

**Immunosuppression During Pediatric Cancer Therapy and Imaging Ramifications:**

- Individuals may be severely immunocompromised during active chemotherapy treatment and any conventional imaging request to evaluate for infectious complications during this time frame should be approved immediately
  - ◆ Imaging requests for infectious disease concerns for all individuals with absolute neutrophil count (ANC) <500 **or**
  - ◆ Inconclusive findings on chest x-ray or US at any ANC during active treatment should be approved as requested
  - ◆ Individuals may have therapy-induced hypogammaglobulinemia which requires supplemental intravenous immune globulin (IVIG) during maintenance therapy. These individuals receiving supplemental IVIG should be treated similarly to individuals with ANC <500 with regards to imaging for infectious disease
- Some individuals are treated with very intensive chemotherapy regimens (including autologous stem cell transplantation) and spend the majority of their chemotherapy treatment phase in the hospital. See: **Hematopoietic Stem Cell Transplantation (ONC-29)**.

- Due to the high risk of invasive infections, frequent CT may be indicated to evaluate known sites of invasive fungal infection, and in general these should be approved as requested
  - ◆ Surveillance imaging of asymptomatic individuals to detect invasive fungal infection has not been shown to impact individual outcomes
    - Imaging requests are indicated when acute clinical decisions will be made based on the imaging

### **Hematopoietic Stem Cell Transplant (HSCT) in Pediatric Oncology:**

- Transplantation of hematopoietic stem cells from bone marrow, peripheral blood, or cord blood is commonly used in the following clinical situations:
  - ◆ High-risk or recurrent leukemia (allogeneic)
  - ◆ Recurrent lymphoma (allogeneic or autologous)
  - ◆ Hemophagocytic lymphohistiocytosis (allogeneic)
  - ◆ High-risk sickle cell disease (allogeneic)
  - ◆ High-risk neuroblastoma (autologous)
  - ◆ High-risk CNS tumors (autologous)
  - ◆ Recurrent Ewing sarcoma family of tumors (autologous, rarely allogeneic)
- Imaging considerations for HSCT should follow guidelines in: **Hematopoietic Stem Cell Transplantation (ONC-29)**.

### **Modality General Considerations (PEDONC-1.3)**

- Plain radiography
  - ◆ Chest x-ray (CXR) can provide a prompt means to evaluate primary intrathoracic tumors and continues to be the initial imaging study recommended to detect complications, such as suspected infection, in symptomatic individuals undergoing treatment.
  - ◆ CXR continues to be the initial imaging study recommended for pulmonary surveillance for some pediatric cancers. See diagnosis-specific guideline sections for details.
  - ◆ Plain radiography continues to be the initial imaging study recommended for evaluation of lesions involving the appendicular skeleton, both during and after completion of treatment. See diagnosis-specific guideline sections for details.
  - ◆ Plain abdominal radiographs have largely been replaced by ultrasound, CT, or MRI.
- Ultrasound
  - ◆ Ultrasound is not widely used in pediatric oncology for staging but is frequently used for surveillance in individuals who have successfully treated (primarily abdominal or pelvic) tumors with little or no residual disease.
  - ◆ See diagnosis-specific guideline sections for details.
- CT
  - ◆ CT with contrast is the imaging study of choice in pediatric individuals with lymphomas or solid tumors of the neck, thorax, abdomen, and/or pelvis

- If CT contrast use is contraindicated due to allergy or impaired renal function, either CT without contrast or MRI without and with contrast may be substituted at the discretion of the ordering physician
- MRI
  - ◆ MRI without and with contrast is the study of choice for CNS tumors and musculoskeletal tumors
    - If MRI contrast use is contraindicated due to allergy or impaired renal function, MRI without contrast may be substituted at the discretion of the ordering physician
  - ◆ Due to the length of time for image acquisition and the need for stillness, anesthesia is required for almost all infants and young children (age <7 years), as well as older children with delays in development or maturity. In this population, MRI imaging sessions should be planned with a goal of avoiding a short-interval repeat anesthesia exposure due to insufficient information using the following considerations:
    - MRI should always be performed without and with contrast unless there is a specific contraindication to gadolinium use since the individual already has intravenous access for anesthesia
      - Recent evidence-based literature demonstrates the potential for gadolinium deposition in various organs including the brain, after the use of MRI contrast
      - The U.S. Food and Drug Administration (FDA) has noted that there is currently no evidence to suggest that gadolinium retention in the brain is harmful and restricting gadolinium-based contrast agents (GBCAS) use is not warranted at this time
      - It has been recommended that GBCA use should be limited to circumstances in which additional information provided by the contrast agent is necessary and the necessity of repetitive MRIs with GBCAS should be assessed
      - If requesting clinicians indicate that a non-contrast study is being requested due to concerns regarding the use of gadolinium, the exam can be approved
    - If multiple body areas are supported by eviCore guidelines for the clinical condition being evaluated, MRI of all necessary body areas should be obtained concurrently in the same anesthesia session
- Nuclear medicine
  - ◆ General PET imaging consideration can be found in **PET Imaging in Pediatric Oncology (PEDONC-1.4)**.
  - ◆ Bone scan is frequently used for evaluation of bone metastases in pediatric oncology during initial treatment, treatment response, and surveillance
    - CPT® 78315 has no specific indications for evaluation of malignant disease
  - ◆ <sup>123</sup>I-metaiodobenzylguanidine (MIBG) scintigraphy is the preferred metabolic imaging for neuroblastoma and is positive in 90% to 95% of neuroblastomas. MIBG is also used for evaluation of pheochromocytomas, paragangliomas, ganglioneuromas, and ganglioneuroblastomas, PET/CT indications are provided in the relevant sections.



Study Type	Coding
Bone scan	<ul style="list-style-type: none"> <li>➤ ANY of the following codes can be approved:                             <ul style="list-style-type: none"> <li>◆ CPT® 78300</li> <li>◆ CPT® 78305</li> <li>◆ CPT® 78306</li> <li>◆ CPT® 78803, 78830, or 78832                                     <ul style="list-style-type: none"> <li>■ May be approved alone or in combination with:   <ul style="list-style-type: none"> <li>▪ CPT® 78305</li> <li>▪ CPT® 78306</li> </ul> </li> </ul> </li> </ul> </li> </ul>
<sup>123</sup> I- metaiodobenzylguanidine (MIBG) scintigraphy	<ul style="list-style-type: none"> <li>➤ ANY one of the following codes can be approved:                             <ul style="list-style-type: none"> <li>◆ CPT® 78801</li> <li>◆ CPT® 78802</li> <li>◆ CPT® 78804</li> </ul> </li> <li>➤ ANY one of the following codes may also be approved, individual or in combination with CPT® 78801, 78802 or 78804:                             <ul style="list-style-type: none"> <li>◆ CPT® 78803</li> <li>◆ CPT® 78830</li> <li>◆ CPT® 78831</li> <li>◆ CPT® 78832</li> <li>◆ CPT® 78800 may be approved for KNOWN neuroblastoma when only a single site follow up is desired but is not sufficient for the initial workup of suspected disease</li> </ul> </li> </ul>
Octreotide scan	<ul style="list-style-type: none"> <li>➤ Same coding as MIBG</li> </ul>
Gallium scan	<ul style="list-style-type: none"> <li>➤ Same coding as MIBG</li> </ul>

### **PET Imaging in Pediatric Oncology (PEDONC-1.4)**

**Throughout these guidelines, the term “PET” refers specifically to <sup>18</sup>F-FDG-PET imaging and also applies to PET/CT fusion studies.**

- PET imaging in pediatric oncology should use PET/CT fusion imaging (CPT® 78815 or CPT® 78816)
- The decision whether to use skull base to mid-femur (“eyes to thighs”) procedure code for PET (CPT® 78815) or whole-body PET (CPT® 78816) is addressed in the diagnosis-specific guideline sections.
- PET imaging in oncology should use PET/CT fusion imaging (CPT® 78815 or CPT® 78816)
- PET/MRI is generally not supported by eviCore for a vast majority of oncologic conditions due to lack of standardization in imaging technique and interpretation.

However, it may be approved in certain pediatric oncologic conditions when all of the following criteria are met:

- ◆ The individual **meets guideline criteria for PET/CT AND**
- ◆ PET/CT is **not** available at the treating institution **AND**
- ◆ The provider requests PET/MRI in lieu of PET/CT
  - When the above criteria are met, PET/MRI may be approved using the code combination of PET Whole-body (CPT® 78813) and MRI Unlisted (CPT® 76498). All other methods of reporting PET/MRI are inappropriate.
  - When clinically appropriate, diagnostic MRI codes may be approved at the same time as the PET/MRI code combination.
- Unbundling PET/CT imaging into separate PET (such as CPT® 78812 or CPT® 78813) and diagnostic CT codes is otherwise not supported.
- PET imaging is not reliable for the detection of anatomic lesions smaller than 8 mm in size.
- Delay PET/CT for at least 12 weeks after completion of radiation treatment, unless required sooner for imminent surgical resection.
- PET imaging using isotopes other than <sup>18</sup>F-FDG, <sup>68</sup>Ga-DOTATATE, or <sup>68</sup>Ga-DOTATOC is considered investigational at this time.
- PET has not been shown to be diagnostically useful in all forms of childhood cancer. PET is supported for pediatric malignancies with significant published evidence regarding its diagnostic accuracy and importance in accurately directing individual care decisions. See diagnosis-specific guideline sections for details.
- PET imaging is not specific to cancer, and has a high rate of false positivity. Inflammation, infection (especially granulomatous), trauma, and post-operative healing may show high levels of FDG uptake and be false-positive for malignant lesions.
- PET for rare malignancies not specifically addressed by eviCore guidelines is generally not indicated, due to lack of available evidence regarding diagnostic accuracy of PET in the majority of rare cancers. Conventional imaging studies should be used for initial staging and treatment response for these diagnoses.
- PET can be approved if **all** of the following apply:
  - ◆ Conventional imaging (CT, MRI, US, plain film) reveals findings that are equivocal or suspicious
  - ◆ No other specific metabolic imaging (MIBG, octreotide, technetium, etc.) is appropriate for the cancer type
  - ◆ The submitted clinical information describes a specific decision regarding the individual's care that will be made based on the PET results
- PET imaging for surveillance imaging **only** when specifically stated elsewhere in the diagnosis-specific guideline sections

- Unless otherwise specified for a specific cancer type, once PET has been documented to be negative for a given individual's cancer or all PET-avid disease has been surgically resected, PET should not be used for continued disease monitoring or surveillance unless **one** of the following applies:
  - ◆ Conventional imaging (CT, MRI, US, plain film) reveals findings that are inconclusive or suspicious for recurrence
    - Residual mass that has not changed in size since the last conventional imaging does **not** justify PET imaging
    - PET avidity in a residual mass at the end of planned therapy is **not** an indication for PET imaging during surveillance.
  - ◆ Very rare circumstances where tumor markers or obvious clinical symptoms show strong evidence suggesting recurrence and PET would replace conventional imaging modalities
  - ◆ The individual is undergoing salvage treatment for a recurrent solid tumor with residual measurable disease on conventional imaging and confirmed repeat negative PET imaging will allow the individual to transition from active treatment to surveillance

### **Diagnostic Radiation Exposure in Pediatric Oncology (PEDONC-1.5)**

- Young children are presumed to be at increased risk for malignancy from diagnostic radiation exposure, most commonly from CT and nuclear medicine imaging. They are more sensitive to radiation than adults and generally live longer after receiving radiation doses from medical procedures, resulting in a larger number of years during which to manifest a cancer.
- Because of this presumed increased risk in young children, requests to substitute MRI without and with contrast for CT with contrast to avoid radiation exposure can be approved if ALL of the following criteria apply:
  - ◆ The individual is presently a young child and the ordering physician has documented the reason for MRI, rather than CT, is to avoid radiation exposure.
  - ◆ The disease-specific guidelines do not list CT as superior to MRI for the current disease and time point, meaning the MRI will provide equivalent or superior information relative to CT.
  - ◆ The request is for a body area other than Chest as MRI is substantially inferior to CT for detection of small pulmonary metastases.
- The guidelines listed in this section for certain specific indications are not intended to be all-inclusive; clinical judgment remains paramount and variance from these guidelines may be appropriate and warranted for specific clinical situations.

## References

1. Krishnamurthy R, Daldrup-Link HE, Jones JY, et al. Imaging studies in the diagnosis and management of pediatric malignancies. In: Pizzo PA, Poplack DG, eds. *Principles and Practice of Pediatric Oncology*. 7th ed. Philadelphia, PA: Wolters Kluwer; 2016:185-238.
2. Allen-Rhoades W, Steuber CP. Clinical assessment and differential diagnosis of the child with suspected cancer. In: Pizzo PA, Poplack DG, eds. *Principles and Practice of Pediatric Oncology*. 7th ed. Philadelphia, PA: Wolters Kluwer; 2016:101-112.
3. Gottschalk S, Naik S, Hegde M, et al. Hematopoietic stem cell transplantation in pediatric oncology. In: Pizzo PA, Poplack DG, eds. *Principles and Practice of Pediatric Oncology*. 7th ed. Philadelphia, PA: Wolters Kluwer; 2016:419-440.
4. Freedman JL, Rheingold SR, and Fisher MJ. Oncologic emergencies. In: Pizzo PA, Poplack DG, eds. *Principles and Practice of Pediatric Oncology*. 7th ed. Philadelphia, PA: Wolters Kluwer; 2016:967-991.
5. Andrews J, Galel SA, Wong W, et al. Hematologic supportive care for children with cancer. In: Pizzo PA, Poplack DG, eds. *Principles and Practice of Pediatric Oncology*. 7th ed. Philadelphia, PA: Wolters Kluwer; 2016:992-1009.
6. Ardura MI, Koh AY. Infectious complications in pediatric cancer patients. In: Pizzo PA, Poplack DG, eds. *Principles and Practice of Pediatric Oncology*. 7th ed. Philadelphia, PA: Wolters Kluwer; 2016:1010-1057.
7. Shaikh R, Prabhu SP, Voss SD. Imaging in the evaluation and management of childhood cancer. In: Orkin SH, Fisher DE, Ginsburg D, Look AT, Lux SE, Nathan DG, eds. *Nathan and Oski's Hematology and Oncology of Infancy and Childhood*. 8th ed. Philadelphia, PA: Elsevier Saunders; 2015:2146-2254.
8. Sung L, Fisher BT, Koh AY. Infectious Disease in the pediatric cancer patient. In: Orkin SH, Fisher DE, Ginsburg D, Look AT, Lux SE, Nathan DG, eds. *Nathan and Oski's Hematology and Oncology of Infancy and Childhood*. 8th ed. Philadelphia, PA: Elsevier Saunders; 2015:2257-2266.
9. Mullen EA, Gratiot E. Oncologic emergencies. In: Orkin SH, Fisher DE, Ginsburg D, Look AT, Lux SE, Nathan DG, eds. *Nathan and Oski's Hematology and Oncology of Infancy and Childhood*. 8th ed. Philadelphia, PA: Elsevier Saunders; 2015:2267-2291.
10. Weiser DA, Kaste SC, Siegel MJ, et al. Imaging in childhood cancer: A society for Pediatric Radiology and Children's Oncology Group joint task force report. *Pediatr Blood Cancer*. 2013;60(8):1253-1260. doi:10.1002/pbc.24533.
11. American College of Radiology. ACR-ASER-SCBT-MR-SPR Practice Parameter for the Performance of Pediatric Computed Tomography (CT). 2014. <https://www.acr.org/-/media/ACR/Files/Practice-Parameters/CT-Ped.pdf>.
12. ACR-SPR Practice Parameter for the Performance and Interpretation of Pediatric Magnetic Resonance Imaging (MRI), Revised 2015 (Resolution 11). <https://www.acr.org/-/media/CB384A65345F402083639E6756CE513F.pdf>.
13. Smith EA, Dillman JR. Current role of body MRI in pediatric oncology. *Pediatr Radiol*. 2016;46(6):873-880. doi:10.1007/s00247-016-3560-8.
14. The Center for Drug Evaluation and Research. Meeting of the Medical Imaging Drugs Advisory Committee, presented September 8, 2017. <https://www.fda.gov/downloads/AdvisoryCommittees/CommitteesMeetingMaterials/Drugs/MedicalImagingDrugsAdvisoryCommittee/UCM574746.pdf>.
15. Uslu L, Doing J, Link M, et al. Value of 18F-FDG PET and PET/CT for evaluation of pediatric malignancies. *J Nucl Med*. 2015;56(2):274-286. doi:10.2967/jnumed.114.146290.
16. McCarville MB. PET-CT imaging in pediatric oncology. *Cancer Imaging*. 2009(1);9:35-43. doi:10.1102/1470-7330.2009.0008.
17. Matthews JD, Forsythe AV, Brady Z, et al. Cancer risk in 680 000 people exposed to computed tomography scans in childhood or adolescence: data linkage study of 11 million Australians. *BMJ*. 2013;346:f2360. doi:10.1136/bmj.f2360.
18. Erdi YE. Limits of tumor detectability in nuclear medicine and PET. *Mol Imaging Radio Nucl Ther*. 2012;21(1):23-28. doi:10.4274/Mirt.138.
19. Ing C, DiMaggio C, Whitehouse A, et al. Long-term differences in language and cognitive function after childhood exposure to anesthesia. *Pediatrics*. 2012;130(3):e476-e485. doi:10.1542/peds.2011-3822.
20. Monteleone M, Khandji A, Cappell J, et al. Anesthesia in children: perspectives from nonsurgical pediatric specialists. *J Neurosurg Anesthesiol*. 2014;26(4):396-398. doi:10.1097/ANA.000000000000124.
21. DiMaggio C, Sun LS, Li G. Early childhood exposure to anesthesia and risk of developmental and behavioral disorders in a sibling birth cohort. *Anesth Analg*. 2011;113(5):1143-1151. doi:10.1213/ANE.0b013e3182147f42.
22. Brody AS, Guillerman RP. Don't let radiation scare trump patient care: 10 ways you can harm your patients by fear of radiation-induced cancer from diagnostic imaging. *Thorax*. 2014;69(8):782-784. doi:10.1136/thoraxjnl-2014-205499.
23. Meulepas JM, Ronckers CM, Smets AMJB, et al. Radiation exposure from pediatric CT scans and subsequent cancer risk in the Netherlands, *JNCI J Natl Cancer Inst*. 2019;111:256-2634. doi: 10.1093/jnci/djy104.

24. Bhatia S, Pappo AS, Acquazzino M, et al. National Comprehensive Cancer Network (NCCN) Guidelines Version 1.2023—June 29, 2022, Adolescent and Young Adult (AYA) Oncology, available at: [https://www.nccn.org/professionals/physician\\_gls/pdf/aya.pdf](https://www.nccn.org/professionals/physician_gls/pdf/aya.pdf), referenced with permission from the NCCN  
  
Clinical Practice Guidelines in Oncology (NCCN Guidelines™) for Adolescent and Young Adult (AYA) Oncology V1.2023 06/29/2022. ©2022 National Comprehensive Cancer Network, Inc. All rights reserved. The NCCN Guidelines™ and illustrations herein may not be reproduced in any form for any purpose without the express written permission of the NCCN. To view the most recent and complete version of the NCCN Guidelines™, go online to NCCN.org.
25. States LJ, Reid JR. Whole-Body PET/MRI applications in pediatric oncology. *AJR Am J Roentgenol*. 2020;215(3):713-725. doi:10.2214/AJR.19.22677.
26. Mayerhoefer ME, Archibald SJ, Messiou C, Staudenherz A, Berzaczy D, Schöder H. MRI and PET/MRI in hematologic malignancies. *J Magn Reson Imaging*. 2020;51(5):1325-1335. doi:10.1002/jmri.26848.
27. Sher AC, Seghers V, Paldino MJ, et. al. Assessment of sequential PET/MRI in comparison with PET/CT of pediatric lymphoma: a prospective study. *AJR Am J Roentgenol*. 2016;206(3):623-31. doi:10.2214/AJR.15.15083.

## Screening Imaging in Cancer Predisposition Syndromes (PEDONC-2)

Screening Imaging in Cancer Predisposition Syndromes – General Considerations (PEDONC-2.1)

Li-Fraumeni Syndrome (LFS) (PEDONC-2.2)

Neurofibromatosis 1 and 2 (NF1 and NF2) (PEDONC-2.3)

Beckwith-Wiedemann Syndrome (BWS) (PEDONC-2.4)

Denys-Drash Syndrome (DDS) (PEDONC-2.5)

Wilms Tumor-Aniridia-Growth Retardation (WAGR) (PEDONC-2.6)

Familial Adenomatous Polyposis (FAP) and Related Conditions (PEDONC-2.7)

Multiple Endocrine Neoplasias (MEN) (PEDONC-2.8)

Tuberous Sclerosis Complex (TSC) (PEDONC-2.9)

Von Hippel-Lindau Syndrome (VHL) (PEDONC-2.10)

Rhabdoid Tumor Predisposition Syndrome (PEDONC-2.11)

Familial Retinoblastoma Syndrome (PEDONC-2.12)

Hereditary Paraganglioma-Pheochromocytoma (HPP) Syndromes (PEDONC-2.13)

Costello Syndrome (PEDONC-2.14)

Constitutional Mismatch Repair Deficiency (CMMRD or Turcot Syndrome) (PEDONC-2.15)

Hereditary Leiomyomatosis and Renal Cell Cancer (HLRCC) (PEDONC-2.16)

Other Renal Cell Cancer Predisposition Syndromes (PEDONC-2.17)

Infantile Myofibromatosis (PEDONC-2.18)

## **Screening Imaging in Cancer Predisposition Syndromes – General Considerations (PEDONC-2.1)**

- This section is intended to give guidance for screening imaging prior to diagnosis with a specific malignancy. Once an individual with a cancer predisposition syndrome has been diagnosed with a malignant disease, future imaging decisions should be guided by the appropriate disease-specific guidelines except as explicitly stated elsewhere in this section.
- This section’s guidelines are limited to cancer predisposition syndromes with screening imaging considerations. Syndromes requiring only clinical or laboratory screening are not discussed here.
- In general, a recent (within 60 days) detailed history and physical examination and appropriate laboratory studies should be performed prior to considering advanced imaging, unless the individual is undergoing guideline-supported scheduled screening evaluation identified in this section.
- Where MRI is indicated in these guidelines, CT may be approved only if MRI is contraindicated, given the risk of radiation exposure in these syndromes.
- Many of these cancer predisposition syndromes also affect adults as survival continues to improve for these individuals.
  - ◆ Adults with syndromes covered in this section may follow these imaging guidelines except where contradicted by specific statements in the general imaging guidelines.
- Documentation of genetic or molecular confirmation of the appropriate syndrome with increased cancer risk is preferred for any individual to qualify for screening imaging. There are a number of complex ethical, social, and financial issues involved in the decision to complete genetic testing in a pediatric individual.
  - ◆ From the 2013 AAP Policy Statement, “Predictive genetic testing for adult-onset conditions generally should be deferred unless an intervention initiated in childhood may reduce morbidity or mortality.” ***Imaging surveillance is one such intervention and should not be performed without justifiable cause.***
  - ◆ Genetic testing should be performed in conjunction with genetic counseling for appropriate communication of risks identified by testing.
  - ◆ When genetic testing is not possible or not supported by health plan coverage policies, formal diagnosis after evaluation by a physician with significant training and/or experience in cancer predisposition syndromes (most commonly a geneticist or oncologist) is generally sufficient to confirm eligibility for screening imaging.

- Due to the length of time for image acquisition and the need for stillness, anesthesia is required for almost all infants and young children (age < 7 years), as well as older children with delays in development or maturity. In this patient population, MRI imaging sessions should be planned with a goal of avoiding a short-interval repeat anesthesia exposure due to insufficient information using the following considerations:
  - ◆ MRI should always be performed without and with contrast unless there is a specific contraindication to gadolinium use, since the individual already has intravenous access for anesthesia.
    - Recent evidence-based literature demonstrates the potential for gadolinium deposition in various organs including the brain, after the use of MRI contrast.
    - The U.S. food and drug administration (FDA) has noted that there is currently no evidence to suggest that gadolinium retention in the brain is harmful and restricting gadolinium-based contrast agents (GBCAS) use is not warranted at this time. It has been recommended that GBCA use should be limited to circumstances in which additional information provided by the contrast agent is necessary and the necessity of repetitive MRIs with GBCAS should be assessed.
    - If requesting clinicians indicate that a non-contrast study is being requested due to concerns regarding the use of gadolinium, the exam can be approved.
  - ◆ If multiple body areas are supported by eviCore guidelines for the clinical condition being evaluated, MRI of all necessary body areas should be obtained concurrently in the same anesthesia session

### **Li-Fraumeni Syndrome (LFS) (PEDONC-2.2)**

**The following imaging studies should be considered appropriate in individuals with LFS:**

Indication	Imaging Study
All individuals	<ul style="list-style-type: none"> <li>➤ BOTH of the following, annually:                             <ul style="list-style-type: none"> <li>◆ MRI Brain without and with contrast (CPT® 70553)</li> <li>◆ Whole-body MRI (WBMRI, CPT® 76498)                                     <ul style="list-style-type: none"> <li>■ CPT® 76498 is the only approvable code for whole-body MRI at this time.</li> </ul> </li> </ul> </li> <li>➤ Every 3 months from birth to age 18:                             <ul style="list-style-type: none"> <li>◆ Abdominal (CPT® 76700) and pelvic (CPT® 76856) ultrasound</li> </ul> </li> <li>➤ Beginning at age 20:                             <ul style="list-style-type: none"> <li>◆ Annual Breast MRI (CPT® 77049), alternating every 6 months with breast ultrasound, in addition to the previously noted annual MRI studies.</li> </ul> </li> </ul>
Documented signs or symptoms suggestive of possible malignancy	<ul style="list-style-type: none"> <li>➤ Targeted MRI without and with contrast of the involved body area(s)</li> </ul>



## Background and Supporting Information

- LFS - syndrome inherited in an autosomal dominant manner (50% risk to offspring) associated with germline mutations in *TP53* resulted in an increased susceptibility to a variety of cancers.
  - ◆ Eighty percent of individuals will have germline *TP53* mutation:
    - Tumor-specific *TP53* mutations are much more common than germline *TP53* mutations and are not associated with an increased risk for subsequent cancers
    - If *TP53*-negative, formal diagnosis of LFS should be assigned by a physician with significant training and/or experience in LFS (most commonly a geneticist or oncologist) based on specified clinical criteria prior to beginning a screening imaging program
    - *TP53* mutations may be present in 50% to 80% of pediatric adrenocortical carcinoma, 10% of pediatric rhabdomyosarcoma, and 10% of pediatric osteosarcoma
- Individuals with LFS have an increased sensitivity to ionizing radiation, so screening strategies resulting in significant radiation exposure are not appropriate (CT and nuclear medicine).
- When a specific malignancy is suspected, the individual should be imaged according to the eviCore imaging guideline specific to the suspected cancer type
- Annual complete detailed physical examinations, complete blood counts, and urinalyses form the backbone of LFS cancer screening.

## Neurofibromatosis 1 and 2 (NF1 and NF2) (PEDONC-2.3)

### **The following imaging studies should be considered appropriate in individuals with NF1:**

Indication	Imaging Study
<ul style="list-style-type: none"> <li>➤ Clarification of the diagnosis of NF1 if evaluation by a physician with significant training and/or experience in neurofibromatosis is inconclusive                             <ul style="list-style-type: none"> <li>◆ Most commonly a neurologist, geneticist, ophthalmologist, or oncologist</li> </ul> </li> </ul>	<ul style="list-style-type: none"> <li>➤ One-time MRI Brain (CPT® 70553) and Orbits (CPT® 70543) without and with contrast</li> </ul>
<ul style="list-style-type: none"> <li>➤ New or worsening neurological or visual symptoms</li> </ul>	<ul style="list-style-type: none"> <li>➤ MRI Brain (CPT® 70553) and Orbits (CPT® 70543) without and with contrast</li> </ul>
<ul style="list-style-type: none"> <li>➤ Clinical symptoms suggestive of change in a known plexiform neurofibroma                             <ul style="list-style-type: none"> <li>◆ Examples include: pain, rapid growth, and neurologic dysfunction</li> </ul> </li> </ul>	<ul style="list-style-type: none"> <li>➤ MRI without and with contrast</li> </ul>
<ul style="list-style-type: none"> <li>➤ <u>Clinical symptoms concerning for malignant transformation of a known plexiform neurofibroma, and ALL of the following are met:</u></li> </ul>	<ul style="list-style-type: none"> <li>➤ PET/CT (CPT® 78815 or 78816)</li> </ul>

Indication	Imaging Study
<ul style="list-style-type: none"> <li>◆ Recent MRI is inconclusive regarding transformation or progression</li> <li>◆ Negative PET will result in a decision to avoid biopsy in a difficult or morbid location</li> </ul>	
<ul style="list-style-type: none"> <li>➤ Baseline tumor burden at age 16 or older (one-time imaging)</li> </ul>	<ul style="list-style-type: none"> <li>➤ WBMBRI (CPT® 76498)</li> </ul>
<ul style="list-style-type: none"> <li>➤ New soft tissue mass(es)</li> </ul>	<ul style="list-style-type: none"> <li>➤ See: <b>MS-10.1</b> in the Musculoskeletal Imaging Guidelines or <b>PEDMS-3.2</b> in the Pediatric Musculoskeletal Imaging Guidelines depending on the individual's age at the time the mass is discovered. Plain x-ray or ultrasound is not required prior to advanced imaging in these individuals.</li> </ul>
<ul style="list-style-type: none"> <li>➤ New bone mass(es)</li> </ul>	<ul style="list-style-type: none"> <li>➤ See: <b>Bone Tumors (PEDONC-9.1)</b></li> </ul>
<ul style="list-style-type: none"> <li>➤ Documented optic pathway gliomas</li> </ul>	<ul style="list-style-type: none"> <li>➤ See: <b>Intracranial Low Grade Gliomas (PEDONC-4.2)</b></li> </ul>
<ul style="list-style-type: none"> <li>➤ Known plexiform neurofibromas</li> </ul>	<ul style="list-style-type: none"> <li>➤ MRI without and with contrast of a known body area containing a neurofibroma is indicated for any of the following:                             <ul style="list-style-type: none"> <li>◆ Every 3 months for treatment response in individuals receiving active treatment</li> <li>◆ New or worsening clinical symptoms suggesting progression</li> <li>◆ Preoperative planning</li> </ul> </li> </ul>
<ul style="list-style-type: none"> <li>➤ Biopsy-proven MPNST in individuals with known NF-1 or NF-2</li> </ul>	<ul style="list-style-type: none"> <li>➤ See: <b>Non-Rhabdomyosarcoma Soft Tissue Sarcomas (NRSTS) (PEDONC-8.3)</b></li> </ul>

## Background and Supporting Information

### **NF1:**

- Common syndrome inherited in an autosomal dominant manner (50% risk to offspring) affecting 1 in 2500 people. The diagnosis is commonly made based on established clinical criteria including café-au-lait spots, lisch nodules of the iris, axillary freckling, family history, and the presence of NF-associated tumors.
- Genetic testing is encouraged for children with possible NF1 and no family history prior to assigning a diagnosis but will not identify a mutation for all individuals with NF1.
- The majority of tumors are benign in nature, but malignant degeneration can occur. The most frequent neoplasms associated with NF1 in children are malignant peripheral nerve sheath tumor (MPNST), glioma, pheochromocytoma, and leukemia.
- NF1-affected persons have increased sensitivity to ionizing radiation, so CT and nuclear medicine imaging are not appropriate screening or surveillance studies for these individuals.
- CT and/or nuclear medicine studies may be indicated for acute clinical situations and should be judged on a case-by-case basis.
- Annual ophthalmology evaluation is strongly recommended beginning at the time of diagnosis of NF1 to evaluate for optic pathway abnormalities:
  - ◆ Screening MRIs Brain (CPT® 70553) and Orbits (CPT® 70543) for asymptomatic individuals are **not** generally recommended due to the ~60% rate of unidentified bright objects (UBOs, T2-weighted signal abnormalities) which mostly disappear by age 30
    - Routine follow up imaging of UBOs is not warranted in the absence of acute symptoms suggesting new or worsening intracranial disease
- Individuals with NF1 are at increased risk for plexiform neurofibromas (PN) and malignant peripheral nerve sheath tumors (MPNST— a high grade sarcoma)
  - ◆ Screening imaging of asymptomatic individuals for these tumors is not supported by evidence. PET imaging is not supported for PN surveillance in asymptomatic individuals at this time as the positive predictive value is only 60% to 65% even in symptomatic individuals.
- Although PET imaging has a positive predictive value of only 61% to 63% in NF1 with suspected transformation to MPNST, the negative predictive value is high (96% to 99%)
  - ◆ Considerations for PET/CT coding and indications/coding for PET/MRI are found in **PET Imaging in Pediatric Oncology (PEDONC-1.4)**
  - ◆ Inconclusive PET findings should lead to biopsy of the concerning lesion
  - ◆ Repeat PET studies are not indicated due to the poor positive predictive value in this setting
- 2017 AACR recommendations support a single baseline Whole-Body MRI to assess tumor burden in late adolescence or young adulthood. Further imaging should be based on focused MRI for symptomatic changes or pre-operative planning, and

further surveillance WBMRI are not supported.

**The following imaging studies should be considered appropriate in individuals with NF2:**

Indication	Imaging Study
<ul style="list-style-type: none"> <li>➤ All individuals, beginning at age 10 years</li> </ul>	<ul style="list-style-type: none"> <li>➤ Annual MRI Brain without and with contrast (CPT® 70553)</li> </ul>
<ul style="list-style-type: none"> <li>➤ All individuals without a history of spinal tumors, beginning at age 10 years</li> </ul>	<ul style="list-style-type: none"> <li>➤ MRI Spine without and with contrast (Cervical-CPT® 72156, Thoracic-CPT® 72157, Lumbar-CPT® 72158) every 3 years</li> </ul>
<ul style="list-style-type: none"> <li>➤ All individuals with a history of spinal tumors</li> </ul>	<ul style="list-style-type: none"> <li>➤ Annual MRI Spine without and with contrast (Cervical-CPT® 72156, Thoracic-CPT® 72157, Lumbar-CPT® 72158)</li> </ul>
<ul style="list-style-type: none"> <li>➤ Clinical symptoms of intracranial mass or vestibular disease</li> </ul>	<ul style="list-style-type: none"> <li>➤ MRI Brain without and with contrast (CPT® 70553)</li> </ul>
<ul style="list-style-type: none"> <li>➤ <u>Any of the following:</u> <ul style="list-style-type: none"> <li>◆ Clinical symptoms suggestive of new or progressive spinal or paraspinal tumors, including uncomplicated back pain or radiculopathy</li> <li>◆ Recent diagnosis with a meningioma or vestibular schwannoma</li> </ul> </li> </ul>	<ul style="list-style-type: none"> <li>➤ MRI Spine without and with contrast (Cervical-CPT® 72156, Thoracic-CPT® 72157, Lumbar-CPT® 72158)</li> </ul>
<ul style="list-style-type: none"> <li>➤ Surveillance for progression of unresected tumors in individuals with known vestibular schwannoma</li> </ul>	<ul style="list-style-type: none"> <li>➤ Annual MRI Brain without and with contrast (CPT® 70553)</li> </ul>
<ul style="list-style-type: none"> <li>➤ <u>Known vestibular schwannomas and any of the following:</u> <ul style="list-style-type: none"> <li>◆ New or worsening clinical symptoms including hearing loss</li> <li>◆ Preoperative planning</li> </ul> </li> </ul>	<ul style="list-style-type: none"> <li>➤ MRI Brain without and with contrast (CPT® 70553)</li> </ul>
<ul style="list-style-type: none"> <li>➤ Known meningioma</li> </ul>	<ul style="list-style-type: none"> <li>➤ See: <b><u>Meningiomas</u></b> in the <b><u>Oncology Imaging Guidelines (ONC-2.8)</u></b></li> </ul>
<ul style="list-style-type: none"> <li>➤ Known ependymoma</li> </ul>	<ul style="list-style-type: none"> <li>➤ See: <b><u>Ependymoma (PEDONC-4.8)</u></b></li> </ul>

***Background and Supporting Information***

**NF2:**

- NF2 is substantially less common than NF1. It is inherited in an autosomal dominant manner (50% risk to offspring) affecting ~1 in 25000 people. NF2 is associated with increased risk for meningiomas (50% of affected individuals), vestibular schwannomas, and spinal tumors (75% of affected individuals).

## **Beckwith-Wiedemann Syndrome (BWS) (PEDONC-2.4)**

**The following imaging studies should be considered appropriate in individuals with BWS:**

<b>Indication</b>	<b>Imaging Study</b>
<ul style="list-style-type: none"> <li>➤ All individuals, from birth to the 8<sup>th</sup> birthday</li> </ul>	<ul style="list-style-type: none"> <li>➤ Abdominal ultrasound (CPT® 76700) every 3 months</li> </ul>
<ul style="list-style-type: none"> <li>➤ Purely cystic adrenal mass found on screening ultrasound</li> </ul>	<ul style="list-style-type: none"> <li>➤ Continue screening ultrasound (CPT® 76700 or 76705) every 3 months without additional imaging (i.e. advanced imaging is not supported for a purely cystic adrenal mass)</li> </ul>
<ul style="list-style-type: none"> <li>➤ <u>Solid or mixed adrenal mass found on screening ultrasound AND:</u> <ul style="list-style-type: none"> <li>◆ Individual age 0 to 5 months, and</li> <li>◆ Mass 0 to 3 cm in diameter</li> </ul> </li> </ul>	<ul style="list-style-type: none"> <li>➤ MIBG imaging (See: <b><u>PEDONC-1.3</u></b> for coding) and either CT or MRI Abdomen (contrast as requested)</li> </ul>
<ul style="list-style-type: none"> <li>➤ Solid or mixed adrenal mass found on screening ultrasound AND: <ul style="list-style-type: none"> <li>◆ Individual age 0 to 5 months, and</li> <li>◆ Mass &gt; 3 cm in diameter</li> </ul> </li> </ul>	<ul style="list-style-type: none"> <li>➤ MIBG imaging (See: <b><u>PEDONC-1.3</u></b> for coding) and MRI Abdomen (contrast as requested)</li> </ul>
<ul style="list-style-type: none"> <li>➤ <u>Solid or mixed adrenal masses on screening ultrasound AND:</u> <ul style="list-style-type: none"> <li>◆ Individual age 6 months or greater</li> </ul> </li> </ul>	<ul style="list-style-type: none"> <li>➤ MIBG imaging (See: <b><u>PEDONC-1.3</u></b> for coding) prior to biopsy or resection <ul style="list-style-type: none"> <li>◆ If no evidence of malignancy on biopsy or resection, resume screening abdominal ultrasound every 3 months</li> </ul> </li> </ul>
<ul style="list-style-type: none"> <li>➤ <u>Solid or mixed adrenal masses on screening ultrasound AND:</u> <ul style="list-style-type: none"> <li>◆ No evidence of malignancy based on MIBG, CT or MRI, Urine HVA/VMA, and serum ACTH</li> </ul> </li> </ul>	<ul style="list-style-type: none"> <li>➤ Repeat abdominal ultrasound (CPT® 76700 or 76705) every 6 weeks for 2 years</li> </ul>
<ul style="list-style-type: none"> <li>➤ Known renal tumors</li> </ul>	<ul style="list-style-type: none"> <li>➤ See: <b><u>Pediatric Renal Tumors (PEDONC-7)</u></b></li> </ul>
<ul style="list-style-type: none"> <li>➤ Known hepatoblastoma</li> </ul>	<ul style="list-style-type: none"> <li>➤ See: <b><u>Hepatoblastoma (PEDONC-11.2)</u></b></li> </ul>
<ul style="list-style-type: none"> <li>➤ Known neuroblastoma</li> </ul>	<ul style="list-style-type: none"> <li>➤ See: <b><u>Neuroblastoma (PEDONC-6)</u></b></li> </ul>
<ul style="list-style-type: none"> <li>➤ Known adrenocortical carcinoma</li> </ul>	<ul style="list-style-type: none"> <li>➤ See: <b><u>Pediatric Adrenocortical Carcinoma (PEDONC-14)</u></b></li> </ul>
<ul style="list-style-type: none"> <li>➤ Known pheochromocytoma</li> </ul>	<ul style="list-style-type: none"> <li>➤ See: <b><u>Neuroendocrine Cancers and Adrenal Tumors (ONC-15)</u></b> in the Oncology Imaging Guidelines</li> </ul>

### ***Background and Supporting Information***

- Inherited syndrome characterized by macroglossia, hemihypertrophy, macrosomia, organomegaly, and neonatal hypoglycemia. Individuals with isolated hemihypertrophy are also imaged according to this guideline.
- Caused by mutation at chromosome 11p15, affected children are predisposed to Wilms tumor, hepatoblastoma, rhabdomyosarcoma, and adrenal tumors.

## **Denys-Drash Syndrome (DDS) (PEDONC-2.5)**

**The following imaging studies should be considered appropriate in individuals with DDS:**

<b>Indication</b>	<b>Imaging Study</b>
<ul style="list-style-type: none"><li>➤ All individuals, from birth to the 8<sup>th</sup> birthday</li></ul>	<ul style="list-style-type: none"><li>➤ Abdominal ultrasound (CPT® 76700) every 3 months</li></ul>
<ul style="list-style-type: none"><li>➤ Known renal tumors</li></ul>	<ul style="list-style-type: none"><li>➤ See: <b><u>Pediatric Renal Tumors (PEDONC-7)</u></b></li></ul>

### ***Background and Supporting Information***

- Characterized by pseudohermaphroditism, early renal failure, and >90% risk of Wilms tumor development in each kidney. Associated with mutations at 11p13, risk of renal failure after detection of symptomatic Wilms tumor is 62%, so early detection may allow for renal-sparing surgical approaches.

## **Wilms Tumor-Aniridia-Growth Retardation (WAGR) (PEDONC-2.6)**

**The following imaging studies should be considered appropriate in individuals with WAGR:**

<b>Indication</b>	<b>Imaging Study</b>
<ul style="list-style-type: none"><li>➤ All individuals, from birth to the 8<sup>th</sup> birthday</li></ul>	<ul style="list-style-type: none"><li>➤ Abdominal ultrasound (CPT® 76700) every 3 months</li></ul>
<ul style="list-style-type: none"><li>➤ Known renal tumors</li></ul>	<ul style="list-style-type: none"><li>➤ See: <b><u>Pediatric Renal Tumors (PEDONC-7)</u></b></li></ul>

### ***Background and Supporting Information***

- Named for the components of the disorder, it is associated with mutations at 11p13. As the name suggests, individuals are predisposed to Wilms tumor, with 57% of individuals in one cohort developing Wilms tumor. Risk of renal failure after detection of symptomatic Wilms tumor is 38%, so early detection may allow for renal-sparing surgical approaches

## **Familial Adenomatous Polyposis (FAP) and Related Conditions (PEDONC-2.7)**

- Individuals with Lynch, Gardner, and Turcot syndromes should also be imaged according to these guidelines.

**The following imaging studies should be considered appropriate in individuals with FAP and related conditions:**

- For colonoscopy and endoscopy guidance for those with FAP and related conditions, See: **Genetic Syndromes (EGD-1.16, CAPEND-5, or COLON-17)** for the endoscopic management of polyposis syndromes.

Indication	Imaging Study
<ul style="list-style-type: none"> <li>➤ All individuals, from birth to the 6<sup>th</sup> birthday</li> </ul>	<ul style="list-style-type: none"> <li>➤ Abdominal ultrasound (CPT® 76700) every 3 months</li> </ul>
<ul style="list-style-type: none"> <li>➤ All individuals, beginning at age 12 years</li> </ul>	<ul style="list-style-type: none"> <li>➤ Annual thyroid ultrasound (CPT® 76536)</li> </ul>
<ul style="list-style-type: none"> <li>➤ All individuals, beginning at age 30 years</li> </ul>	<ul style="list-style-type: none"> <li>➤ Annual pelvic ultrasound (CPT® 76856)</li> </ul>
<ul style="list-style-type: none"> <li>➤ Family history of desmoid tumors</li> </ul>	<ul style="list-style-type: none"> <li>➤ Abdominal ultrasound (CPT® 76700) annually for life after age 6</li> </ul>
<ul style="list-style-type: none"> <li>➤ Individuals with Spigelman Stage III or IV or if duodenectomy is being planned                             <ul style="list-style-type: none"> <li>◆ See: <b><u>Genetic Syndromes (EGD-1.16)</u></b> for additional information regarding Spigelman staging.</li> </ul> </li> </ul>	<ul style="list-style-type: none"> <li>➤ MR Enterography (MRI Abdomen without and with contrast, CPT® 74183 and MRI Pelvis without and with contrast, CPT® 72197)</li> </ul>
<ul style="list-style-type: none"> <li>➤ Known colorectal tumors</li> </ul>	<ul style="list-style-type: none"> <li>➤ See: <b><u>Colorectal Cancer (ONC-16)</u></b> in the Oncology Imaging Guidelines</li> </ul>
<ul style="list-style-type: none"> <li>➤ Known desmoid tumors</li> </ul>	<ul style="list-style-type: none"> <li>➤ See: <b><u>Non-Rhabdomyosarcoma Soft Tissue Sarcomas (NRSTS) (PEDONC-8.3)</u></b></li> </ul>

### Background and Supporting Information

- Inherited in an autosomal dominant manner (50% risk to offspring), it is also known as Adenomatous Polyposis Coli (APC). It is associated with the development of thousands of colonic polyps by age 20 and >90% risk of colorectal carcinoma. Prophylactic total colectomy is recommended by age 20 for most individuals. FAP is also associated with hepatoblastoma, tumors of the pancreas and small bowel, medulloblastoma, and thyroid cancer.

### Multiple Endocrine Neoplasias (MEN) (PEDONC-2.8)

**The following imaging studies should be considered appropriate in individuals with MEN1:**

Indication	Imaging Study
<ul style="list-style-type: none"> <li>➤ All individuals, beginning at age 5 years</li> </ul>	<ul style="list-style-type: none"> <li>➤ Annual MRI Brain without and with contrast (CPT® 70553)</li> <li>➤ Annual MRI Abdomen without and with contrast (CPT® 74183), CT Abdomen with contrast (CPT® 74160), or ultrasound (CPT® 76700)</li> <li>➤ Annual Octreotide study (see: <b><u>PEDONC-1.3</u></b> for coding)</li> </ul>
<ul style="list-style-type: none"> <li>➤ All individuals, beginning at age 15 years</li> </ul>	<ul style="list-style-type: none"> <li>➤ Annual MRI Chest without and with contrast (CPT® 71552) or CT Chest with contrast (CPT® 71260)</li> </ul>
<ul style="list-style-type: none"> <li>➤ Known thyroid cancer</li> </ul>	<ul style="list-style-type: none"> <li>➤ See: <b><u>Thyroid Cancer (ONC-6)</u></b> in the Oncology Imaging Guidelines</li> </ul>
<ul style="list-style-type: none"> <li>➤ Known pheochromocytoma</li> </ul>	<ul style="list-style-type: none"> <li>➤ See: <b><u>Neuroendocrine Cancers and Adrenal Tumors (ONC-15)</u></b> in the Oncology Imaging Guidelines</li> </ul>

**The following imaging studies should be considered appropriate in individuals with MEN2a and MEN2b:**

Indication	Imaging Study
<ul style="list-style-type: none"> <li>➤ All individuals, beginning at age 5 years</li> </ul>	<ul style="list-style-type: none"> <li>➤ MRI Abdomen without and with contrast (CPT® 74183) can be approved every 3 years</li> </ul>
<ul style="list-style-type: none"> <li>➤ <u>One of the following:</u> <ul style="list-style-type: none"> <li>◆ Elevated catecholamines</li> <li>◆ Inconclusive adrenal mass on MRI</li> </ul> </li> </ul>	<ul style="list-style-type: none"> <li>➤ <u>ONE of the following:</u> <ul style="list-style-type: none"> <li>◆ Octreotide study (see: <b>PEDONC-1.3</b> for coding)</li> <li>◆ Adrenal Nuclear Imaging (CPT® 78075)</li> </ul> </li> </ul>
<ul style="list-style-type: none"> <li>➤ Known pheochromocytoma</li> </ul>	<ul style="list-style-type: none"> <li>➤ See: <b><u>Neuroendocrine Cancers and Adrenal Tumors (ONC-15)</u></b></li> </ul>

**Background and Supporting Information**

- Inherited in an autosomal dominant manner (50% risk to offspring)
- MEN1 is characterized by parathyroid, pancreatic islet cell, and pituitary gland tumors (3 P’s), as well as carcinoid tumors in the chest and abdomen, and 28% of individuals will develop at least one tumor by age 15.
- MEN2a is characterized by medullary thyroid carcinoma, parathyroid adenomas, and pheochromocytomas.
- MEN2b is characterized by ganglioneuromas of the GI tract and skeletal abnormalities presenting in infancy.
- Recommended cancer screening includes:
  - ◆ Individuals with MEN2a and MEN2b receive annual measurement of catecholamines for pheochromocytoma screening

**Tuberous Sclerosis Complex (TSC) (PEDONC-2.9)**

- Abdominal MRI (CPT® 74183) may be approved for women of childbearing age planning pregnancy.

**The following imaging studies should be considered appropriate in individuals with TSC:**

Indication	Imaging Study
<ul style="list-style-type: none"> <li>➤ All individuals, at the time of suspected diagnosis until age 25 years</li> </ul>	<ul style="list-style-type: none"> <li>➤ Annual Brain MRI without and with contrast (CPT® 70553)</li> </ul>
<ul style="list-style-type: none"> <li>➤ All individuals at diagnosis</li> </ul>	<ul style="list-style-type: none"> <li>➤ Single baseline MRI Abdomen without and with contrast (CPT® 74183)</li> </ul>



Indication	Imaging Study
<ul style="list-style-type: none"> <li>➤ If no renal lesions seen on baseline MRI Abdomen</li> </ul>	<ul style="list-style-type: none"> <li>➤ From diagnosis through age 11:                             <ul style="list-style-type: none"> <li>◆ Annual Renal US (CPT® 76770)</li> </ul> </li> <li>➤ Age 12 (or 10 years earlier than the youngest family member with renal cell carcinoma, whichever comes earlier):                             <ul style="list-style-type: none"> <li>◆ MRI Abdomen without and with contrast (CPT® 74183) every 3 years in lieu of ultrasound</li> </ul> </li> </ul>
<ul style="list-style-type: none"> <li>➤ For documented renal lesions on baseline MRI Abdomen or any ultrasound</li> </ul>	<ul style="list-style-type: none"> <li>➤ MRI Abdomen without and with contrast (CPT® 74183) annually</li> </ul>
<ul style="list-style-type: none"> <li>➤ All individuals, beginning at age 18 years</li> </ul>	<ul style="list-style-type: none"> <li>➤ CT Chest without contrast (CPT® 71250) every 5 years</li> </ul>
<ul style="list-style-type: none"> <li>➤ All individuals, for cardiac screening or follow up of known cardiac disease</li> </ul>	<ul style="list-style-type: none"> <li>➤ See: <b><u>Initial Transthoracic Echocardiography (TTE) Indications (PEDCD-8.2) and Repeat Transthoracic Echocardiography Indications (PEDCD-8.3)</u></b> in the Pediatric Cardiology Imaging Guidelines</li> </ul>
<ul style="list-style-type: none"> <li>➤ Individuals with documented abnormalities on baseline CT Chest</li> </ul>	<ul style="list-style-type: none"> <li>➤ Additional CT Chest without contrast or with contrast (CPT® 71250 or 71260) may be approved every 1 year</li> </ul>
<ul style="list-style-type: none"> <li>➤ Any of the following:                             <ul style="list-style-type: none"> <li>◆ New pulmonary symptoms</li> <li>◆ Worsening pulmonary function testing</li> </ul> </li> </ul>	<ul style="list-style-type: none"> <li>➤ CT Chest without contrast (CPT® 71250)</li> </ul>
<ul style="list-style-type: none"> <li>➤ Known SEGA tumors</li> </ul>	<ul style="list-style-type: none"> <li>➤ See: <b><u>Intracranial Low Grade Gliomas (LGG) (PEDONC-4.2)</u></b></li> </ul>
<ul style="list-style-type: none"> <li>➤ Known renal cell carcinoma</li> </ul>	<ul style="list-style-type: none"> <li>➤ See: <b><u>Pediatric Renal Cell Carcinoma (RCC) (PEDONC-7.4)</u></b></li> </ul>

**Background and Supporting Information**

- Inherited in an autosomal dominant manner (50% risk to offspring), affecting ~1 in 6000 individuals, it is associated with benign tumors, hypopigmented skin macules (ash leaf spots), developmental delay, and epilepsy.
- Malignancies associated with this syndrome include:
  - ◆ Subependymal giant cell astrocytomas (SEGA tumors)
    - Historically, early surgery was important to reduce morbidity related to these tumors
    - More recently, everolimus has been successfully used to treat these tumors without surgery, and early detection remains an important feature for success
  - ◆ Renal cell carcinoma
  - ◆ Cardiac rhabdomyosarcoma
  - ◆ Pulmonary lymphangioleiomyomatosis

- Recommended cancer screening includes:
  - ◆ Ophthalmologic and dermatologic evaluation annually

### **Von Hippel-Lindau Syndrome (VHL) (PEDONC-2.10)**

**The following imaging studies should be considered appropriate in individuals with VHL:**

Indication	Imaging Study
➤ All individuals, beginning at age 11 years	➤ MRI Brain without and with contrast (CPT® 70553) and MRI Spine without and with contrast (Cervical-CPT® 72156), Thoracic-CPT® 72157, and Lumbar-CPT® 72158) every 2 years
➤ Individuals with frequent ear infections, prior to age 8	➤ One-time MRI Brain without and with contrast (CPT® 70553)
➤ All individuals, beginning at age 5 years	➤ Annual Abdominal US (CPT® 76700)
➤ All individuals, beginning at age 15 years	➤ MRI Abdomen without and with contrast (CPT® 74183) every 2 years
➤ <u>ONE of the following:</u> <ul style="list-style-type: none"> <li>◆ Elevated catecholamines</li> <li>◆ Inconclusive adrenal mass on MRI</li> </ul>	➤ Octreotide study (CPT® 78800, CPT® 78801, CPT® 78802, CPT® 78803, or CPT® 78804) or Adrenal Nuclear imaging (CPT® 78075)
➤ Individuals with known hemangioblastoma anywhere in the body (based on imaging) that has not been resected	➤ <u>Both of the following, every 1 year:</u> <ul style="list-style-type: none"> <li>◆ MRI Brain without and with contrast (CPT® 70553)</li> <li>◆ MRI Spine without and with contrast (Cervical-CPT® 72156), Thoracic-CPT® 72157, and Lumbar-CPT® 72158)</li> </ul>
➤ Known hemangioblastoma that has not been resected and new or worsening symptoms	➤ MRI Brain without and with contrast (CPT® 70553) ➤ MRI Spine without and with contrast (Cervical-CPT® 72156), Thoracic-CPT® 72157, and Lumbar-CPT® 72158)
➤ Known (based on imaging) CNS hemangioblastoma	➤ See: <b><u>Intracranial Low Grade Gliomas (LGG) (PEDONC-4.2)</u></b>
➤ Known renal cell carcinoma	➤ See: <b><u>Pediatric Renal Cell Carcinoma (RCC) (PEDONC-7.4)</u></b>
➤ Known pheochromocytoma or other neuroendocrine tumor	➤ See: <b><u>Neuroendocrine Cancers And Adrenal Tumors (ONC-15)</u></b> in the Oncology Imaging Guidelines

#### ***Background and Supporting Information***

- Inherited in an autosomal dominant manner (50% risk to offspring), it is associated with CNS hemangioblastomas, retinal angiomas, endolymphatic sac tumors (ELST), gastrointestinal stromal tumor (GIST), renal cell carcinoma (RCC), and pheochromocytomas and other neuroendocrine tumors (NETs). Pediatric individuals are at risk of developing hemangioblastomas and pheochromocytomas that can remain clinically occult until symptoms become severe. Historically, substantial mortality

was attributable to RCC, pancreatic NET, and CNS hemangioblastoma.

- Recommended cancer screening includes:
  - ◆ Annual ophthalmologic evaluation beginning at birth
  - ◆ Annual measurement of catecholamines beginning at age 2
  - ◆ Audiology assessment every 2 years beginning at age 5

### **Rhabdoid Tumor Predisposition Syndrome (PEDONC-2.11)**

**The following imaging studies should be considered appropriate in individuals with Rhabdoid Tumor Predisposition Syndrome:**

Indication	Imaging Study
➤ All individuals, at diagnosis, as early as birth if requested	➤ Whole-body MRI (WBMRI) (CPT® 76498)
➤ All individuals, from birth to 6 months of age	➤ <u>ALL of the following, monthly:</u> <ul style="list-style-type: none"> <li>◆ US Head (CPT® 76506)</li> <li>◆ US Abdomen (CPT® 76700)</li> <li>◆ US Pelvis (CPT® 76856)</li> <li>◆ US Neck (CPT® 76536)</li> <li>◆ MRI with and without contrast of areas of concern found on baseline WBMRI</li> </ul>
➤ All individuals, from age 7 months to 5 years	➤ <u>ALL of the following, every 3 months:</u> <ul style="list-style-type: none"> <li>◆ US Abdomen (CPT® 76700)</li> <li>◆ US Pelvis (CPT® 76856)</li> <li>◆ US Neck (CPT® 76536)</li> <li>◆ MRI Brain (CPT® 70553)</li> <li>◆ MRI Spine (CPT® 72156, CPT® 72157, and CPT® 72158) without and with contrast</li> <li>◆ MRI with and without contrast of areas of concern found on baseline WBMRI</li> </ul>
➤ All individuals, after age 5 years	◆ Annual WBMRI (CPT® 76498)
➤ Clinical symptoms or WBMRI findings suggesting malignancy	➤ Targeted advanced imaging of the suspected disease site (CT with or without contrast, or MRI without and with contrast)
➤ Inconclusive findings on ultrasound	➤ MRI with and without contrast of the inconclusive US site <ul style="list-style-type: none"> <li>◆ MRI should be used in place of ultrasound for remainder of planned screening</li> </ul>

### ***Background and Supporting Information***

- Inherited in an autosomal dominant manner (50% risk to offspring), it is associated with malignant rhabdoid tumors of the kidney and extrarenal locations, and atypical teratoid/rhabdoid tumors (ATRT) of the CNS. It is caused by a germline mutation in *INI1* or *SMARCB1*, and is associated with a more variable prognosis than de novo rhabdoid tumors.

## **Familial Retinoblastoma Syndrome (PEDONC-2.12)**

- Regular physical and ophthalmologic evaluations under anesthesia (EUA) are the hallmark of surveillance strategies for these individuals, and asymptomatic screening imaging does not have a defined role at this time.

### **The following imaging studies should be considered appropriate in individuals with Familial Retinoblastoma Syndrome:**

Indication	Imaging Study
➤ Individuals with retinomas (pre-malignant retinal lesions)	➤ Annual MRI Orbits (CPT® 70543)
➤ Either of the following: <ul style="list-style-type: none"> <li>◆ Inconclusive EUA findings</li> <li>◆ New symptoms</li> </ul>	➤ US Orbits (CPT® 76512, 76510, or 76511) or MRI Orbits (CPT® 70543) <ul style="list-style-type: none"> <li>◆ These studies should be used if at all possible in lieu of CT or nuclear imaging to avoid radiation exposure</li> </ul>

### ***Background and Supporting Information***

- This syndrome is inherited in an autosomal dominant manner (50% risk to offspring). As the name suggests, it is associated with retinoblastoma, as well as osteosarcoma, pediatric melanoma, and a significantly increased risk for radiation-related malignancies.

## **Hereditary Paraganglioma-Pheochromocytoma (HPP) Syndromes (PEDONC-2.13)**

### **The following imaging studies should be considered appropriate in individuals with HPP Syndromes:**

Indication	Imaging Study
➤ All individuals with SDHx mutations, beginning at age 6	<ul style="list-style-type: none"> <li>➤ Every 2 years, ONE of the following sets of imaging:                             <ul style="list-style-type: none"> <li>◆ Whole-body MRI (CPT® 76498)                                     <ul style="list-style-type: none"> <li>■ CPT® 76498 is the only approvable code for whole-body MRI at this time</li> </ul> </li> <li>OR</li> <li>◆ MRI Neck (CPT® 70543), Chest (CPT® 71552), Abdomen (CPT® 74183), Pelvis (CPT® 72197) without and with contrast OR                                     <ul style="list-style-type: none"> <li>■ If MRI cannot be performed: CT Neck (CPT® 70491), Chest (CPT® 71260), and Abdomen/Pelvis (CPT® 74177) with contrast</li> </ul> </li> </ul> </li> </ul>
➤ Known pheochromocytoma or other neuroendocrine tumors	➤ See: <b><u>Neuroendocrine Cancers and Adrenal Tumors (ONC-15)</u></b> in the Oncology Imaging Guidelines

### Background and Supporting Information

- Caused by mutations in *SDHx* genes, this syndrome is inherited in an autosomal dominant manner (50% risk to offspring), and is associated with pheochromocytomas and paragangliomas.
- Individuals with multiple endocrine neoplasias should not use this guideline and should be imaged according to **Multiple Endocrine Neoplasias (MEN) (PEDONC-2.8)**.
- MRI is preferred to CT to minimize radiation exposure given these individuals' lifelong need for screening
- All individuals with HPP receive annual measurement of catecholamines

### **Costello Syndrome (PEDONC-2.14)**

**The following imaging studies should be considered appropriate in individuals with Costello Syndrome:**

Indication	Imaging Study
➤ Following confirmation of gene mutation	<ul style="list-style-type: none"> <li>➤ <u>ANY or ALL</u> of the following:                             <ul style="list-style-type: none"> <li>◆ Echocardiogram                                     <ul style="list-style-type: none"> <li>■ CPT® 93306 or</li> <li>■ CPT® 93308 with 93321 and 93325</li> </ul> </li> <li>◆ MRI Brain (CPT® 70553) without and with contrast</li> <li>◆ MRI Cervical (CPT® 72156) and Thoracic Spine (CPT® 72157) without and with contrast</li> </ul> </li> </ul>
➤ All individuals, from birth to 10 <sup>th</sup> birthday	<ul style="list-style-type: none"> <li>➤ <u>Every 3 months:</u> <ul style="list-style-type: none"> <li>◆ US Abdomen (CPT® 76700) and Pelvis (CPT® 76856)</li> </ul> </li> </ul>
➤ Known cardiac disease	➤ See: <b><u>Initial Transthoracic Echocardiography (TTE) Indications (PEDCD-8.2)</u></b> and <b><u>Repeat Transthoracic Echocardiography Indications (PEDCD-8.3)</u></b> in the Pediatric Cardiology Guidelines
➤ Known rhabdomyosarcoma	➤ See: <b><u>Rhabdomyosarcoma (RMS) (PEDONC-8.2)</u></b>
➤ Known neuroblastoma	➤ See: <b><u>Neuroblastoma (PEDONC-6)</u></b>

### Background and Supporting Information

- Caused by mutations in *HRAS* genes, this syndrome is inherited in an autosomal dominant manner (50% risk to offspring), and is associated with rhabdomyosarcoma and neuroblastoma in early childhood, and transitional cell cancer of the bladder in older children and adults.

## **Constitutional Mismatch Repair Deficiency (CMMRD or Turcot Syndrome) (PEDONC-2.15)**

**The following imaging studies should be considered appropriate in individuals with CMMRD/Turcot Syndrome:**

Indication	Imaging Study
<ul style="list-style-type: none"> <li>➤ All individuals, after CMMRD diagnosis is confirmed by genetic mutation</li> </ul>	<ul style="list-style-type: none"> <li>➤ MRI Brain without and with contrast (CPT® 70553) every 6 months</li> </ul>
<ul style="list-style-type: none"> <li>➤ All individuals, beginning at age 4 years</li> </ul>	<ul style="list-style-type: none"> <li>➤ Annual esophagogastroduodenoscopy and colonoscopy</li> </ul>
<ul style="list-style-type: none"> <li>➤ All individuals, beginning at age 6 years</li> </ul>	<ul style="list-style-type: none"> <li>➤ Annual whole-body MRI (CPT® 76498)                             <ul style="list-style-type: none"> <li>◆ 76498 is the only approvable code for whole-body MRI at this time</li> </ul> </li> </ul>

### ***Background and Supporting Information***

- A highly penetrant and aggressive cancer predisposing syndrome resulting from autosomal recessive inheritance of biallelic mutations in mismatch repair genes, CMMRD syndrome leads to substantial risk for several commonly fatal childhood malignancies - high-grade CNS tumors (glioma, PNET, medulloblastoma) and hematologic malignancies (non-Hodgkin lymphoma, acute lymphoblastic leukemia). Individuals with CMMRD are also at increased risk for gastrointestinal tumors.

## **Hereditary Leiomyomatosis and Renal Cell Cancer (HLRCC) (PEDONC-2.16)**

**The following imaging studies should be considered appropriate in individuals with HLRCC:**

Indication	Imaging Study
<ul style="list-style-type: none"> <li>➤ Beginning at age 8 years, individuals with at least ONE of the following:                             <ul style="list-style-type: none"> <li>◆ Documented fumarate hydratase (FH) gene mutation/variant consistent with HLRCC</li> <li>◆ Histologically confirmed multiple cutaneous piloleiomyomas</li> <li>◆ At least TWO of the following manifestations:                                     <ul style="list-style-type: none"> <li>■ Surgical treatment for symptomatic uterine leiomyomas before age 40</li> <li>■ Type 2 papillary renal cell carcinoma or collecting duct renal carcinoma before age 40</li> <li>■ A first-degree family member with either of the two above criteria</li> </ul> </li> </ul> </li> </ul>	<ul style="list-style-type: none"> <li>➤ MRI Abdomen with and without contrast (CPT® 74183), annually</li> </ul>

### ***Background and Supporting Information***

- Hereditary leiomyomatosis and renal cell cancer (HLRCC) is a disorder in which affected individuals tend to develop benign tumors containing smooth muscle tissue (leiomyomas) in the skin and, in females, the uterus. Approximately 20 percent of people with HLRCC develop renal cell cancer. People with HLRCC are commonly diagnosed with kidney cancer in their forties but cases have been reported in individuals as young as 11.
- In 2019, Forde et al published the first large, prospective study of screening for HLRCC and showed that most symptomatic individuals present with stage 3 or 4 RCC with a high risk of death, and one life is saved for every 5 individuals on an MRI screening protocol.

## **Other Renal Cell Cancer Predisposition Syndromes (PEDONC-2.17)**

### **Birt-Hogg-Dube Syndrome (BHDS)**

**The following imaging studies should be considered appropriate in individuals with BHDS:**

<b>Indication</b>	<b>Imaging Study</b>
➤ All individuals, beginning at age 20 years	➤ Abdominal MRI with and without contrast (CPT® 74183) every 3 years

### ***Background and Supporting Information***

- Birt-Hogg-Dube Syndrome (BHDS) is an autosomal dominant disorder with a heterozygous pathogenic variant in FLCN gene.
- These individuals have, or may have:
  - ◆ Cutaneous manifestations (fibrofolliculomas, acrochordons, angiofibromas, oral papules, cutaneous collagenomas, and epidermal cysts)
  - ◆ Pulmonary cysts/history of pneumothorax
  - ◆ A seven-fold increase in renal tumors
    - The most common renal tumors are oncocytoma, chromophobe, and a hybrid of these two.
    - Renal tumors may be multifocal and bilateral.
    - Median age of renal tumor diagnosis is 48 years.
- Recommended cancer screening includes:
  - ◆ Screening colonoscopy starting at age 40
    - Earlier colonoscopy may be considered for those with a family history of colorectal cancer earlier than age 40.

## BAP1 Tumor Predisposition Syndrome

### **The following imaging studies should be considered appropriate in individuals with BAP1:**

Indication	Imaging Study
➤ All individuals, beginning at age 30 years	➤ Abdominal MRI with and without contrast (CPT® 74183) every 2 years

#### ***Background and Supporting Information***

- BAP1 tumor predisposition syndrome (TPDS) is an autosomal dominant condition with a predisposition to melanoma (ocular and cutaneous), mesothelioma, clear cell renal cancer, and chromophobe renal cancer.

## **Hereditary Papillary Renal Carcinoma (HPRC)**

### **The following imaging studies should be considered appropriate in individuals with HPRC:**

Indication	Imaging Study
➤ All individuals, beginning at age 30 years	➤ Abdominal MRI with and without contrast (CPT® 74183) every 2 years

#### ***Background and Supporting Information***

- Hereditary papillary renal carcinoma (HPRC) is an autosomal dominant condition involving the MET gene and predisposes individuals to multifocal, bilateral renal tumors.

## **Other Renal Predisposition Syndromes**

### **The following imaging studies should be considered appropriate in individuals with other renal predisposition syndromes:**

Indication	Imaging Study
------------	---------------



<ul style="list-style-type: none"> <li>➤ Individuals with any of the following genetic variants or syndromes:             <ul style="list-style-type: none"> <li>◆ <i>REST, TRIM28, FBXW7, NYNRIN, KDM3B, XPO5, CHECK2, PALB2, CTNNB1, DROSHA, WT1 and 2, WTX, DGCR8, SIC1 and 2, BCORL1, MLLT1, MYCN</i></li> <li>◆ Frasier Syndrome</li> <li>◆ Trisomy 18</li> <li>◆ Perlman Syndrome</li> <li>◆ Bohring-Opitz Syndrome (ASXL1)</li> <li>◆ MULIBREY and Nanism Syndrome</li> <li>◆ Congenital anomalies associated with Wilms Tumor                 <ul style="list-style-type: none"> <li>■ Horseshoe kidney</li> <li>■ Renal ectopia, hypoplasia or renal/ureteral duplication</li> <li>■ Congenital mesoblastic nephroma</li> </ul> </li> </ul> </li> </ul>	<ul style="list-style-type: none"> <li>➤ Every 3 months, from birth to the 8<sup>th</sup> birthday:             <ul style="list-style-type: none"> <li>◆ Abdominal US (CPT® 76700)</li> </ul> </li> </ul>
--	---

**Background and Supporting Information**

- The list of syndromes and congenital anomalies associated with Wilms Tumor specifically is ever growing. The following genetic variants and syndromes, not otherwise listed in **PEDONC-2** for more specific imaging, may have imaging as shown below.

**Infantile Myofibromatosis (PEDONC-2.18)**

**The following imaging studies should be considered appropriate in individuals with Infantile Myofibromatosis:**

Indication	Imaging Study
<ul style="list-style-type: none"> <li>➤ Assess for the presence of multifocal disease in children under two years of age</li> </ul>	<ul style="list-style-type: none"> <li>➤ WBMRI (CPT® 76498) once within 6 months of diagnosis</li> </ul>
<ul style="list-style-type: none"> <li>➤ Pre-operative planning or</li> <li>➤ Signs or symptoms suggesting progression that may require treatment with surgery or chemotherapy</li> </ul>	<ul style="list-style-type: none"> <li>➤ Imaging of cutaneous/muscular sites with MRI with and without contrast of symptomatic sites or sites requiring treatment.</li> </ul>
<ul style="list-style-type: none"> <li>➤ Unresected, known visceral sites of disease</li> </ul>	<ul style="list-style-type: none"> <li>➤ MRI with and without contrast of unresected visceral involved sites, every 6 months until the age of two years</li> </ul>
<ul style="list-style-type: none"> <li>➤ Post-operative evaluation and both of the following:             <ul style="list-style-type: none"> <li>◆ Adequacy of resection is unclear and</li> <li>◆ Re-excision is being considered</li> </ul> </li> </ul>	<ul style="list-style-type: none"> <li>➤ One-time MRI with and without contrast</li> </ul>

<ul style="list-style-type: none"> <li>➤ Surveillance for emergence of visceral disease</li> </ul>	<ul style="list-style-type: none"> <li>➤ <u>Every 6 months, until the age of two years:</u> <ul style="list-style-type: none"> <li>◆ CT Chest with contrast (CPT® 71260) or without contrast (CPT® 71250)</li> <li>◆ CT Abdomen and Pelvis (CPT® 74177)</li> </ul> </li> <li>➤ CT should not duplicate simultaneous MRI imaging of involved sites</li> </ul>
<ul style="list-style-type: none"> <li>➤ Individuals requiring chemotherapy</li> </ul>	<ul style="list-style-type: none"> <li>➤ See: <b><u>PEDONC-8.3</u></b></li> </ul>

### **Background and Supporting Information**

- Infantile myofibromatosis is a benign condition characterized by soft tissue tumors, 90% of which present in the first 2 years of life. 75% of cases present as solitary lesions affecting the skin and/or muscles of the head, neck and trunk. Other patterns of inheritance include congenital multicentric disease limited to skin and muscle, congenital multicentric with a single visceral site, and congenital with multiple visceral site involvement.
- The condition is most commonly sporadic, though familial cases associated with *PDGFRB* and *NOTCH3* have been described
- The majority of cases with skin or muscle only involvement regress spontaneously.
- Visceral cases are lethal in the absence of therapy in 75% of cases due to organ compression, particularly with cardiopulmonary involvement.
- If vital structures are involved or significant symptoms occur, treatment is generally radical resection. Chemotherapy is sometimes utilized for progressive or multifocal life threatening lesions.
- Infants may present with a single lesion and develop further lesions in the first two years of life. This scenario, along with the inability of infants to readily express symptoms, impacts the imaging studies that may be approved.
- Routine surveillance of cutaneous/muscular sites is not supported as spontaneous regression is common.
- Surveillance beyond the age of two years is not supported.

### **References**

1. Plon SE, Malkin D. Childhood Cancer and Heredity. In: Pizzo PA, Poplack DG, eds. Principles and Practice of Pediatric Oncology. 7th ed. Philadelphia, PA: Wolters Kluwer; 2016:13-31.
2. Aplan PD, Shern JF, Khan J. Molecular and genetic basis of childhood cancer. In: Pizzo PA, Poplack DG, eds. Principles and Practice of Pediatric Oncology. 7th ed. Philadelphia, PA: Wolters Kluwer; 2016:32-62.
3. Zellek K, Lindell RB, Schiffman JD. et al. Genetic predisposition to cancer. In: Orkin SH, Fisher DE, Ginsburg D, Look AT, Lux SE, Nathan DG, eds. Nathan and Oski's Hematology and Oncology of Infancy and Childhood. 8th ed. Philadelphia, PA: Elsevier Saunders; 2015:1270-1293.
4. Garber JE, Offit K. Hereditary cancer predisposition syndromes. J Clin Oncol. 2005;23(2):276-292. doi:10.1200/JCO.2005.10.042.
5. Holman JD, Dyer JA. Genodermatoses with malignant potential. Current Opin Pediatr. 2007;19(4):446-454. doi:10.1097/MOP.0b013e3282495939.
6. Foulkes WD. Inherited susceptibility to common cancers. N Engl J Med. 2008;359:2143-2153. doi:10.1056/NEJMra0802968.

7. Schiffman JD, Geller JI, Mundt E, et al. Update on pediatric cancer predisposition syndromes. *Pediatr Blood Cancer*. 2013;60(8):1247-1252. doi:10.1002/pbc.24555.
8. American Academy of Pediatrics. Ethical and policy issues in genetic testing and screening of children. *Pediatrics*. 2013;131(3):620-622. doi:10.1542/peds.2012-3680.
9. Monsalve J, Kapur J, Malkin D, Babyn PS. Imaging of cancer predisposition syndromes in children. *Radiographics*. 2011;31(1):263-280. doi:10.1148/rg.311105099.
10. D'Orazio JA. Inherited cancer syndromes in children and young adults. *J Pediatr Hematol Oncol*. 2010;32(3):195-228. doi:10.1097/MPH.0b013e3181ced34c.
11. Lu KH, Wodd ME, Daniels M, et al. American Society of Clinical Oncology Expert Statement: collection and use of a cancer family history for oncology providers. *J Clin Oncol*. 2014;32(8):833-841. doi:10.1200/JCO.2013.50.9257.
12. Farid M, Ngeow J. Sarcomas associated with genetic cancer predisposition syndromes: a review. *Oncologist*. 2016;21(8):1002-1013. doi:10.1634/theoncologist.2016-0079.
13. Tiwari R, Singh AK, Somwaru AS, et al. Radiologist's primer on imaging of common hereditary cancer syndromes. *RadioGraphics*. 2019;39:759-778. doi:10.1148/rg.2019180171.
14. Schneider K, Zelle K, Nichols KE, Garber J. Li-Fraumeni Syndrome. In: Adam MP, Ardinger HH, Pagon RA, et al., ed. *GeneReviews*® [Internet]. Seattle, WA: University of Washington, Seattle; 1993-2019. <https://www.ncbi.nlm.nih.gov/books/NBK1311/>.
15. Villani A, Tabori U, Schiffman J, et al. Biochemical and imaging surveillance in germline TP53 mutation carriers with Li-Fraumeni syndrome: a prospective observational study. *Lancet Oncol*. 2011;12(6):559-567. doi:10.1016/S1470-2045(11)70119-X.
16. Villani A, Shore A, Wasserman JD, et al. Biochemical and imaging surveillance in germline TP53 mutation carriers with Li-Fraumeni syndrome: 11 year follow-up of a prospective observational study. *Lancet Oncol*. 2016;17(9):1295-1305. doi:10.1016/S1470-2045(16)30249-2.
17. Ballinger ML, Best A, Mai PL, et al. Baseline surveillance in Li-Fraumeni Syndrome using whole-body magnetic resonance imaging a meta analysis. *JAMA Oncol*. 2017;3(12):1634-1639. doi:10.1001/jamaoncol.2017.1968.
18. Ruijs MWG, Loo CE, van Buchem CAJM, et al. Surveillance of Dutch patients with Li-Fraumeni Syndrome: the life-guard study. *JAMA Oncol*. 2017;3(12):1733-1734. doi:10.1001/jamaoncol.2017.1346.
19. Mai PL, Khincha PP, Loud JT, et al. Prevalence of Cancer at Baseline screening in the National Cancer Institute Li-Fraumeni Syndrome Cohort. *JAMA Oncol*. 2017;3(12):1640-1645. doi:10.1001/jamaoncol.2017.1350.
20. Kratz CP, Achatz MI, Brugières L, et al. Cancer screening recommendations for individuals with Li-Fraumeni Syndrome. *Clin Cancer Res*. 2017;23(11):e38-e45. doi:10.1158/1078-0432.CCR-17-0408.
21. Greer MC, Voss SD, States LJ. Pediatric cancer predisposition imaging: focus on whole-body MRI. *Clin Cancer Res*. 2017;23(11):e6-e13. doi:10.1158/1078-0432.CCR-17-0515.
22. Asdahl PH, Ojha RP, Hasle H. Cancer screening in Li-Fraumeni Syndrome. *JAMA Oncol*. 2017;3(12):1645-1646. doi:10.1001/jamaoncol.2017.2459.
23. Eutsler EP, Khanna G. Whole-body magnetic resonance imaging in children: technique and clinical applications. *Pediatr Radiol*. 2016;46(6):858-872. doi: 10.1007/s00247-016-3586-y.
24. Gottumukkalla RV, Gee MS, Hampilos PJ, Greer MC. Current and emerging roles of whole-body MRI in evaluation of pediatric cancer patients. *RadioGraphics*. 2019;39:516-534. doi:10.1148/rg.2019180130.
25. Daly MB, Pilarski R, Berry MP, et al. National Comprehensive Cancer Network (NCCN) Guidelines Version 2.2022—March 9, 2022. Genetic/Familial High-Risk Assessment: Breast, Ovarian, and Pancreatic, available at: [https://www.nccn.org/professionals/physician\\_gls/pdf/genetics\\_bop.pdf](https://www.nccn.org/professionals/physician_gls/pdf/genetics_bop.pdf), Referenced with permission from the NCCN Clinical Practice Guidelines in Oncology (NCCN Guidelines™) for Genetic/Familial High-Risk Assessment: Breast, Ovarian, and Pancreatic V2.2022 3/9/2022 ©2022 National Comprehensive Cancer Network, Inc. All rights reserved. The NCCN Guidelines™ and illustrations herein may not be reproduced in any form for any purpose without the express written permission of the NCCN. To view the most recent and complete version of the NCCN Guidelines™, go online to [NCCN.org](http://NCCN.org).
26. Miller DT, Freedenberg D, Schorry E, et al. Health supervision for children with neurofibromatosis type 1. *Pediatrics*. 2019;143:e20190660. doi:10.1541/peds.2019-0660.
27. Sahin M. Neurocutaneous syndromes. In: Kliegman RM, Stanton BF, St. Geme JW, Schor NF, Behrman RE, eds. *Nelson Textbook of Pediatrics*. Philadelphia, PA: Elsevier Saunders; 2011:2046-2048.
28. Ullrich NJ. Neurocutaneous syndromes and brain tumors. *J Child Neurol*. 2016;31(12):1399-1411. doi:10.1177/0883073815604220.
29. Korf BR and Bebin EM. Neurocutaneous disorders in Children. *Pediatr Rev*. 2017; 38(3):119-127. doi:10.1542/pir.2015-0118.
30. Campian J, Gutmann DH. CNS tumors in neurofibromatosis. *J Clin Oncol*. 2017; 35(21):2378-2385. doi:10.1200/JCO.2016.71.7199.
31. Friedman JM. Neurofibromatosis 1. In: Pagon RA, Adam MP, Ardinger HH et al., eds. *GeneReviews*™ [Internet]. Seattle, WA: University of Washington, Seattle;1998-2017. Version April 21 2022 <https://www.ncbi.nlm.nih.gov/books/NBK1109/>.
32. Karajannis MA, Ferner RE. Neurofibromatosis-related tumors: emerging biology and therapies. *Curr Opin Pediatr*. 2015;27(1):26-33. doi:10.1097/MOP.000000000000169.

33. Meany H, Dombi E, Reynolds J, et al. 18-Fluorodeoxyglucose-Positron Emission Tomography (FDG-PET) evaluation of nodular lesions in patients with neurofibromatosis Type 1 and Plexiform Neurofibromas (PN) or Malignant Peripheral Nerve Sheath Tumors (MPNST). *Pediatr Blood Cancer*. 2013;60(1):59-64. doi:10.1002/pbc.24212.
34. Tsai LL, Druback L, Fahey F, et al. [18F]-Fluorodeoxyglucose positron emission tomography in children with neurofibromatosis type 1 and plexiform neurofibromas: correlation with malignant transformation. *J Neuro Oncol*. 2012;108(3):469-475. doi:10.1007/s11060-012-0840-5.
35. Corbemale P, Valeyrie-Allanore L, Giammarile F, et al. Utility of 18F-FDG PET with a semi-quantitative index in the detection of sarcomatous transformation in patients with neurofibromatosis Type 1. *PLoS ONE*. 2014;9(2):e85954. doi:10.1371/journal.pone.0085954.
36. Chirindel A, Chaudhry M, Blakeley JO, Wahl R. 18F-FDG PET/CT Qualitative and quantitative evaluation in neurofibromatosis Type 1 Patients for detection of malignant transformation: comparison of early to delayed imaging with and without liver activity normalization. *J Nucl Med*. 2015;56(3):379-385. doi:10.2967/jnumed.114.142372.
37. Prada CE, Hufnagel RB, Hummel TR, et al. The use of magnetic resonance imaging screening for optic pathway gliomas in children with neurofibromatosis Type 1. *J Pediatr*. 2015;167(4):851-856. doi:10.1016/j.jpeds.2015.07.001.
38. Blakeley JO, Evans DG, Adler J, et al. Consensus recommendations for current treatments and accelerating clinical trials for patients with neurofibromatosis Type 2. *Am J Med Genet A*. 2012;158A(1):24-41. doi:10.1002/ajmg.a.34359.
39. Evans DG. Neurofibromatosis 2. In: Pagon RA, Adam MP, Bird TD et al., eds. *GeneReviews™* [Internet]. Seattle, WA: University of Washington, Seattle; 2011. Version March 15, 2018. <https://www.ncbi.nlm.nih.gov/books/NBK1201/>.
40. Evans DG. Neurofibromatosis type 2 (NF2): a clinical and molecular review. *Orphanet J Rare Dis* 2009;4:16. doi:10.1186/1750-1172-4-16.
41. Ardern-Holmes S, Fisher G, North K. Neurofibromatosis Type 2: presentation, major complications, and management, with a focus on the pediatric age group. *J Child Neurol*. 2016;32(1):9-22. doi:10.1177/0883073816666736.
42. Shuman C, Beckwith JB, Weksberg R. Beckwith-Wiedemann syndrome. In: Pagon RA, Adam MP, Bird TD et al., eds. *GeneReviews™* [Internet]. Seattle, WA: University of Washington, Seattle; 2016. Version August 11, 2016. <https://www.ncbi.nlm.nih.gov/pubmed/20301568>.
43. Choyke PL, Siegel MJ, Craft AW, Green DM, DeBaun MR. Screening for Wilms Tumor in children with Beckwith-Wiedemann syndrome or idiopathic hemihypertrophy. *Med Pediatr Oncol*. 1999;32(3):196-200. doi:10.1002/(SICI)1096-911X(199903)32:3<196::AID-MPO6>3.0.CO;2-9.
44. Mussa A, Molinatto C, Baldassare G, et al. Cancer risk in Beckwith-Wiedemann syndrome: A systematic review and meta-analysis outlining a novel (epi)genotype specific histotype targeted screening protocol. *J Pediatr*. 2016 September;176:142-149. doi:10.1016/j.jpeds.2016.05.038.
45. MacFarland SP, Mostoufi-Moab S, Zellely K, et al. Management of adrenal masses in patients with Beckwith-Wiedemann syndrome. *Pediatr Blood Cancer*. 2017;64(8):e26432. doi:10.1002/pbc.26432.
46. Dome JS and Huff V. Wilms tumor predisposition. In: Pagon RA, Adam MP, Bird TD et al., eds. *GeneReviews™* [Internet]. Seattle, WA: University of Washington, Seattle; 2016. <https://www.ncbi.nlm.nih.gov/pubmed/20301471> March 24, 2022.
47. Fischbach BV, Trout KL, Lewis J, Luis CA, Sika M. WAGR Syndrome: A Clinical Review of 54 Cases. *Pediatrics*. 2005;116(4):984-988. doi:10.1542/peds.2004-0467.
47. Provenzale D, Gupta S, Ahnen DJ, et al. National Comprehensive Cancer Network (NCCN) Guidelines Version 1.2022—June 8, 2022, Genetic/Familial High-Risk Assessment: Colorectal, available at: [https://www.nccn.org/professionals/physician\\_gls/pdf/genetics\\_colon.pdf](https://www.nccn.org/professionals/physician_gls/pdf/genetics_colon.pdf), Referenced with permission from the NCCN Clinical Practice Guidelines in Oncology (NCCN Guidelines™) for Genetic/Familial High-Risk Assessment: Colorectal V1.2022 06/08/2022. ©2022 National Comprehensive Cancer Network, Inc. All rights reserved. The NCCN Guidelines™ and illustrations herein may not be reproduced in any form for any purpose without the express written permission of the NCCN. To view the most recent and complete version of the NCCN Guidelines™, go online to NCCN.org
48. Kennedy RD, Potter DD, Moir CR, Mounif E. The natural history of familial adenomatous polyposis syndrome: A 24 year review of a single center experience in screening, diagnosis, and outcomes, *J Pediatr Surg* 2014;49(1):82-86. doi:10.1016/j.jpedsurg.2013.09.033.
49. Jasperson KW, Patel SG, Ahnen DJ. APC-Associated Polyposis Conditions. In: Pagon RA, Adam MP, Bird TD, et al., ed. *GeneReviews™* [Internet]. Seattle, WA: University of Washington, Seattle; 2017. Version May 12, 2022. <https://www.ncbi.nlm.nih.gov/books/NBK1345/>.
50. Stoffel EM, Mangu PB, Gruber SB, et al. Hereditary colorectal cancer syndromes: American Society of Clinical Oncology clinical practice guideline endorsement of the familial risk-colorectal cancer: European Society for Medical Oncology clinical practice guidelines. *J Clin Oncol*. 2015;33(2):209-217. doi:10.1200/JCO.2014.58.1322.
51. Giusti F, Marini F, Brandi ML. Multiple endocrine neoplasia Type 1. In: Pagon RA, Adam MP, Ardinger HH et al,

- ed. GeneReviews™ [Internet]. Seattle, WA: University of Washington, Seattle; 1993-2019. Version December 14, 2017. <https://www.ncbi.nlm.nih.gov/books/NBK1538/>.
52. Thakker RV, Newey PJ, Walls GV, et al. Clinical Practice guidelines for multiple endocrine neoplasia type 1 (MEN1). *J Clin Endocrinol Metab*. 2012;97(9):2990-3011. doi:10.1210/jc.2012-1230
53. Giri D, McKay V, Weber A, Blair JC. Multiple endocrine neoplasia syndromes 1 and 2: manifestations and management in childhood and adolescence. *Arch Dis Child*. 2015;100(10):994-999. doi:10.1136/archdischild-2014-307028.
54. Eng C. Multiple endocrine neoplasia Type 2. In: Pagon RA, Adam MP, Ardinger HH et al, eds. GeneReviews™ [Internet]. Seattle, WA: University of Washington, Seattle; 1999-2019. Version August 15, 2019. <https://www.ncbi.nlm.nih.gov/books/NBK1257/>.
55. Northrup H, Koenig MK, Pearson DA, Au KS. Tuberous Sclerosis Complex. In: Pagon RA, Adam MP, Ardinger HH et al, eds. GeneReviews™ [Internet]. Seattle, WA: University of Washington, Seattle; Version September 3, 2015. <https://www.ncbi.nlm.nih.gov/pubmed/20301399>.
56. Northrup H, Koenig MK, Pearson DA, Au KS. Tuberous sclerosis complex. In: Pagon RA, Adam MP, Ardinger HH et al, eds. GeneReviews™ [Internet]. Seattle, WA: University of Washington, Seattle; 1993-2019. Version Dec 9, 2021 <https://www.ncbi.nlm.nih.gov/books/NBK1220/>.
57. Krueger DA, Care MM, Agricola K, Tudor C, Mays M, Franz DN. Everolimus long-term safety and efficacy in subependymal giant cell astrocytoma. *Neurology*. 2013;80(6):574-580. doi:10.1212/WNL.0b013e3182815428.
58. Wheless JW, Klimo P. Subependymal giant cell astrocytomas in patients with tuberous sclerosis complex: considerations for surgical or pharmacotherapeutic intervention. *J Child Neurol*. 2014;29(11):1562-1571. doi:10.1177/0883073813501870.
59. van Leeuwen RS, Ahmad S, Links TP, Giles RH. Von Hippel-Lindau Syndrome. In: Pagon RA, Adam MP, Ardinger HH et al, eds. GeneReviews™ [Internet]. Seattle, WA: University of Washington, Seattle; 1993-2019. Version September 6, 2018. <https://www.ncbi.nlm.nih.gov/books/NBK1463/>.
60. Nielsen SM, Rhodes L, Blanco I, et al. Von Hippel-Lindau Disease: genetics and role of genetic counseling in a Multiple Neoplasia Syndrome. *J Clin Oncol*. 2016;34(18):2172-2181.
61. Rednam SP, Erez A, Druker H, et al. Von Hippel-Lindau and hereditary pheochromocytoma/paraganglioma syndromes: clinical features, genetics, and surveillance recommendations in childhood. *Clin Cancer Res*. 2017;23:e68-e75. doi: 10.1158/1078-0432.CCR-17-0547.
62. Kordes U, Bartelheim K, Modena P, et al. Favorable outcome of patients affected by rhabdoid tumors due to Rhabdoid Tumor Predisposition Syndrome (RTPS). *Pediatr Blood Cancer*. 2014;61(5):919-921. doi:10.1002/pbc.24793.
63. Sredni ST, Tomita T. Rhabdoid Tumor Predisposition Syndrome. *Pediatr Dev Pathol*. 2015;18(1):49-58. doi:10.2350/14-07-1531-MISC.1.
64. Nemes K, Bens S, Bourdeaut F, et al. Rhabdoid tumor predisposition syndrome. In: Pagon RA, Adam MP, Ardinger HH et al, eds. GeneReviews™ [Internet]. Seattle, WA: University of Washington, Seattle; 1993-2019. Version May 12, 2022. <https://www.ncbi.nlm.nih.gov/books/NBK469816/>.
65. Lohmann DR, Gallie BL. Retinoblastoma. In: Pagon RA, Adam MP, Ardinger HH et al, eds. GeneReviews™ [Internet]. Seattle, WA: University of Washington, Seattle; 1993-2019. Version November 21, 2018. <https://www.ncbi.nlm.nih.gov/books/NBK1452/>.
66. Else T, Greenberg S, Fishbein L. Hereditary Paraganglioma-Pheochromocytoma Syndromes. 2008 May 21 [updated 2018 Oct 4]. In: Adam MP, Everman DB, Mirzaa GM, Pagon RA, Wallace SE, Bean LJH, Gripp KW, Amemiya A, editors. GeneReviews® [Internet]. Seattle (WA): University of Washington, Seattle; 1993–2022. PMID: 20301715. Version April 1, 2021. <https://www.ncbi.nlm.nih.gov/pubmed/20301715>.
67. Gripp KW, Lin AE. Costello Syndrome. In: Pagon RA, Adam MP, Ardinger HH et al, eds. GeneReviews™ [Internet]. Seattle, WA: University of Washington, Seattle; 1999-2019. Version January 12, 2012. <https://www.ncbi.nlm.nih.gov/books/NBK1507/>.
68. Tabori U, Hansford JR, Achatz MI, et al. Clinical management and tumor surveillance recommendations of inherited mismatch repair deficiency in childhood. *Clin Cancer Res*. 2017;23:e32-e37. doi: 10.1158/1078-0432.CCR-17-0574.
69. Krueger DA, Northrup H. Tuberous sclerosis complex surveillance and management: recommendations of the 2012 International Tuberous Sclerosis Complex Consensus Conference. *Pediatr Neurol*. 2013;49(4):255–265. doi:10.1016/j.pediatrneurol.2013.08.002.
70. Campen CJ, Gutmann DH. Optic pathway gliomas in neurofibromatosis type 1. *J Child Neurol*. 2018;33(1):73–81. doi:10.1177/0883073817739509.
71. Rosser T. Neurocutaneous disorders. *CONTINUUM*. 2018;24(1, Child Neurology):96-129. doi:10.1212/CON000000000000562.
72. Motzer RJ, Jonasch E, Agarwal N, et al. National Comprehensive Cancer Network (NCCN) Guidelines Version 2.2023 – August 3, 2022. Kidney Cancer, available at: [https://www.nccn.org/professionals/physician\\_gls/pdf/kidney.pdf](https://www.nccn.org/professionals/physician_gls/pdf/kidney.pdf), Referenced with permission from the NCCN Clinical Practice Guidelines in Oncology (NCCN Guidelines™) for Kidney Cancer V2.2023 – 8/3/2022. ©2022 National Comprehensive Cancer Network, Inc. All rights reserved. The NCCN Guidelines™ and illustrations herein may not be reproduced in any form for any purpose without the express written permission of the

- NCCN. To view the most recent and complete version of the NCCN Guidelines™, go online to NCCN.org
73. Tuberous Sclerosis Alliance. Diagnosis, surveillance, and management of individuals with tuberous sclerosis complex. Silver Spring, MD. Tuberous Sclerosis Alliance; 2014. <https://www.tsalliance.org/healthcare-professionals/diagnosis/>
  74. Lam H, Siroky BJ, Henske EP. Renal disease in tuberous sclerosis complex: pathogenesis and therapy. *Nat Rev Nephrol.* 2018;14(11):704-706. doi:10.1038/s41581-018-0059-6.
  75. Sattler EC, Ortud KS. Birt-Hogg-Dube Syndrome. In: Pagon RA, Adam MP, Ardinger HH et al, eds. GeneReviews™ [Internet]. Seattle, WA: University of Washington, Seattle;1993-2020. Version January 30, 2020. <https://www.ncbi.nlm.nih.gov/books/NBK1522/>.
  76. Pilarski R, Rai K, Cebulla C, et al. BAP1 Tumor Predisposition Syndrome. In: Pagon RA, Adam MP, Ardinger HH et al, eds. GeneReviews™ [Internet]. Seattle, WA: University of Washington, Seattle;1993-2020. Version January 30, 2020. <https://www.ncbi.nlm.nih.gov/books/NBK390611/>.
  77. Gläsker S, Vergauwen E, Koch CA, Kutikov A, Vortmeyer AO. Von Hippel-Lindau disease: current challenges and future prospects. *Onco Targets Ther.* 2020;13;5669-5690. doi:10.2147/OTT.S190753.
  78. VHL Alliance. VHLA suggested active surveillance guidelines. Boston, MA. VHL Alliance; 2020. <https://www.vhl.org/wp-content/uploads/2020/07/Active-Surveillance-Guidelines-2020-2.pdf>
  79. Balis F, Green DM, Anderson C, et. al. National Comprehensive Cancer Network (NCCN) Guidelines Version 1.2022 – April 12, 2022. Wilms Tumor (Nephroblastoma), available at: [https://www.nccn.org/professionals/physician\\_gls/pdf/wilms\\_tumor.pdf](https://www.nccn.org/professionals/physician_gls/pdf/wilms_tumor.pdf), Referenced with permission from the NCCN Clinical Practice Guidelines in Oncology (NCCN Guidelines™) for Wilms Tumor (Nephroblastoma) V1.2022 – 4/12/2022. ©2022 National Comprehensive Cancer Network, Inc. All rights reserved. The NCCN Guidelines™ and illustrations herein may not be reproduced in any form for any purpose without the express written permission of the NCCN. To view the most recent and complete version of the NCCN Guidelines™, go online to NCCN.org
  80. Todd K, Kim HK, Szabo S, et. al. Solitary myofibroma preceding the development of multicentric myofibromatosis: A report of two cases with surveillance recommendations. *Pediatr Blood Cancer.* 2020;67(10):e28266. doi:10.1002/pbc.28266.
  81. Orbach, D, Bodemer C. Infantile myofibromatosis. *Orphanet.* 2019. [https://www.orpha.net/consor/cgi-bin/OC\\_Exp.php?Lng=GB&Expert=2591](https://www.orpha.net/consor/cgi-bin/OC_Exp.php?Lng=GB&Expert=2591)
  82. National Cancer Institute. Infantile myofibromatosis. 2020. <https://www.cancer.gov/pediatric-adult-rare-tumor/rare-tumors/rare-soft-tissue-tumors/infantile-myofibromatosis>
  83. Tang ER, Khalatbari H, Parisi MT. Utility of 18F-FDG PET/CT in infantile myofibromatosis. *Clin Nucl Med.* 2019;44:676-679. doi:10.1097/RLU.0000000000002627.
  84. Evans DGR, Salvador H, Chang VY, Erez A, Voss SD, Schneider KW, Scott HS, Plon SE, Tabori U. Evans DGR, et al. Cancer and Central Nervous System Tumor Surveillance in Pediatric Neurofibromatosis 1. *Clin Cancer Res.* 2017;23(12):e46-e53. doi: 10.1158/1078-0432.CCR-17-0589.
  85. Gottumukkala RV, Gee MS, Hampilos PJ, Greer MC. Gottumukkala RV, et al. Current and emerging roles of whole-body MRI in evaluation of pediatric cancer patients. *Radiographics.* 2019;39(2):516-534. doi:10.1148/rg.2019180130.
  86. Al-Sarhani H, Gottumukkala RV, Grasparil ADS 2nd, Tung EL, Gee MS, Greer MC. Screening of cancer predisposition syndromes. *Pediatr Radiol.* 2021. doi:10.1007/s00247-021-05023-w.
  87. Grasparil AD 2nd, Gottumukkala RV, Greer MC, Gee MS. Whole-Body MRI surveillance of cancer predisposition syndromes: current best practice guidelines for use, performance, and interpretation. *AJR Am J Roentgenol.* 2020;215(4):1002-1011. doi:10.2214/AJR.19.22399.
  88. Yang J, Gurudu SR, Koptiuch C, et.al. American Society for Gastrointestinal Endoscopy guideline on the role of endoscopy in familial adenomatous polyposis syndromes. *Gastrointestinal Endoscopy.* 2020;91(5):963-82. doi:10.1016/j.gie.2020.01.028.
  89. PDQ® Cancer Genetics Editorial Board. PDQ Birt-Hogg-Dubé Syndrome. Bethesda, MD: National Cancer Institute. Updated 04/13/2022. Available at: <https://www.cancer.gov/types/kidney/hp/renal-cell-carcinoma-genetics/bhd-syndrome>.
  90. Frühwald MC, Nemes K, Boztug H, et al. Current recommendations for clinical surveillance and genetic testing in rhabdoid tumor predisposition: a report from the SIOPE Host Genome Working Group. *Fam Cancer.* 2021;20(4):305-316. doi:10.1007/s10689-021-00229-1. Epub 2021 Feb 3. PMID: 33532948; PMCID: PMC8484234.
  91. Wolters WPG, Dreijerink KMA, Giles RH, et al. Multidisciplinary integrated care pathway for von Hippel-Lindau disease. *Cancer.* 2022;128(15):2871-2879. doi:10.1002/cncr.34265. Epub 2022 May 17. PMID: 35579632.

<b>Pediatric Leukemias (PEDONC-3)</b>
<b>Pediatric Leukemia General Considerations (PEDONC-3.1)</b>
<b>Acute Lymphoblastic Leukemia (ALL) (PEDONC-3.2)</b>
<b>Acute Myeloid Leukemia (AML) (PEDONC-3.3)</b>

### Pediatric Leukemia General Considerations (PEDONC-3.1)

- MRI Brain without and with contrast (CPT® 70553) in individuals exhibiting CNS symptoms
  - ◆ Imaging due to CSF tumor burden has not been shown to improve the detection of CNS involvement compared with CSF alone
- See: **Hematopoietic Stem Cell Transplantation (ONC-29)** for imaging guidelines related to transplant

### *Background and Supporting Information*

- The overwhelming majority of leukemias occurring in children are acute. Chronic myelogenous leukemia (CML) is rare in children, and the occurrence of chronic lymphocytic leukemia (CLL) appears to have only been reported once in pediatric individuals to date
- Routine advanced imaging is not indicated in the evaluation and management of chronic myeloid leukemia in the absence of specific localizing clinical symptoms or clearance for hematopoietic stem cell transplantation

### **Acute Lymphoblastic Leukemia (ALL) (PEDONC-3.2)**

- Individuals with B-precursor or T-cell lymphoblastic lymphoma without bone marrow involvement are treated similarly to leukemia individuals of the same cell type and should be imaged according to this guideline section
- This section does not apply to individuals with mature B-cell histology (primarily Burkitt's in children). Please refer to **Pediatric Aggressive Mature B-Cell Non-Hodgkin Lymphomas (NHL) (PEDONC-5.3)** for guidelines for these individuals
- Scrotal Ultrasound CPT® 76870 and/or doppler ultrasound of the scrotum CPT® 93975 or 93976 may be approved for suspected testicular involvement.
- Chest x-ray should be performed to evaluate for mediastinal mass in suspected cases or upon initial diagnosis.
  - ◆ CT Chest with contrast (CPT® 71260) immediately to evaluate for airway compression and anesthesia safety prior to attempting histologic diagnosis if mediastinal widening is seen on chest x-ray
  - ◆ Individuals with known or strongly suspected T-cell histology or other suspected lymphoblastic lymphoma involvement EITHER of the following for initial staging purposes:
    - CT Neck (CPT® 70491), CT Chest (CPT® 71260) and CT Abdomen and Pelvis (CPT® 74177) with contrast **OR**
    - PET/CT (CPT® 78816)
    - Indications and coding for rare circumstances where PET/MRI may be approved are found in **PET Imaging in Pediatric Oncology (PEDONC-1.4)**
- MRI Brain without and with contrast (CPT® 70553) for individuals exhibiting CNS symptoms.
  - ◆ Imaging due to CSF tumor burden has not been shown to improve the detection of CNS involvement compared with CSF alone.



### **Additional imaging in lymphoblastic lymphoma/lymphomatous extramedullary disease:**

- CT to assess response to therapy **only** for individuals with known bulky nodal disease (usually with T-cell histology) at the end of induction (4 to 6 weeks). Individuals with residual masses can be evaluated with every new therapy phase (Consolidation, Interim maintenance, etc., generally every 8 to 12 weeks) until disease resolution is seen
- PET/CT (CPT® 78815) when residual mass  $\geq 8$  mm in diameter is present on recent CT imaging and immediate radiation or chemotherapy plan will be based on results.
  - ◆ Residual mass of any size with no PET-avidity is considered a complete response at the extranodal/lymphomatous site.
- Chest x-ray or Abdominal ultrasound (CPT® 76700) **only**, as indicated by site(s) of bulky disease present at diagnosis, for further surveillance, once CT imaging shows no evidence of disease.
- CT of all involved bulky nodal areas individuals with persistent residual masses performed as part of an end of therapy evaluation

### **Immunosuppression during ALL therapy:**

- CT or MRI requests for infectious disease concerns for individuals with ALL with:
  - ◆ Absolute neutrophil count (ANC)  $< 500$  **or**
  - ◆ Inconclusive findings on chest x-ray **or** ultrasound at any ANC during active treatment
- MRA/MRV of the head (CPT® 70544, 70545, or 70546)
  - ◆ To rule out bleeding associated with sinus venous thrombosis in individuals treated with asparaginase

### **Imaging during therapy for relapsed ALL:**

- Frequent CT or MRI imaging may be indicated to evaluate known or suspected new sites of invasive fungal or other aggressive infections
- Surveillance imaging of asymptomatic individuals to detect invasive fungal infection **only** when acute clinical decisions will be made based on the imaging

### **Imaging of known or suspected osteonecrosis in ALL:**

- MRI without contrast or without and with contrast of the affected joint(s) with symptoms suggesting osteonecrosis
  - ◆ CT without contrast can be approved when MRI is contraindicated or unavailable, or for diagnosis of suspected subchondral fracture
- MRI Bilateral Hips (CPT® 73721 or CPT® 73723 with modifier -50) once at 6 to 9 months after diagnosis for individuals age  $\geq 11$  years
- Repeat MRI without contrast of the affected joint(s) every 2 cycles of maintenance (every 6 months) if reintroduction of corticosteroids is being considered in individuals whose symptoms have resolved and are still receiving active treatment
- MRI without contrast of the affected joint(s) for preoperative planning for individuals

undergoing core decompression

- See: **Osteonecrosis In Long Term Cancer Survivors (PEDONC-19.4)** for information on osteonecrosis in ALL individuals who have completed therapy

### ***Background and Supporting Information***

- The majority of individuals with ALL have B-precursor ALL and routine advanced imaging is not necessary.
- Individuals with ALL are severely immunocompromised during the first 4 to 6 weeks of treatment (induction) and any conventional imaging request to evaluate for infectious complications during this time frame should be approved immediately
- Individuals with ALL who relapse are treated with very intensive chemotherapy regimens and most spend the majority of their chemotherapy treatment phase in the hospital
- Individuals may have therapy-induced hypogammaglobulinemia which requires supplemental intravenous immune globulin (IVIG) during maintenance therapy. Those receiving supplemental IVIG should be treated similarly to individuals with ANC <500 with regards to imaging for infectious disease
- Osteonecrosis (ON) in individuals with ALL is a relatively common complication of ALL and its treatment, primary corticosteroids. Approximately 3% of younger children and 12 to 15% of adolescents are affected by ON at some point during therapy. The peak incidence occurs approximately one year from the time of diagnosis
- Screening MRI of asymptomatic individuals age ≤10 years to detect osteonecrosis has not been shown to impact individual outcomes, and it is not standard to alter treatment based on imaging findings alone without symptoms
- If osteonecrosis is detected on initial MRI, corticosteroids are often withheld during maintenance chemotherapy (but continued in earlier phases of therapy).

### **Acute Myeloid Leukemia (AML) (PEDONC-3.3)**

- Frequent CT or MRI imaging may be indicated to evaluate known sites of invasive fungal infection
- Surveillance imaging of asymptomatic individuals to detect invasive fungal infection **only** when acute clinical decisions will be made based on the imaging

### ***Background and Supporting Information***

- The majority of AML individuals do not have any bulky disease and routine advanced imaging is not necessary
- Advanced imaging may be indicated for rare individuals with bulky tumor masses (commonly referred to as chloromas, leukemic sarcomas, or myeloid sarcomas) noted on physical examination or other imaging such as plain film or ultrasound
- AML individuals are treated with very intensive chemotherapy regimens and spend the majority of their chemotherapy treatment phase in the hospital

## References

1. Rabin KR, Gramatges MM, Margolin JF, et al. Acute Lymphoblastic Leukemia. In: Pizzo PA, Poplack DG, eds. Principles and Practice of Pediatric Oncology. 7th ed. Philadelphia, PA: Wolters Kluwer; 2016:463-497.
2. Arceci RJ, Meshinchi S. Acute Myeloid Leukemia and Myelodysplastic disorders. In: Pizzo PA, Poplack DG, eds. Principles and Practice of Pediatric Oncology. 7th ed. Philadelphia, PA: Wolters Kluwer; 2016:498-544.
3. Rau R, Loh ML. Myeloproliferative neoplasms of childhood. In: Pizzo PA, Poplack DG, eds. Principles and Practice of Pediatric Oncology. 7th ed. Philadelphia, PA: Wolters Kluwer; 2016:545-567.
4. Gutierrez A, Silverman LB. Acute Lymphoblastic Leukemia. In: Orkin SH, Fisher DE, Ginsburg D, Look AT, Lux SE, Nathan DG, eds. Nathan and Oski's Hematology and Oncology of Infancy and Childhood. 8th ed. Philadelphia, PA: Elsevier Saunders; 2015:1527-1554.
5. Berman JN, Look AT. Pediatric Myeloid Leukemia, Myelodysplasia, and Myeloproliferative Disease. In: Orkin SH, Fisher DE, Ginsburg D, Look AT, Lux SE, Nathan DG, eds. Nathan and Oski's Hematology and Oncology of Infancy and Childhood. 8th ed. Philadelphia, PA: Elsevier Saunders; 2015:1555-1613.
6. Kobos R, Shukla N, and Armstrong SA. Infant Leukemias. In: Orkin SH, Fisher DE, Ginsburg D, Look AT, Lux SE, Nathan DG, eds. Nathan and Oski's Hematology and Oncology of Infancy and Childhood. 8th ed. Philadelphia, PA: Elsevier Saunders; 2015:1614-1625.
7. Kaplan JA. Leukemia in children. *Pediatr Rev.* 2019;40:319-331. doi: 10.1542/pir.2018-0192.
8. Brown P, Inaba H, Annesley C, et al. National Comprehensive Cancer Network (NCCN) Guidelines Version 1.2022—October 1, 2021, Pediatric Acute Lymphoblastic Leukemia, available at: [https://www.nccn.org/professionals/physician\\_gls/pdf/ped\\_all.pdf](https://www.nccn.org/professionals/physician_gls/pdf/ped_all.pdf), Referenced with permission from the NCCN Clinical Practice Guidelines in Oncology (NCCN Guidelines™) for Pediatric Acute Lymphoblastic Leukemia V1.2022 10/1/2021. ©2021 National Comprehensive Cancer Network, Inc. All rights reserved. The NCCN Guidelines™ and illustrations herein may not be reproduced in any form for any purpose without the express written permission of the NCCN. To view the most recent and complete version of the NCCN Guidelines™, go online to NCCN.org.
9. Ranta S, Palomäki M, Levinsen M, et al. Role of neuroimaging in children with Acute Lymphoblastic Leukemia and central nervous system involvement at diagnosis. *Pediatr Blood Cancer.* 2016;64:64-70. doi:10.1002/pbc.26182/epdf.
10. Agrawal AK, Saini N, Gildengorin G et al. Is routine computed tomographic scanning justified in the first week of persistent febrile neutropenia in children with malignancies? *Pediatr Blood Cancer.* 2011;57(4):620-624. doi:10.1002/pbc.22974/epdf.
11. Pui C-H, Yang JJ, Hunger SP, et al. Childhood Acute Lymphoblastic Leukemia: progress through collaboration. *J Clin Oncol.* 2015;33(27):2938-2948. doi: 10.1200/JCO.2014.59.1636.
12. Kawedia JD, Kaste SC, Pei D, et al. Pharmacokinetic, pharmacodynamic, and pharmacogenetic determinants of osteonecrosis in children with acute lymphoblastic leukemia. *Blood Journal.* 2011;117(8):2340-2347. doi:10.1182/blood-2010-10-311969.
13. Marcucci G, Beltrami G, Tamburini A, et al. Bone health in childhood cancer: review of the literature and recommendations for the management of bone health in childhood cancer survivors. *Ann Oncol* 2019;30:908-920. doi:10.1093/annonc/mdz120.
14. Vora A. Management of osteonecrosis in children and young adults with acute lymphoblastic leukaemia. *Br J Haematol.* 2011;155(5):549-560. doi:10.1111/j.1365-2141.2011.08871.x.
15. Kaste SC, Pei D, Cheng C, et al. Utility of early screening magnetic resonance imaging for extensive hip osteonecrosis in pediatric patients treated with glucocorticoids. *J Clin Oncol.* 2015;33(6):610-615. doi:10.1200/JCO.2014.57.5480.
16. Niinimäki T, Harila-Saari A, Niinimäki R. The diagnosis and classification of osteonecrosis in patients with childhood Leukemia. *Pediatr Blood Cancer.* 2015;62(2):198-203. doi:10.1002/pbc.25295.
17. Murphey MD, Roberts CC, Bencardino JT, et al. Osteonecrosis of the hip. *ACR Appropriateness Criteria®* 2015;1-12. Revised: 2022. <https://acsearch.acr.org/docs/69420/Narrative/>.
18. Karol SE, Mattano LA, Yang W, et al. Genetic risk factors for the development of osteonecrosis in children under age 10 treated for acute lymphoblastic leukemia. *Blood Journal.* 2016;127(5):558-564. doi:10.1182/blood-2015-10-673848.
19. Chavhan GB, Babyn PS, Nathan PC, et al. Imaging of acute and subacute toxicities of cancer therapy in children. *Pediatr Radiol.* 2016;46(1):9-20. doi:10.1007/s00247-015-3454-1.
20. Lauer M, Kernen E, Schwabe D, Lehrnbecher T, Porto L. The role of magnetic resonance imaging in the diagnosis of central nervous system involvement in children with acute lymphoblastic leukemia. *Pediatr Blood Cancer.* 2020;e28294. doi:10.1002/pbc.28294.

<b>Pediatric CNS Tumors (PEDONC-4)</b>
<b>Pediatric CNS Tumors General Considerations (PEDONC-4.1)</b>
<b>CNS Low Grade Gliomas (LGG) (PEDONC-4.2)</b>
<b>CNS High Grade Gliomas (HGG) (PEDONC-4.3)</b>
<b>Medulloblastoma (MDB), Supratentorial Primitive Neuroectodermal Tumors (sPNET), and Pineoblastoma (PEDONC-4.4)</b>
<b>Atypical Teratoid/Rhabdoid Tumors (ATRT) (PEDONC-4.5)</b>
<b>Pineocytomas and Pineal Parenchymal Tumors (PEDONC-4.6)</b>
<b>CNS Germinomas and Non-Germinomatous Germ Cell Tumors (NGGCT) (PEDONC-4.7)</b>
<b>Ependymoma (PEDONC-4.8)</b>
<b>Malignant Tumors of the Spinal Cord (PEDONC-4.9)</b>
<b>Craniopharyngioma and Other Hypothalamic/Pituitary Region Tumors (PEDONC-4.10)</b>
<b>Primary CNS Lymphoma (PEDONC-4.11)</b>
<b>Meningiomas (PEDONC-4.12)</b>
<b>Choroid Plexus Tumors (PEDONC-4.13)</b>

## **Pediatric CNS Tumors General Considerations (PEDONC-4.1)**

- Central nervous system tumors are the second most common form of childhood cancer, accounting for ~20% of all pediatric malignancies

<b>Red Flag Symptoms Raising Suspicion for CNS Tumors Include:</b>
Any headache complaint from a child age $\leq 5$ years
Headaches awakening from sleep
Focal findings on neurologic exam
Clumsiness (common description of gait or coordination problems in young children)
Headaches associated with morning nausea/vomiting
New onset of seizure activity with focal features
Papilledema on physical exam

### **MRI Considerations**

- MRI is the preferred imaging modality for all pediatric CNS tumors
  - ◆ MRI Brain without and with contrast (CPT<sup>®</sup> 70553) is the primary imaging study for pediatric brain tumors
  - ◆ MRI Brain without contrast (CPT<sup>®</sup> 70551) if requested for initial evaluation of suspected CNS tumor for children able to undergo MRI without sedation
  - ◆ Initial MRI should be performed without and with contrast in order to avoid a second anesthesia exposure in younger children requiring sedation for MRI
- MRI Spine with contrast only (Cervical-CPT<sup>®</sup> 72142, Thoracic-CPT<sup>®</sup> 72147, Lumbar-CPT<sup>®</sup> 72149) can be substituted where MRI Spine without and with contrast is indicated, if being performed immediately following a contrast-enhanced MRI Brain
- Functional MRI (CPT<sup>®</sup> 70555 or CPT<sup>®</sup> 70554) is indicated to depict spatial relationships between eloquent cortex and neoplasms for preoperative planning and to promote safe resections (following baseline MRI Brain).

### **CT Considerations**

- CT for evaluation of ventriculomegaly or other operative considerations, or for children who cannot undergo MRI safely
  - ◆ CT for evaluation of headaches related to head trauma or evaluation of skull or facial bone abnormalities
- CT is not a recommended study for evaluation of pediatric headache when brain tumor is clinically suspected because of its limited diagnostic accuracy in this area. MRI should be used as first line imaging in these cases
- CT should not be used in place of MRI to avoid sedation in young children when red flag symptoms for CNS tumors are present

### **MRA/CTA and Perfusion Studies**

- MRA or CTA **only** for preoperative planning or to clarify inconclusive findings on MRI or CT
- CT and MRI Perfusion
  - ◆ See: **CT or MRI Perfusion (HD-24.5)** in the Head Imaging guidelines

### **MR Spectroscopy (MRS, CPT® 76390)**

- MRS is only supported for use in brain tumors of specified histologies where diagnostic accuracy has been established in peer-reviewed literature
  - ◆ See diagnosis-specific guidelines for MRS indications
- MRS is considered investigational/experimental for all other histologies and indications not listed in a diagnosis-specific guideline section
- MR spectroscopy is not indicated for routine surveillance

### **PET Brain Imaging (CPT® 78608 and CPT® 78609)**

- PET Brain Metabolic imaging (CPT® 78608) is **only** supported for use in brain tumors of specified histologies where diagnostic accuracy has been established in peer-reviewed literature
  - ◆ See diagnosis-specific guidelines for PET indications
- PET Brain Metabolic is not indicated for routine surveillance
- PET Brain Metabolic imaging is considered investigational/experimental for all other histologies and indications not listed in a diagnosis-specific guideline section
- PET Brain Perfusion imaging (CPT® 78609) is not indicated in the evaluation or management of primary CNS tumors
- Fusion PET/CT studies (CPT® 78814, CPT® 78815, or CPT® 78816) are not indicated in the evaluation or management of primary CNS tumors

### **Timing and Frequency of Imaging**

- Definitive imaging should be completed prior to considering biopsy given the high degree of morbidity associated with operating on the CNS
  - ◆ Occasionally biopsy is not necessary because the imaging findings provide a definitive diagnosis
    - Examples include diffuse intrinsic pontine glioma and optic pathway gliomas in an individual with known neurofibromatosis
- Perioperative imaging frequency
  - ◆ Children may undergo very frequent imaging in the immediate perioperative period around resection or debulking of a CNS tumor due to the small anatomic spaces involved
    - Requests for imaging during this time period to specifically evaluate postoperative course or ventriculoperitoneal shunt functioning should, in general, be approved as requested
  - ◆ MRI Brain without and with contrast (CPT® 70553) one time in the immediate preoperative period (even if another study has already been completed) to gain additional information which can be important in optimizing individual outcomes, such as:
    - Completion of additional specialized MRI sequences such as diffusion-tensor imaging
    - Perfusion imaging
    - Tractography

- Other sequences not reported under a separate CPT® code but not part of a routine MRI Brain series
- ◆ Repeat MRI Brain that is being requested solely for loading into operative navigation software should not be requested as a diagnostic code but can be approved under a treatment planning code (CPT® 76498).

### **CNS Low Grade Gliomas (LGG) (PEDONC-4.2)**

- MR Spectroscopy and PET Brain Metabolic are not indicated for routine surveillance
- MRI is generally superior to CT for staging and restaging CNS malignancies, but CT may be approved in accordance with these guidelines where MRI is contraindicated.

Indication	Imaging Study
Initial staging of all LGG	<ul style="list-style-type: none"> <li>➤ MRI Brain without and with contrast (CPT® 70553)</li> <li>➤ MRI Spine without and with contrast (Cervical-CPT® 72156, Thoracic-CPT® 72157, Lumbar-CPT® 72158)</li> </ul>
<ul style="list-style-type: none"> <li>➤ <u>EITHER</u> of the following:                             <ul style="list-style-type: none"> <li>◆ Determining the need for biopsy when transformation to high grade glioma is suspected based on clinical symptoms or recent MRI findings</li> <li>◆ Evaluation of a brain lesion of indeterminate nature when the PET findings will be used to determine whether biopsy/resection can be safely postponed</li> </ul> </li> </ul>	<ul style="list-style-type: none"> <li>➤ PET Brain Metabolic imaging (CPT® 78608)</li> </ul>
<ul style="list-style-type: none"> <li>➤ <u>ANY</u> of the following:                             <ul style="list-style-type: none"> <li>◆ Distinguish low grade from high grade gliomas</li> <li>◆ Evaluate a brain lesion of indeterminate nature when the MRS findings will be used to determine whether biopsy/resection can be safely postponed</li> <li>◆ Distinguish radiation-induced tumor necrosis from progressive disease within 18 months of completing radiotherapy</li> </ul> </li> </ul>	<ul style="list-style-type: none"> <li>➤ MR Spectroscopy (MRS, CPT® 76390)</li> </ul>
Baseline imaging after resection, to assess degree of resection	<ul style="list-style-type: none"> <li>➤ MRI Brain without and with contrast (CPT® 70553)</li> <li>➤ MRI with and without contrast at level of resected spinal site</li> </ul>
Treatment response at the completion of radiotherapy	<ul style="list-style-type: none"> <li>➤ MRI Brain without and with contrast (CPT® 70553)</li> <li>➤ MRI with and without contrast at level of irradiated spinal site</li> </ul>

Indication	Imaging Study
Treatment response on chemotherapy	➤ MRI Brain without and with contrast (CPT® 70553) approved every 2 cycles during active treatment and at the end of planned chemotherapy
Additional treatment response imaging during induction chemotherapy for individuals with measurable spinal cord disease on MRI	➤ MRI Spine without and with contrast (Cervical-CPT® 72156, Thoracic-CPT® 72157, Lumbar-CPT® 72158) every 2 cycles
Surveillance	<ul style="list-style-type: none"> <li>➤ <u>For individuals with intracranial primary:</u> <ul style="list-style-type: none"> <li>◆ MRI Brain without and with contrast (CPT® 70553) every 3 months for 2 years, then every 6 months for 3 years, then annually thereafter.</li> <li>◆ MRI Spine is not indicated during surveillance in individuals without prior history of spinal involvement except to evaluate symptoms suspicious for spinal cord recurrence</li> </ul> </li> <li>➤ <u>For individuals with a history of spine primary tumor or metastatic spinal involvement:</u> <ul style="list-style-type: none"> <li>◆ MRI Spine without and with contrast (Cervical-CPT® 72156, Thoracic-CPT® 72157, Lumbar-CPT® 72158) every 3 months for 2 years, then every 6 months for 3 years, then annually thereafter</li> </ul> </li> </ul>
Surveillance imaging for individuals with optic pathway glioma and either a history of intra-orbital involvement or a history of NF1	<ul style="list-style-type: none"> <li>➤ <u>Every 3 months for 2 years, then every 6 months for 3 years, then annually thereafter:</u> <ul style="list-style-type: none"> <li>◆ MRI Brain without and with contrast (CPT® 70553) and</li> <li>◆ MRI Orbits without and with contrast (CPT® 70543)</li> </ul> </li> </ul>
Suspected intracranial or intraspinal recurrence	➤ All imaging supported in initial staging criteria may be repeated
	➤

**Background and Supporting Information**

Includes the following tumors:
<ul style="list-style-type: none"> <li>◆ Pilocytic Astrocytoma</li> <li>◆ Fibrillary (or Diffuse) Astrocytoma</li> <li>◆ Optic Pathway Gliomas</li> <li>◆ Pilomyxoid Astrocytoma</li> <li>◆ Oligodendroglioma</li> <li>◆ Oligoastrocytoma</li> <li>◆ Oligodendrocytoma</li> <li>◆ Subependymal Giant Cell Astrocytoma (SEGA)</li> <li>◆ Ganglioglioma</li> <li>◆ Gangliocytoma</li> <li>◆ Dysembryoplastic Infantile Astrocytoma (DIA)</li> <li>◆ Dysembryoplastic Infantile Ganglioglioma (DIG)</li> <li>◆ Dysembryoplastic Neuroepithelial Tumor (DNT)</li> <li>◆ Tectal Plate Gliomas</li> </ul>



Includes the following tumors:
<ul style="list-style-type: none"> <li>◆ Cervicomedullary Gliomas</li> <li>◆ Pleomorphic Xanthoastrocytoma (PXA)</li> <li>◆ Any other glial tumor with a WHO grade of I or II</li> </ul>

**General Considerations:**

- Account for 40 to 60% of pediatric CNS tumors.
- These tumors are defined as having a WHO histologic grade of I or II (out of IV), can occur anywhere in the CNS

**Treatment Considerations:**

- Children with neurofibromatosis and small optic pathway tumors may not undergo biopsy or resection and will proceed directly to treatment or surveillance
- Children on observation without specific treatment should be imaged according to surveillance guidelines for LGG
- Individuals who undergo complete resection should be imaged according to surveillance guidelines after post-resection imaging
- Individuals age >10 years with incompletely resected tumors usually receive adjuvant radiation therapy
- Individuals age ≤10 years with incompletely resected tumors are commonly treated with chemotherapy

**CNS High Grade Gliomas (HGG) (PEDONC-4.3)**

Indication	Imaging Study
Initial staging of all HGG	<ul style="list-style-type: none"> <li>➤ MRI Brain without and with contrast (CPT® 70553)</li> <li>➤ MRI Spine without and with contrast (Cervical-CPT® 72156, Thoracic-CPT® 72157, Lumbar-CPT® 72158)</li> <li>➤ 3D rendering may be approved as requested for initial staging</li> </ul>
At any time, for rapid assessment in the acute setting and for the evaluation of acute intracranial hemorrhage, ventriculomegaly and shunt-related issues.	<ul style="list-style-type: none"> <li>➤ CT Head with contrast (CPT® 70460) or without and with contrast (CPT® 70470)</li> </ul>

Indication	Imaging Study
<ul style="list-style-type: none"> <li>➤ <u>ANY of the following:</u> <ul style="list-style-type: none"> <li>◆ Distinguishing radiation-induced tumor necrosis from progressive disease within 18 months of completing radiotherapy</li> <li>◆ Evaluating inconclusive MRI findings when the PET findings will be used to determine need for biopsy or change in therapy, including a change from active therapy to surveillance</li> <li>◆ Evaluation of a brain lesion of indeterminate nature when the PET findings will be used to determine whether biopsy/resection can be safely postponed</li> </ul> </li> </ul>	<ul style="list-style-type: none"> <li>➤ PET Brain Metabolic Imaging (CPT® 78608)</li> </ul>
<ul style="list-style-type: none"> <li>➤ <u>ANY of the following:</u> <ul style="list-style-type: none"> <li>◆ To distinguish low grade from high grade gliomas</li> <li>◆ To evaluate a brain lesion of indeterminate nature when the MRS findings will be used to determine whether biopsy/resection can be safely postponed</li> <li>◆ To distinguish radiation-induced tumor necrosis from progressive disease within 18 months of completing radiotherapy</li> </ul> </li> </ul>	<ul style="list-style-type: none"> <li>➤ MR Spectroscopy (MRS, CPT® 76390)</li> </ul>
<p>Baseline imaging following resection, to assess degree of resection</p>	<ul style="list-style-type: none"> <li>➤ MRI Brain without and with contrast (CPT® 70553)</li> <li>➤ MRI with and without contrast at level of resected spinal site</li> </ul>
<p>Treatment response at the completion of radiotherapy</p>	<ul style="list-style-type: none"> <li>➤ MRI Brain without and with contrast (CPT® 70553)</li> <li>➤ MRI with and without contrast at level of irradiated spinal site</li> </ul>
<p>Treatment response on chemotherapy</p>	<ul style="list-style-type: none"> <li>➤ MRI Brain without and with contrast (CPT® 70553) every 2 cycles during active treatment and at the end of planned chemotherapy</li> </ul>
<p>Additional treatment response imaging during induction chemotherapy for individuals with measurable spinal cord disease on MRI</p>	<ul style="list-style-type: none"> <li>➤ MRI Spine without and with contrast (Cervical-CPT® 72156, Thoracic-CPT® 72157, Lumbar-CPT® 72158) every 2 cycles</li> </ul>

Indication	Imaging Study
Surveillance	<ul style="list-style-type: none"> <li>➤ <u>For individuals with intracranial primary:</u> <ul style="list-style-type: none"> <li>◆ MRI Brain without and with contrast (CPT® 70553) every 3 months for 3 years, then every 6 months thereafter</li> <li>◆ MRI Spine is not indicated during surveillance in individuals without prior history of spinal involvement except to evaluate symptoms suspicious for spinal cord recurrence</li> </ul> </li> <li>➤ <u>For individuals with a history of spine primary tumor or metastatic spinal involvement:</u> <ul style="list-style-type: none"> <li>◆ MRI Spine without and with contrast (Cervical-CPT® 72156, Thoracic-CPT® 72157, Lumbar-CPT® 72158) every 3 months for 3 years, then every 6 months thereafter</li> </ul> </li> </ul>
Suspected intracranial or intraspinal recurrence	➤ All imaging supported for initial staging may be repeated
Suspected spinal cord recurrence	➤ MRI Spine without and with contrast (Cervical-CPT® 72156, Thoracic-CPT® 72157, Lumbar-CPT® 72158)

**Background and Supporting Information**

Includes the following tumors:
<ul style="list-style-type: none"> <li>◆ Anaplastic astrocytoma</li> <li>◆ Glioblastoma multiforme</li> <li>◆ Diffuse intrinsic pontine glioma (DIPG, or “Brainstem glioma”)</li> <li>◆ Gliomatosis cerebri</li> <li>◆ Gliosarcoma</li> <li>◆ Anaplastic oligodendroglioma</li> <li>◆ Anaplastic ganglioglioma</li> <li>◆ Anaplastic mixed glioma</li> <li>◆ Anaplastic mixed ganglioneuronal tumors</li> <li>◆ Any other glial tumor with a WHO grade of III or IV</li> </ul>

**General Considerations:**

- Rare in children compared with the adult population but represent 10% to 20% of pediatric CNS tumors
- Prognosis is very poor, and survival significantly beyond 3 years from diagnosis is rare, even with complete surgical resection at initial diagnosis
- These tumors are defined as having a WHO histologic grade of III or IV (out of IV) can occur anywhere in the CNS (though the majority occur in the brain)

**Treatment Considerations:**

- Individuals who undergo complete resection should be imaged according to surveillance guidelines after post-resection imaging
- Individuals with incompletely resected tumors are commonly treated with chemotherapy

## **Medulloblastoma (MDB), Supratentorial Primitive Neuroectodermal Tumors (sPNET), and Pineoblastoma (PEDONC-4.4)**

➤ MR Spectroscopy and PET Brain Metabolic are not indicated for routine surveillance

Indication	Imaging Study
Initial staging for all individuals, preoperatively	<ul style="list-style-type: none"> <li>➤ MRI Brain without and with contrast (CPT® 70553)</li> <li>➤ MRI spine without and with contrast (Cervical-CPT® 72156, Thoracic-CPT® 72157, Lumbar-CPT® 72158)</li> </ul>
<ul style="list-style-type: none"> <li>➤ <u>ANY of the following:</u> <ul style="list-style-type: none"> <li>◆ To distinguish radiation-induced tumor necrosis from progressive disease within 18 months of completing radiotherapy</li> <li>◆ To evaluate inconclusive MRI findings when the PET findings will be used to determine need for biopsy or change in therapy, including a change from active therapy to surveillance</li> <li>◆ To evaluate a brain lesion of indeterminate nature when the PET findings will be used to determine whether biopsy/resection can be safely postponed</li> </ul> </li> </ul>	<ul style="list-style-type: none"> <li>➤ PET Brain Metabolic Imaging (CPT® 78608)</li> </ul>
<ul style="list-style-type: none"> <li>➤ <u>ANY of the following:</u> <ul style="list-style-type: none"> <li>◆ To evaluate a brain lesion of indeterminate nature when the MRS findings will be used to determine whether biopsy/resection can be safely postponed</li> </ul> </li> </ul>	<ul style="list-style-type: none"> <li>➤ MR Spectroscopy (CPT® 76390)</li> </ul>
Postoperative (preferably within 48 hours of surgery) to quantify residual tumor volume	<ul style="list-style-type: none"> <li>➤ MRI Brain without and with contrast (CPT® 70553)</li> </ul>
Within 28 days post-op, if spinal imaging was not performed preoperatively	<ul style="list-style-type: none"> <li>➤ MRI Spine without and with contrast (Cervical-CPT® 72156, Thoracic-CPT® 72157, Lumbar-CPT® 72158)</li> </ul>
Treatment response	<ul style="list-style-type: none"> <li>➤ At the start of adjuvant chemotherapy and every 2 cycles until therapy is completed:                             <ul style="list-style-type: none"> <li>◆ MRI Brain without and with contrast (CPT® 70553)</li> <li>◆ MRI Spine without and with contrast (Cervical-CPT® 72156, Thoracic CPT® 72157, Lumbar-CPT® 72158)</li> </ul> </li> </ul>

Indication	Imaging Study
Children age <3 years treated with multiple cycles of high dose chemotherapy with autologous stem cell rescue in lieu of radiotherapy	<ul style="list-style-type: none"> <li>➤ Disease evaluations (imaging per treatment response guidelines) may occur prior to each cycle (every 4 to 6 weeks) if needed for response determination.</li> </ul>
End of treatment evaluation	<ul style="list-style-type: none"> <li>➤ MRI Brain without and with contrast (CPT® 70553)</li> <li>➤ MRI Spine with contrast (Cervical-CPT® 72142, Thoracic-CPT® 72147, Lumbar-CPT® 72149) or MRI Spine without and with contrast (Cervical-CPT® 72156, Thoracic-CPT® 72157, Lumbar-CPT® 72158)</li> </ul>
Surveillance	<ul style="list-style-type: none"> <li>➤ Every 3 months for 3 years, then every 6 months for 2 years, then annually for 10 years:                             <ul style="list-style-type: none"> <li>◆ MRI Brain without and with contrast (CPT® 70553)</li> <li>◆ MRI Spine without and with contrast (Cervical-CPT® 72156, Thoracic-CPT® 72157, Lumbar-CPT® 72158)</li> </ul> </li> </ul>

### Background and Supporting Information

Includes the Following Tumors:
<ul style="list-style-type: none"> <li>➤ Medulloblastoma and Pineoblastoma</li> <li>➤ sPNET                             <ul style="list-style-type: none"> <li>◆ Medulloepithelioma</li> <li>◆ Cerebral or cerebellar neuroblastoma</li> <li>◆ Cerebral or cerebellar ganglioneuroblastoma</li> <li>◆ Ependymoblastoma</li> </ul> </li> </ul>
Risk Assessment is Important in Determining Optimal Treatment High-Risk Features Include the Following:
<ul style="list-style-type: none"> <li>➤ Spinal metastasis (including cytology positive only)</li> <li>➤ Multifocal intracranial tumors</li> <li>➤ Anaplastic histology</li> <li>➤ All sPNET and pineoblastomas</li> <li>➤ &gt; 1.5 cm<sup>2</sup> residual tumor area on postoperative MRI and age &lt; 3 years</li> </ul>
Individuals without any high-risk features are considered “Average Risk”

### General Considerations:

- Account for 15% to 25% of pediatric CNS tumors
- Prognosis is generally favorable
- Leptomeningeal spread is common and can occur after initial diagnosis

### **Treatment Considerations:**

- Individuals generally proceed to chemoradiotherapy within 31 days of surgical resection
  - ◆ All individuals receive adjuvant chemotherapy lasting 6 to 12 months that begins ~6 weeks after completion of chemoradiotherapy

### **Atypical Teratoid/Rhabdoid Tumors (ATRT) (PEDONC-4.5)**

- PET Brain Metabolic does not have a defined role in the evaluation of ATRT at this time
- MR Spectroscopy is not indicated for routine surveillance

Indication	Imaging Study
Initial staging for all individuals, preoperatively	<ul style="list-style-type: none"> <li>➤ MRI Brain without and with contrast (CPT® 70553)</li> <li>➤ MRI Spine without and with contrast (Cervical-CPT® 72156, Thoracic-CPT® 72157, Lumbar-CPT® 72158)</li> <li>➤ Renal US (CPT® 76770)                             <ul style="list-style-type: none"> <li>◆ If renal US is abnormal, refer to: <b><u>Malignant Rhabdoid Tumor of the Kidney (MRT) and Other Extracranial Sites (PEDONC-7.6)</u></b></li> </ul> </li> </ul>
Evaluation of a brain lesion of indeterminate nature when the MRS findings will be used to determine whether biopsy/resection can be safely postponed	<ul style="list-style-type: none"> <li>➤ MR Spectroscopy (CPT® 76390)</li> </ul>
Postoperative (preferably within 48 hours of surgery) to quantify residual tumor volume	<ul style="list-style-type: none"> <li>➤ MRI Brain without and with contrast (CPT® 70553)</li> </ul>
Within 28 days post-op, if spinal imaging was not performed preoperatively	<ul style="list-style-type: none"> <li>➤ MRI Spine without and with contrast (Cervical-CPT® 72156, Thoracic-CPT® 72157, Lumbar-CPT® 72158)</li> </ul>
Treatment response to induction chemotherapy	<ul style="list-style-type: none"> <li>➤ <u>After every 2 cycles:</u> <ul style="list-style-type: none"> <li>◆ MRI Brain without and with contrast (CPT® 70553)</li> <li>◆ MRI Spine without and with contrast (Cervical-CPT® 72156, Thoracic-CPT® 72157, Lumbar-CPT® 72158)</li> </ul> </li> </ul>
Individuals treated with consolidation chemotherapy and autologous stem cell rescue	<ul style="list-style-type: none"> <li>➤ Disease evaluation is indicated following the end of the planned stem cell rescues but may occur prior to each cycle (every 4 to 6 weeks) if needed for response determination</li> </ul>
End of treatment evaluation	<ul style="list-style-type: none"> <li>➤ MRI Brain without and with contrast (CPT® 70553)</li> <li>➤ MRI Spine without and with contrast (Cervical-CPT® 72156, Thoracic-CPT® 72157, Lumbar-CPT® 72158)</li> </ul>
Surveillance	<ul style="list-style-type: none"> <li>➤ <u>Every 3 months for 2 years, then every 6 months for 3 years, then annually for 10 years:</u> <ul style="list-style-type: none"> <li>◆ MRI Brain without and with contrast (CPT® 70553)</li> <li>◆ MRI Spine without and with contrast (Cervical-CPT® 72156, Thoracic-CPT® 72157, Lumbar-CPT® 72158)</li> </ul> </li> </ul>

## Background and Supporting Information

### **General Considerations:**

- Highly aggressive tumor occurring primarily in very young children that has a clinical presentation very similar to medulloblastoma with a much higher rate of leptomeningeal spread.
- Metastases can occur outside the CNS, and associated tumors can also arise in the kidneys (Malignant Rhabdoid Tumor of the Kidney, MRT).
  - ◆ Rhabdoid malignancies occurring outside the CNS should be imaged according to **Malignant Rhabdoid Tumor of the Kidney (MRT) and Other Extracranial Sites (PEDONC-7.6)**.
- Overall prognosis is poor, with <20% of individuals surviving beyond 2 years from diagnosis.
- Individuals generally proceed to induction chemotherapy shortly following surgical resection or biopsy.
- Following completion of chemotherapy, some individuals will proceed to radiotherapy.
  - ◆ MRI performed at the end of consolidation therapy should serve as the diagnostic MRI prior to radiotherapy.

### **Pineocytomas and Pineal Parenchymal Tumors (PEDONC-4.6)**

- PET Brain Metabolic imaging and MR Spectroscopy do not have a defined role in the evaluation of pineocytoma

Indication	Imaging Study
Initial staging for all individuals	➤ MRI Brain without and with contrast (CPT® 70553)
<ul style="list-style-type: none"> <li>➤ Additional initial staging imaging for individuals with:                             <ul style="list-style-type: none"> <li>◆ Multicentric tumors</li> <li>◆ Atypical histology including pineoblastoma-like elements (grade 2 or 3 pineal parenchymal tumor which have not been considered a pineoblastoma or PNET)</li> <li>◆ Clinical signs or symptoms suggesting spinal cord involvement</li> </ul> </li> </ul>	<ul style="list-style-type: none"> <li>➤ MRI Spine without and with contrast (Cervical-CPT® 72156, Thoracic-CPT® 72157, Lumbar-CPT® 72158)</li> </ul>
Baseline imaging following resection	➤ MRI Brain without and with contrast (CPT® 70553)
End of radiotherapy	➤ MRI Brain without and with contrast (CPT® 70553)
Additional imaging at end of radiotherapy for individuals with measurable spinal cord disease on MRI	➤ MRI Spine without and with contrast (Cervical-CPT® 72156, Thoracic-CPT® 72157, Lumbar-CPT® 72158)

Indication	Imaging Study
Surveillance	<ul style="list-style-type: none"> <li>➤ MRI Brain without and with contrast (CPT® 70553) every 3 months for 1 year, then every 4 months for 1 year, then every 6 months for 1 year, then annually thereafter</li> </ul>
Additional surveillance imaging for individuals with cord involvement at diagnosis	<ul style="list-style-type: none"> <li>➤ MRI Spine without and with contrast (Cervical-CPT® 72156, Thoracic-CPT® 72157, Lumbar-CPT® 72158) after completion of therapy every 3 months for 1 year, then every 4 months for 1 year, then every 6 months for 1 year, then annually thereafter</li> </ul>
Suspected spinal cord recurrence	<ul style="list-style-type: none"> <li>➤ MRI Spine without and with contrast (Cervical-CPT® 72156, Thoracic-CPT® 72157, Lumbar-CPT® 72158)</li> </ul>

### Background and Supporting Information

#### **General Considerations:**

- Low grade malignancy that is similar in presentation to low grade glioma (LGG)
- Surgical resection is curative for most individuals
  - ◆ Individuals with a complete resection should then be imaged according to surveillance guidelines
- Individuals with incompletely resected tumors may receive adjuvant radiation therapy
  - ◆ After end of radiotherapy imaging, these individuals should be imaged according to surveillance guidelines

### **CNS Germinomas and Non-Germinomatous Germ Cell Tumors (NGGCT) (PEDONC-4.7)**

- PET Metabolic Brain imaging does not have a defined role in the evaluation of CNS GCT

Indication	Imaging Study
Initial staging for all individuals	<ul style="list-style-type: none"> <li>➤ MRI Brain without and with contrast (CPT® 70553)</li> <li>➤ MRI Spine without and with contrast (Cervical-CPT® 72156, Thoracic-CPT® 72157, Lumbar-CPT® 72158)</li> </ul>
Evaluation of a brain lesion of indeterminate nature when the MRS findings will be used to determine whether biopsy/resection can be safely postponed	<ul style="list-style-type: none"> <li>➤ MR Spectroscopy (CPT® 76390)</li> </ul>
Treatment response to induction chemotherapy	<ul style="list-style-type: none"> <li>➤ MRI Brain without and with contrast (CPT® 70553) every 2 cycles</li> </ul>
Additional treatment response to induction chemotherapy for individuals with measurable spinal cord disease on MRI	<ul style="list-style-type: none"> <li>➤ MRI Spine without and with contrast (Cervical-CPT® 72156, Thoracic-CPT® 72157, Lumbar-CPT® 72158) every 2 cycles</li> </ul>



Indication	Imaging Study
End of induction chemotherapy for individuals with localized intracranial tumors	➤ MRI Spine without and with contrast (Cervical-CPT® 72156, Thoracic-CPT® 72157, Lumbar-CPT® 72158)
Prior to second-look surgery	➤ MRI of all known sites of measurable disease
Prior to radiotherapy	➤ MRI of all known sites of measurable disease
At the end of all planned therapy	➤ MRI Brain without and with contrast (CPT® 70553) ➤ MRI Spine (with or without and with contrast)
Surveillance	➤ <u>Every 3 months for 1 year, then every 4 months for 1 year, then every 6 months for 1 year, then annually until 5 years after completion of therapy:</u> ◆ MRI Brain without and with contrast (CPT® 70553) ◆ MRI Spine without and with contrast (Cervical-CPT® 72156, Thoracic-CPT® 72157, Lumbar-CPT® 72158)
Individuals in long term follow up after CNS tumor treatment that included radiation therapy	➤ See: <b><u>Second Malignant Neoplasms (SMN) (PEDONC-19.3)</u></b>
Suspected recurrence - new or worsening neurologic symptoms (including worsening of diabetes insipidus)	➤ MRI Brain without and with contrast (CPT® 70553) ➤ MRI Spine without and with contrast (Cervical-CPT® 72156, Thoracic-CPT® 72157, Lumbar-CPT® 72158)

### Background and Supporting Information

Includes the following tumors:
<ul style="list-style-type: none"> <li>➤ CNS Germinoma</li> <li>➤ Non-Germinomatous Germ Cell Tumors (NGGCT)                             <ul style="list-style-type: none"> <li>◆ Embryonal carcinoma</li> <li>◆ Yolk sac tumor</li> <li>◆ Choriocarcinoma</li> <li>◆ Teratoma</li> <li>◆ Mixed germ cell tumor</li> </ul> </li> </ul>

### **General Considerations:**

- More common in older school age children and younger adolescents but can occur throughout the pediatric age range
- Although leptomeningeal spread is common, prognosis is excellent due to high sensitivity to chemotherapy and radiotherapy
- Individuals generally proceed to chemotherapy shortly following surgical resection or biopsy and will usually receive 2 to 4 cycles
- Following completion of chemotherapy, individuals with residual disease will proceed to second-look surgery and/or radiotherapy

## **Ependymoma (PEDONC-4.8)**

- PET Brain Metabolic imaging does not have a defined role in the evaluation of ependymoma
- MR Spectroscopy is not indicated for routine surveillance

Indication	Imaging Study
Initial staging for all individuals	<ul style="list-style-type: none"> <li>➤ MRI Brain without and with contrast (CPT® 70553)</li> <li>➤ MRI Spine without and with contrast (Cervical-CPT® 72156, Thoracic-CPT® 72157, Lumbar-CPT® 72158)</li> </ul>
Evaluation of a brain lesion of indeterminate nature when the MRS findings will be used to determine whether biopsy/resection can be safely postponed	<ul style="list-style-type: none"> <li>➤ MR Spectroscopy (CPT® 76390)</li> </ul>
Baseline imaging following resection	<ul style="list-style-type: none"> <li>➤ MRI Brain without and with contrast (CPT® 70553) or MRI without and with contrast of involved spinal level(s)</li> </ul>
Completion of radiotherapy	<ul style="list-style-type: none"> <li>➤ MRI Brain without and with contrast (CPT® 70553) or MRI without and with contrast of involved spinal level(s)</li> </ul>
Prior to radiotherapy	<ul style="list-style-type: none"> <li>➤ MRI of all known sites of measurable disease</li> </ul>
Treatment response to induction chemotherapy	<ul style="list-style-type: none"> <li>➤ MRI Brain without and with contrast (CPT® 70553) or MRI without and with contrast of involved spinal level(s) every 2 cycles</li> </ul>
End of induction chemotherapy and again at end of all therapy	<ul style="list-style-type: none"> <li>➤ MRI Brain without and with contrast (CPT® 70553)</li> <li>➤ MRI Spine without and with contrast (Cervical-CPT® 72156, Thoracic-CPT® 72157, Lumbar-CPT® 72158)</li> </ul>
Prior to second-look surgery	<ul style="list-style-type: none"> <li>➤ MRI of all known sites of measurable disease</li> </ul>
Surveillance, primary intracranial ependymoma and NO history of spinal cord involvement	<ul style="list-style-type: none"> <li>➤ MRI Brain without and with contrast (CPT® 70553) every 3 months for 2 years, then every 4 months for 1 year, then every 6 months in years 4 and 5, then annually to 10 years post treatment</li> <li>➤ MRI Spine without and with contrast (Cervical-CPT® 72156, Thoracic-CPT® 72157, Lumbar-CPT® 72158) can be approved annually for 2 years</li> </ul>
Surveillance, primary intracranial ependymoma AND metastatic cord involvement at diagnosis	<ul style="list-style-type: none"> <li>➤ MRI Brain without and with contrast (CPT® 70553) every 3 months for 2 years, then every 4 months for 1 year, then every 6 months in years 4 and 5, then annually to 10 years post treatment</li> <li>➤ MRI Spine without and with contrast (Cervical-CPT® 72156, Thoracic-CPT® 72157, Lumbar-CPT® 72158) every 3 months for 2 years, then every 4 months for 1 year, then every 6 months in years 4 and 5, then annually to 10 years post treatment</li> </ul>

Indication	Imaging Study
Surveillance, primary intraspinal ependymoma and NO history of intracranial involvement	<ul style="list-style-type: none"> <li>➤ MRI without and with contrast of the involved spinal level(s) every 3 months for 2 years, then every 4 months for 1 year, then every 6 months in years 4 and 5, then annually to 10 years post treatment</li> <li>➤ MRI Brain without and with contrast (CPT® 70553) every 3 months for 2 years, then every 4 months for 1 year, then every 6 months in years 4 and 5, then annually to 10 years post treatment</li> </ul>
Surveillance, primary intraspinal ependymoma AND metastatic intracranial involvement at diagnosis	<ul style="list-style-type: none"> <li>➤ MRI Brain without and with contrast (CPT® 70553) and MRI of the involved spinal level(s) without and with contrast every 3 months for 2 years, then every 4 months for 1 year, then every 6 months in years 4 and 5, then annually to 10 years post treatment</li> </ul>

**Background and Supporting Information**

**General Considerations:**

- Occur primarily intracranially, roughly 2/3 in the posterior fossa
- Overall prognosis is very good, with supratentorial tumors faring better
- Primary spinal tumors can also occur, and are more common in adult individuals than pediatric individuals.
- Surgery is the primary treatment modality
- Individuals with a complete resection should then be imaged according to surveillance guidelines
- Radiotherapy +/- chemotherapy is used for:
  - ◆ Incompletely resected tumors
  - ◆ Anaplastic histology
  - ◆ Infratentorial location
    - Individuals with incomplete resection or high-risk histology that receive adjuvant radiation therapy should then be imaged according to surveillance guidelines after end of radiotherapy imaging.
- Individuals with gain of chromosome 1q have worse progression-free survival and overall survival outcomes
  - RELA-fusion supratentorial ependymoma did not portend worse overall survival outcomes in recent Clinical Oncology Group studies, and is generally not considered an indication for more frequent surveillance imaging

## **Malignant Tumors of the Spinal Cord (PEDONC-4.9)**

- If a disease-specific guideline exists, image according to the guidance found in that disease-specific guideline section.
- Common histologies of primary spinal cord tumor in children include:
  - ◆ Low Grade Glioma, see: **CNS Low Grade Glioma (LGG) (PEDONC-4.2)** for guidelines
  - ◆ High Grade Glioma, see: **CNS High-Grade Glioma (HGG) (PEDONC-4.3)** for guidelines
  - ◆ Ependymoma, see: **Ependymoma (PEDONC-4.8)** for guidelines
  - ◆ NF 1 or 2, see: **Neurofibromatosis 1 and 2 (NF1 and NF2) (PEDONC-2.3)** for guidelines
  - ◆ Any type of malignant spinal cord tumor can occur, but other histologies are rare.
- For rare histologies that do not have a disease-specific guideline section, follow the imaging outlined in the table below.

Indication	Imaging Study
Initial staging for all individuals	<ul style="list-style-type: none"> <li>➤ MRI Brain without and with contrast (CPT® 70553)</li> <li>➤ MRI Spine without and with contrast (Cervical-CPT® 72156, Thoracic-CPT® 72157, Lumbar-CPT® 72158)</li> </ul>
Treatment response, every 2 cycles	<ul style="list-style-type: none"> <li>➤ MRI Spine without and with contrast (Cervical-CPT® 72156, Thoracic-CPT® 72157, Lumbar-CPT® 72158)</li> <li>➤ Additionally, MRI Brain without and with contrast (CPT® 70553) for known intracranial disease</li> </ul>
<p>Surveillance of rare histologies is highly individualized.</p> <p>Surveillance imaging after recent evaluation by a physician with significant training and/or experience in pediatric spinal cord tumors (most commonly a pediatric neurosurgeon or pediatric oncologist) may be indicated in these rare individuals.</p>	<ul style="list-style-type: none"> <li>➤ MRI Brain and/or MRI Spine may be considered</li> </ul>

### ***Background and Supporting Information***

- Treatment principles are the same as tumors of the brain, and should follow imaging guidelines according to the specific histologic type
- Multiple spinal cord tumors should raise suspicion for neurofibromatosis
- Asymptomatic surveillance imaging should generally end at the time point appropriate for the specific tumor type

## **Craniopharyngioma and Other Hypothalamic/Pituitary Region Tumors (PEDONC-4.10)**

- Individuals of all ages should be imaged according to these guidelines.
- PET Brain Metabolic Imaging and MR Spectroscopy do not have a defined role in the evaluation of craniopharyngioma

Indication	Imaging Study
Initial staging for all individuals	<ul style="list-style-type: none"> <li>➤ MRI Brain without and with contrast (CPT® 70553)                             <ul style="list-style-type: none"> <li>◆ Concurrent CT Head without contrast (CPT® 70450) can be approved in addition to MRI if craniopharyngioma is suspected</li> </ul> </li> </ul>
<ul style="list-style-type: none"> <li>➤ <u>Additional initial staging for individuals with:</u> <ul style="list-style-type: none"> <li>◆ Multicentric tumors</li> <li>◆ Clinical signs or symptoms suggesting spinal cord involvement</li> </ul> </li> </ul>	<ul style="list-style-type: none"> <li>➤ MRI Spine without and with contrast (Cervical-CPT® 72156, Thoracic-CPT® 72157, Lumbar-CPT® 72158)</li> </ul>
Operative planning or image guidance	<ul style="list-style-type: none"> <li>➤ MRA Head (CPT® 70544, 70545, or 70546) OR</li> <li>➤ CTA Head (CPT® 70496)</li> </ul>
Baseline imaging following resection	<ul style="list-style-type: none"> <li>➤ MRI Brain without and with contrast (CPT® 70553)</li> </ul>
Completion of radiotherapy	<ul style="list-style-type: none"> <li>➤ MRI Brain without and with contrast (CPT® 70553)</li> </ul>
Treatment response to chemotherapy	<ul style="list-style-type: none"> <li>➤ MRI Brain without and with contrast (CPT® 70553) approved every 2 cycles during active treatment and at the end of planned chemotherapy</li> </ul>
Additional treatment response imaging during induction chemotherapy for individuals with measurable spinal cord disease on MRI	<ul style="list-style-type: none"> <li>➤ MRI Spine without and with contrast (Cervical-CPT® 72156, Thoracic-CPT® 72157, Lumbar-CPT® 72158) every 2 cycle</li> </ul>
Surveillance	<ul style="list-style-type: none"> <li>➤ MRI Brain without and with contrast (CPT® 70553) can be approved every 3 months for 1 year, then every 4 months for 1 year, then every 6 months for 1 year, then annually until 10 years after completion of therapy as late progressions can occur</li> </ul>
	<ul style="list-style-type: none"> <li>◆ For additional imaging guidelines for individuals in long term follow up after CNS tumor treatment that included radiation therapy, see: <b><u>Second Malignant Neoplasms (SMN) (PEDONC-19.3)</u></b></li> </ul>
Suspected spinal cord recurrence	<ul style="list-style-type: none"> <li>➤ MRI Spine without and with contrast (Cervical-CPT® 72156, Thoracic-CPT® 72157, Lumbar-CPT® 72158)</li> </ul>

### ***Background and Supporting Information***

## **General Considerations:**

- Imaging guidelines and treatment approaches for pediatric pituitary tumors other than craniopharyngioma are consistent with those used for adults with pituitary tumors
  - ◆ For these tumors follow guidelines in **Pituitary (HD-19)** in the Head Imaging Guidelines
- Craniopharyngiomas are less common, accounting for 6% to 8% of pediatric CNS tumors.
- Most commonly affects children in the preadolescent ages
- Several key imaging findings can be used to differentiate the tumors in this region including the presence of calcifications, cysts, and T1/T2 enhancement patterns in craniopharyngiomas
  - ◆ These are best evaluated using a COMBINATION of both MRI and CT modalities. Preoperative prediction is much more successful when BOTH modalities are obtained prior to biopsy.
- Other less common tumors in the optic chiasm, sella, and suprasella region may include Germ Cell Tumors (GCT, see: **PEDONC-4.7)** and Langerhans Cell Histiocytosis (LCH, see: **PEDONC-18)**

## **Treatment Considerations:**

- Surgical resection is curative for many individuals
  - ◆ Those with a complete resection should then be imaged according to surveillance guidelines after post-resection imaging is completed
- Individuals with incomplete resection and receiving adjuvant radiation therapy can have a single MRI Brain (CPT® 70553) approved at completion of radiotherapy and should then be imaged according to surveillance guidelines

## **Primary CNS Lymphoma (PEDONC-4.11)**

- Primary CNS lymphoma imaging indications in pediatric individuals are identical to those in the general imaging guidelines. See: **CNS Lymphoma (ONC-2.7)** in the Oncology Imaging Guidelines
- CNS lymphomas also involving bone marrow and/or lymph nodes should be imaged according to: **Pediatric Aggressive Mature B-Cell Non-Hodgkin Lymphomas (NHL) (PEDONC-5.3)**

## ***Background and Supporting Information***

- Primary CNS lymphoma is a solitary or multifocal mass occurring in the brain without evidence of systemic (bone marrow or lymph node) involvement
- Usually associated with immunodeficiency, this is a very rare entity in pediatrics accounting for <0.1% of pediatric malignancies, so age-specific guidelines have not been established

## **Meningiomas (PEDONC-4.12)**

- Meningioma imaging indications in pediatric individuals are identical to those in the general imaging guidelines
  - ◆ See: **Meningiomas (Intracranial and Intraspinal) (ONC-2.8)** in the Oncology Imaging Guidelines

### ***Background and Supporting Information***

- Account for 1% to 3% of pediatric CNS tumors
- Usually associated with neurofibromatosis type 2 (NF-2) or prior therapeutic radiation exposure to the brain
  - ◆ Lifetime risk may be as high as 20% for young children receiving whole brain radiotherapy, most commonly occurring 15 to 20 years after radiation exposure

## **Choroid Plexus Tumors (PEDONC-4.13)**

- PET Metabolic Brain imaging does not have a defined role in the evaluation of choroid plexus tumors

### **Choroid Plexus Papilloma:**

Indication	Imaging Study
Suspected/Diagnosis	➤ MRI Brain without and with contrast (CPT® 70553)
Evaluation of a brain lesion of indeterminate nature when the MRS findings will be used to determine whether biopsy/resection can be safely postponed	➤ MR Spectroscopy (CPT® 76390)
Suspected return of hydrocephalus, or return of hydrocephalus seen on CT imaging	➤ MRI Brain without and with contrast (CPT® 70553)

### **Choroid Plexus Adenoma or Atypical Choroid Plexus Papilloma**

Indication	Imaging Study
Suspected/Diagnosis	<ul style="list-style-type: none"> <li>➤ MRI Brain without and with contrast (CPT® 70553)</li> <li>➤ MRI Spine without and with contrast (Cervical-CPT® 72156, Thoracic-CPT® 72157, Lumbar-CPT® 72158)</li> </ul>
Evaluation of a brain lesion of indeterminate nature when the MRS findings will be used to determine whether biopsy/resection can be safely postponed	➤ MR Spectroscopy (CPT® 76390)
Suspected return of hydrocephalus, or return of hydrocephalus seen on CT imaging	➤ MRI Brain without and with contrast (CPT® 70553)

### **Choroid Plexus Carcinoma:**

Indication	Imaging Study
Initial staging of all individuals	<ul style="list-style-type: none"> <li>➤ MRI Brain without and with contrast (CPT® 70553)</li> <li>➤ MRI Spine without and with contrast (Cervical-CPT® 72156, Thoracic-CPT® 72157, Lumbar-CPT® 72158)</li> </ul>
Evaluation of a brain lesion of indeterminate nature when the MRS findings will be used to determine whether biopsy/resection can be safely postponed	<ul style="list-style-type: none"> <li>➤ MR Spectroscopy (CPT® 76390)</li> </ul>
Baseline imaging following resection	<ul style="list-style-type: none"> <li>➤ MRI Brain without and with contrast (CPT® 70553)</li> </ul>
Prior to radiotherapy	<ul style="list-style-type: none"> <li>➤ MRI Brain without and with contrast (CPT® 70553) and MRI with and without contrast of all known sites with measurable disease prior to radiotherapy.</li> </ul>
Completion of radiotherapy	<ul style="list-style-type: none"> <li>➤ MRI Brain without and with contrast (CPT® 70553)</li> </ul>
Treatment response to chemotherapy	<ul style="list-style-type: none"> <li>➤ MRI Brain without and with contrast (CPT® 70553) every 2 cycles during active treatment</li> </ul>
Additional treatment response to chemotherapy for individuals with measurable spinal cord disease on MRI	<ul style="list-style-type: none"> <li>➤ MRI Spine without and with contrast (Cervical-CPT® 72156, Thoracic-CPT® 72157, Lumbar-CPT® 72158) every 2 cycles during active treatment</li> </ul>
Prior to second-look surgery	<ul style="list-style-type: none"> <li>➤ MRI of all known sites of measurable disease</li> </ul>
End of all planned therapy	<ul style="list-style-type: none"> <li>➤ MRI Brain without and with contrast (CPT® 70553)</li> <li>➤ MRI Spine without and with contrast (Cervical-CPT® 72156, Thoracic-CPT® 72157, Lumbar-CPT® 72158)</li> </ul>
Surveillance, no history of spinal cord involvement	<ul style="list-style-type: none"> <li>➤ MRI Brain without and with contrast (CPT® 70553) every 4 months for 3 years, then every 6 months for 2 years after completion of therapy                             <ul style="list-style-type: none"> <li>◆ For additional imaging guidelines for individuals in long term follow up after CNS tumor treatment that included radiation therapy, see: <b><u>Second Malignant Neoplasms (SMN) (PEDONC-19.3)</u></b></li> </ul> </li> <li>➤ MRI Spine without and with contrast (Cervical-CPT® 72156, Thoracic-CPT® 72157, Lumbar-CPT® 72158) at 12 and 24 months after completion of therapy</li> </ul>
Surveillance, individuals with cord involvement at diagnosis	<ul style="list-style-type: none"> <li>➤ MRI Brain without and with contrast (CPT® 70553) every 4 months for 3 years, then every 6 months for 2 years after completion of therapy                             <ul style="list-style-type: none"> <li>◆ For additional imaging guidelines for individuals in long term follow up after CNS tumor treatment that included radiation therapy, see: <b><u>Second Malignant Neoplasms (SMN) (PEDONC-19.3)</u></b></li> </ul> </li> <li>➤ MRI Spine without and with contrast (Cervical-CPT® 72156, Thoracic-CPT® 72157, Lumbar-CPT® 72158) every 4 months for 3 years, then every 6 months for 2 years after completion of therapy</li> </ul>



### **Background and Supporting Information**

- As a group these account for 1% to 4% of pediatric CNS tumors, and 70% of choroid plexus tumors present within the first 2 years of life
- Includes the following tumors:
  - ◆ Choroid plexus papilloma
  - ◆ Choroid plexus adenoma, or atypical choroid plexus papilloma
  - ◆ Choroid plexus carcinoma
- Choroid plexus papillomas
  - ◆ Choroid plexus papillomas outnumber other choroid plexus tumors by 4 to 5 times.
  - ◆ These ventricular tumors commonly present with hydrocephalus caused by increased CSF production, resulting in signs of increased intracranial pressure.
  - ◆ Appearance on MRI is typical, and they are usually treated by excision.
  - ◆ Regrowth is rare
- Choroid Plexus Adenoma or Atypical Choroid Plexus Papilloma
  - ◆ These are extremely rare tumors with features midway in the malignant spectrum between papillomas and carcinomas
  - ◆ They are more prone to local invasion but rarely to metastasis
  - ◆ Presenting symptoms are similar to papillomas
  - ◆ Appearance on MRI is typical, and they are usually treated by excision
  - ◆ Spinal imaging may be approved if requested at initial diagnosis
  - ◆ Regrowth is rare
- Choroid Plexus Carcinoma
  - ◆ This is a very aggressive malignancy, with high rates of metastasis to other parts of the CNS
    - Overall incidence of metastases in choroid plexus carcinoma is 12%–50%, which is associated with a worse outcome
  - ◆ Prognosis is significantly less favorable than for papillomas with overall survival rates of 35% to 40%
  - ◆ *TP53* mutations and alternative lengthening telomeres (ALT) are common in individuals with choroid plexus carcinoma
  - ◆ Surgical gross total resection is curative for many individuals
  - ◆ Individuals with confirmed gross total resection should then be imaged according to surveillance guidelines
  - ◆ Individuals with incomplete resection who receive adjuvant radiation therapy should be imaged according to surveillance guidelines after end of radiotherapy imaging
  - ◆ MR Spectroscopy is not indicated for routine surveillance

## References

1. Parsons DW, Pollack IF, Hass-Kogan DA, et al. Gliomas, ependymomas, and other nonembryonal tumors of the central nervous system. In: Pizzo PA, Poplack DG, eds. Principles and Practice of Pediatric Oncology. 7th ed. Philadelphia, PA: Wolters Kluwer; 2016:628-670.
2. Chintagumpala MM, Paulino A, Panigraphy A, et al. Embryonal and pineal region tumors. In: Pizzo PA, Poplack DG, eds. Principles and Practice of Pediatric Oncology. 7th ed. Philadelphia, PA: Wolters Kluwer; 2016:671-699.
3. Kieran MW, Chi SN, Manley PE, et al. Tumors of the Brain and Spinal Cord. In: Orkin SH, Fisher DE, Ginsburg D, Look AT, Lux SE, Nathan DG, eds. Nathan and Oski's Hematology and Oncology of Infancy and Childhood. 8th ed. Philadelphia, PA: Elsevier Saunders; 2015:1779-1885.
4. Nabors LB, Portnow J, Ahluwalia M, et al. National Comprehensive Cancer Network (NCCN) Guidelines Version 1.2022—June 2,2022. Central Nervous System Cancers, available at: [https://www.nccn.org/professionals/physician\\_gls/pdf/cns.pdf](https://www.nccn.org/professionals/physician_gls/pdf/cns.pdf), referenced with permission from the NCCN Clinical Practice Guidelines in Oncology (NCCN Guidelines™) for Central Nervous System Cancers V2.2022 6/2/2022. ©2022 National Comprehensive Cancer Network, Inc. All rights reserved. The NCCN Guidelines™ and illustrations herein may not be reproduced in any form for any purpose without the express written permission of the NCCN. To view the most recent and complete version of the NCCN Guidelines™, go online to NCCN.org
5. Menashe SJ, Iyer RS. Pediatric Spinal neoplasia: a practical imaging overview of intramedullary, intradural, and osseous tumors. *Curr Probl Diagn Radiol.* 2013;42(6):249-265. doi:10.1067/j.cpradiol.2013.05.003.
6. Warmuth-Metz M. Imaging guidelines for pediatric brain tumor patients. In: Warmuth-Metz M, ed. *Imaging and Diagnosis in Pediatric Brain Tumor Studies.* Switzerland; Springer,Cham:2017:55-67.
7. Warren KW, Poussaint TY, Vezina G, et al. Challenges with defining response to antitumor agents in pediatric neuro-oncology: a report from the response assessment in pediatric neuro-oncology (RAPNO) working group. *Pediatr Blood Cancer.* 2013;60(9):1397-1401. doi:10.1002/psc.24562.
8. Zukotynski K, Fahey F, Kocak M, et al. 18F-FDG PET and MR Imaging associations across a spectrum of pediatric brain tumors: a report from the Pediatric Brain Tumor Consortium. *J Nucl Med.* 2014;55(9):1473-1480. doi:10.2967/jnumed.114.139626.
9. Gajjar A, Bowers DC, Karajannis MA, Leary S, Witt H, Gottardo NG. Pediatric brain tumors: innovative genomic information is transforming the diagnostic and clinical landscape. *J Clin Oncol.* 2015;33(27):2986-2998. doi:10.1200/JCO.2014.59.9217.
10. Brandão LA, Poussaint TY. Pediatric brain tumors. *Neuroimag Clin N Am.* 2013 August;23(3):499-525. [http://www.neuroimaging.theclinics.com/article/S1052-5149\(13\)00017-8/abstract](http://www.neuroimaging.theclinics.com/article/S1052-5149(13)00017-8/abstract).
11. Brandão LA and Castillo M. Adult brain tumors: clinical applications of magnetic resonance spectroscopy. *Neuroimag Clin N Am.* 2013;23(3):527-555. doi:10.1016/j.nic.2013.03.003
12. Zarifi M, Tzika AA. Proton MRS imaging in pediatric brain tumors. *Pediatr Radiol.* 2016;46(7):952-962. doi:10.1007/s00247-016-3547-5.
13. Uslu L, Doing J, Link M, Rosenberg J, Quon A, Daldrup-Link HE. Value of 18F-FDG-PET and PET/CT for evaluation of pediatric malignancies. *J Nucl Med.* 2015;56(2):274-286. doi:10.2967/jnumed.114.146290.
14. Soffietti R, Baumert BG, Bello L, et al. Guidelines on management of low-grade gliomas: report of an EFSN-EANO\* Task Force. *Eur J Neurol.* 2010;17(9):1124-1133. doi:10.1111/j.1468-1331.2010.03151.x.
15. Krueer MC, Kaplan AM, Etzl MM Jr, et al. The value of positron emission tomography and proliferation index in predicting progression in low-grade astrocytomas of childhood. *J Neurooncol.* 2009;95(2):239-245. doi:10.1007/s11060-009-9922-4.
16. Chamdine O, Broniscer A, Wu S, Gajjar A, Qaddoumi I. Metastatic low-grade gliomas in children: 20 years' experience at St. Jude Children's Research Hospital. *Pediatr Blood Cancer.* 2016;63(1):62-70. doi:10.1002/psc.25731.
17. Chalil A, Ramaswamy V. Low grade gliomas in children. *J Child Neurol.* 2016;31(4):517-522. doi:10.1177/0883073815599259.
18. Krishnatry R, Zhukova N, Stucklin ASG, et al. Clinical and treatment factors determining long-term outcomes for adult survivors of childhood low-grade glioma: a population-based study. *Cancer.* 2016;122(8):1261-1269. doi:10.1002/cncr.29907.
19. Ullrich NJ. Neurocutaneous Syndromes and brain tumors. *J Child Neurol.* 2016;31(12):1399-1411. doi:10.1177/0883073815604220.
20. Campian J, Gutmann DH. CNS tumors in neurofibromatosis. *J Clin Oncol.* 2017; 35(21):2378-2385. doi:10.1200/JCO.2016.71.7199.
21. Morris EB, Gajjar A, Okuma JO, et al. Survival and late mortality in long-term survivors of pediatric CNS tumors. *J Clin Oncol.* 2007;25(12):1532-1538. doi:10.1200/JCO.2006.09.8194.
22. Karthigeyan M, Gupta K, Salunke P. Pediatric central neurocytoma: a short series with literature review. *J Child Neurol.* 2016;32(1):53-59. Accessed January 3, 2018 doi:10.1177/0883073816668994.
23. Tisnado J, Young R, Peck KK, et al. Conventional and advanced imaging of diffuse intrinsic pontine glioma. *J Child Neurol.* 2016;31(12):1386-1393. doi:10.1177/0883073816634855.
24. Greenfield JP, Heredia AC, George E, Keiran MW, Morales La Madrid A. Gliomatosis cerebri: a consensus summary report from the First International Gliomatosis cerebri Group Meeting, March 26-27, 2015, Paris, France. *Pediatr Blood Cancer.* 2016;63(12):2072-2077. doi:10.1002/psc.26169.
25. Zaky W, Dhall G, Ji L, et al. Intensive induction chemotherapy followed by myeloablative chemotherapy with

- autologous hematopoietic progenitor cell rescue for young children newly-diagnosed with central nervous system atypical teratoid/rhabdoid tumors: the head start III experience. *Pediatr Blood Cancer*. 2014;61(1):95-101. doi:10.1002/pbc.24648.
26. Gururangan S, Hwang E, Herndon JE II, et al. [18F]Fluorodeoxyglucose-Positron Emission Tomography in patients with medulloblastoma. *Neurosurgery*. 2004;55(6):1280-1289. doi:10.1227/01.NEU.0000143027.41632.2B.
  27. Millard NE and DeBraganca KC. Medulloblastoma. *J Child Neurol*. 2016;31(12):1341-1353. doi:10.1177/0883073815600866.
  28. Koschmann C, Bloom K, Upadhyaya S, Geyer JR. Survival after relapse of medulloblastoma. *J Pediatr Hematol. Oncol*. 2016;38(4):269-273. doi:10.1097/MPH.0000000000000547.
  29. Martinex S, Khakoo Y, Giheeney S, et al. Marker (+) CNS germ cell tumors in remission: are surveillance MRI scans necessary? *Pediatr Blood Cancer*. 2014;61(5):853-854. Accessed January 3, 2018. doi:10.1002/pbc.24888.
  30. Goldman S, Bouffet E, Fisher PG, et al. Phase II trial assessing the ability of neoadjuvant chemotherapy with or without second-look surgery to eliminate measurable disease for nongerminomatous germ cell tumors: a children's oncology group study. *J Clin Oncol*. 2015;33(22):2464-2471. doi:10.1200/JCO.2014.59.5132.
  31. Abu Arja MH, Bouffet E, Finlay JL, AbdelBaki MS. Critical review of the management of primary central nervous system germ cell tumors. *Pediatr Blood Cancer*. 2019;66:e27658. doi:10.1002/pbc.27658.
  32. Vitanza NA, Partap S. Pediatric Ependymoma. *J Child Neurol*. 2016;31(12):1354-1366. doi:10.1177/0883073815610428
  33. Norris GA, Garcia J, Hankinson TC, et al. Diagnostic accuracy of neuroimaging in pediatric optic chiasm/suprasellar tumors. *Pediatr Blood Cancer*. 2019;66:e27860. doi:10.1002/pbc.27680.
  34. McCrea HJ, George E, Settler A, et al. Pediatric suprasellar tumors. *J Child Neurol*. 2016;31(12):1367-1376. doi:10.1177/0883073815620671.
  35. Grommes C, DeAngelis LM. Primary CNS lymphoma. *J Clin Oncol*. 2017;35(21):2410-2418. doi:10.1200/JCO.2017.72.7602.
  36. Larrew T, Eskandari R. Pediatric intraparenchymal meningioma, case report and comparative review. *Pediatr Neurosurg*. 2016;51(2):83-86. doi:10.1159/000441008.
  37. Li Z, Li H, Wang S, et al. Pediatric skull base meningiomas: clinical features and surgical outcomes. *J Child Neurol*. 2016;31(14):1523-1527. doi:10.1177/0883073816664669.
  38. Horská A, Barker PB. Imaging of brain tumors: MR Spectroscopy and metabolic imaging. *Neuroimaging Clin N Am*. 2010;20(3):293-310. doi:10.1016/j.nic.2010.04.003.
  39. Sundgren PC. MR Spectroscopy in radiation injury. *AJNR Am J Neuroradiol*. 2009;30(8):1469-1476. doi:10.3174/ajnr.A1580.
  40. Zaky W, Dhall G, Khatua S, et al. Choroid plexus carcinoma in children: the head start experience. *Pediatr Blood Cancer*. 2015;62(5):784-789. doi:10.1002/pbc.25436.
  41. Zaky W, Finlay JL. Pediatric choroid plexus carcinoma: Biologically and clinically in need of new perspectives, *Pediatr Blood Cancer* 2018;65:e27031. doi:10.1002/pbc.27031.
  42. Kramer K. Rare primary central nervous system tumors encountered in pediatrics. *J Child Neurol*. 2016;31(12):1394-1398. doi:10.1177/0883073815627878.
  43. Merchant TE, Bendel AE, Sabin ND, et al. Conformal radiation therapy for pediatric ependymoma, chemotherapy for incompletely resected ependymoma, and observation for completely resected, supratentorial ependymoma. *J Clin Oncol*. 2019;37(12):974-983. doi:10.1200/JCO.18.01765.
  44. PDQ® Pediatric Treatment Editorial Board. PDQ Childhood Medulloblastoma and Other Central Nervous System Embryonal Tumors Treatment. Bethesda, MD: National Cancer Institute. Updated 8/16/2022. Available at: <https://www.cancer.gov/types/brain/hp/child-cns-embryonal-treatment-pdq>. [PMID: 26389418]
  45. Burns J, Policeni B, Bykowski J, et al. ACR Appropriateness Criteria® Neuroendocrine Imaging. Available at <https://acsearch.acr.org/docs/69485/Narrative/>. American College of Radiology.
  46. Klawinski D, Indelicato DJ, Hossain J, Sandler E. Surveillance imaging in pediatric ependymoma. *Pediatr Blood Cancer*. 2020;67(11):e28622. doi:10.1002/pbc.28622.
  47. Massimino M, Barretta F, Modena P, et al. Pediatric intracranial ependymoma: correlating signs and symptoms at recurrence with outcome in the second prospective AIEOP protocol follow-up. *J Neurooncol*. 2018;140(2):457-465. doi:10.1007/s11060-018-2974-6.
  48. Gajjar A, Mahajan A, Abdelbaki M, et al. National Comprehensive Cancer Network (NCCN) Guidelines Version 1.2023—July 12, 2022. Pediatric Central Nervous System Cancers, available at: [https://www.nccn.org/professionals/physician\\_gls/pdf/ped\\_cns.pdf](https://www.nccn.org/professionals/physician_gls/pdf/ped_cns.pdf), referenced with permission from the NCCN Clinical Practice Guidelines in Oncology (NCCN Guidelines™) for Central Nervous System Cancers V1.2023 7/12/2022. ©2022 National Comprehensive Cancer Network, Inc. All rights reserved. The NCCN Guidelines™ and illustrations herein may not be reproduced in any form for any purpose without the express written permission of the NCCN. To view the most recent and complete version of the NCCN Guidelines™, go online to [NCCN.org](https://www.nccn.org).

<b>Pediatric Lymphomas (PEDONC-5)</b>
<b>Pediatric Lymphoma – General Considerations (PEDONC-5.1)</b>
<b>Pediatric Hodgkin Lymphoma (HL) (PEDONC-5.2)</b>
<b>Pediatric Aggressive Mature B-Cell Non-Hodgkin Lymphomas (NHL) (PEDONC-5.3)</b>
<b>Anaplastic Large Cell Lymphoma (ALCL) (PEDONC-5.4)</b>

## **Pediatric Lymphoma – General Considerations (PEDONC-5.1)**

- Lymphoma mostly commonly involves the lymph nodes (LNs). However, lymphoma can also arise from primary lymphoid tissues (bone marrow or thymus) or various secondary lymphoid tissues (spleen, mucosa-associated lymphoid tissue) or non-lymphoid organs (skin, bone, brain, lungs, liver, salivary glands, etc.).
- Pediatric lymphomas are generally Hodgkin Lymphomas, Aggressive B-Cell Non-Hodgkin Lymphomas, Lymphoblastic Lymphomas, or Anaplastic Large Cell Lymphomas
- Individuals with Lymphoblastic Lymphoma (even those with bulky nodal disease) are treated using the leukemia treatment plan appropriate to the cell type (B or T cell).
  - ◆ These individuals should be imaged using guidelines in **Acute Lymphoblastic Leukemia (ALL) (PEDONC-3.2)**
- Other histologies are rare in pediatric individuals, and should be imaged according to the following guidelines:
  - ◆ Follicular lymphoma: **Follicular Lymphoma (ONC-27.3)** in the Oncology Imaging Guidelines
  - ◆ Marginal zone or MALT lymphomas: **Marginal Zone Lymphomas (ONC-27.4)** in the Oncology Imaging Guidelines
  - ◆ Mantle cell lymphomas: **Mantle Cell Lymphoma (ONC-27.5)** in the Oncology Imaging Guidelines
  - ◆ Cutaneous lymphomas: **Cutaneous Lymphomas and T Cell Lymphomas (ONC-27.8)** in the Oncology Imaging Guidelines
    - **Exception:** Cutaneous B-Lymphoblastic Lymphoma should be imaged using guidelines in **Acute Lymphoblastic Leukemia (ALL) (PEDONC-3.2)**
  - ◆ Castleman's Disease: **Castleman's Disease (Unicentric and Multicentric) (ONC-31.11)** in the Oncology Imaging Guidelines
- All CT imaging recommended in this section refers to CT with contrast only.
  - ◆ Noncontrast CT imaging has not been shown to be beneficial in the management of pediatric lymphomas
  - ◆ Given the limited utility of noncontrast CT imaging in pediatric lymphomas, MRI without or without and with contrast is recommended in place of CT for individuals who cannot tolerate CT contrast due to allergy or impaired renal function
- MRI without and with contrast of symptomatic or previously involved bony areas can be approved in known lymphoma individuals without prior plain x-ray or bone scan evaluation
  - ◆ Bone scan is inferior to MRI for evaluation of known or suspected bone metastases in lymphoma
- MRI Brain without and with contrast (CPT® 70553) is the preferred study for evaluation of suspected brain metastases in pediatric lymphoma
  - ◆ CT Head with (CPT® 70460) or without and with contrast (CPT® 70470) can be approved when MRI is contraindicated

## Pediatric Hodgkin Lymphoma (HL) (PEDONC-5.2)

Indication	Imaging Study
Initial staging	<p><u>ANY or ALL of the following may be approved:</u></p> <ul style="list-style-type: none"> <li>➤ CT Neck with contrast (CPT® 70491)</li> <li>➤ CT Chest with contrast (CPT® 71260)</li> <li>➤ CT Abdomen and Pelvis with contrast (CPT® 74177)</li> <li>➤ CT with contrast or MRI without and with contrast of any other symptomatic body area</li> <li>➤ PET/CT (CPT® 78815 or CPT® 78816)                             <ul style="list-style-type: none"> <li>◆ Can be performed prior to biopsy if necessary for individual scheduling</li> </ul> </li> <li>➤ CT or MRI of other body areas may be indicated for rare individuals based on physical findings or PET/CT results</li> </ul>
Restaging	<ul style="list-style-type: none"> <li>➤ ALL of the following, as often as every 2 cycles of chemotherapy:                             <ul style="list-style-type: none"> <li>◆ CT of previously involved visceral areas                                     <ul style="list-style-type: none"> <li>■ In individuals on treatment for recurrent or refractory Hodgkin Lymphoma, the following are indicated:   <ul style="list-style-type: none"> <li>▪ CT Neck with contrast (CPT® 70491)</li> <li>▪ CT Chest with contrast (CPT® 71260)</li> <li>▪ CT Abdomen and Pelvis with contrast (CPT® 74177)</li> </ul> </li> </ul> </li> <li>◆ MRI Brain with and without contrast (CPT® 70553) for known CNS involvement</li> </ul> </li> <li>AND</li> <li>➤ After cycles 2 and 4 of chemotherapy* and at end of therapy:                             <ul style="list-style-type: none"> <li>◆ PET/CT (CPT® 78815 or CPT® 78816)</li> <li>◆ *This restaging PET/CT may instead be performed after cycles 1 and 3 for individuals with low risk stage IA or IIA mixed cellularity Hodgkin lymphoma</li> </ul> </li> <li>➤ In addition to the above studies:                             <ul style="list-style-type: none"> <li>◆ A single follow-up PET/CT (CPT® 78815 or CPT® 78816) is indicated &gt;12 weeks after radiation therapy, if end of therapy PET/CT report documents Deauville 3, 4 or 5 FDG avidity, to confirm complete response</li> </ul> </li> </ul>
Surveillance for individuals with no history of recurrent HL	<ul style="list-style-type: none"> <li>➤ Imaging studies are only recommended when relapse is clinically suspected, because most individuals will clinically declare themselves and there is no survival advantage in pre-emptive imaging.</li> <li>➤ <b>Routine surveillance imaging is not supported in individuals without a prior history of recurrent disease.</b></li> </ul>
Surveillance, individuals with <b>recurrent</b> HL and no evidence of disease following successful treatment	<ul style="list-style-type: none"> <li>➤ ALL of the following, every 3 months for 1 year after completing therapy for recurrence:                             <ul style="list-style-type: none"> <li>◆ CT Neck with contrast (CPT® 70491)</li> <li>◆ CT Chest with contrast (CPT® 71260)</li> <li>◆ CT Abdomen and Pelvis with contrast (CPT® 74177)</li> </ul> </li> </ul>



Indication	Imaging Study
Clarify inconclusive findings on conventional imaging suspicious for recurrence AND considering biopsy to establish recurrence	<ul style="list-style-type: none"> <li>➤ PET/CT (CPT® 78815 or CPT® 78816)</li> </ul>
Clinical symptoms suggesting recurrence	<ul style="list-style-type: none"> <li>➤ MRI Brain with and without contrast (CPT® 70553) for known CNS involvement or new signs or symptoms suggesting intracranial disease AND either of the following:                             <ul style="list-style-type: none"> <li>➤ CT of the Neck (CPT® 70491) and Chest (CPT® 71260) and CT Abdomen/Pelvis (CPT® 74177) and CT of other previously involved visceral areas or currently symptomatic areas</li> <li>OR</li> <li>➤ PET/CT (CPT® 78815 or 78816)</li> </ul> </li> </ul>

**Background and Supporting Information**

- Most individuals experiencing recurrence are detected based on physical findings, and frequent CT surveillance imaging of Hodgkin Lymphoma after completion of therapy does not improve post-recurrence overall survival. The primary determinant of survival at recurrence is time to relapse, regardless of whether relapse is detected clinically or via imaging. NCCN pediatric HL guidelines recommend no pre-emptive surveillance imaging.
- Pediatric individuals have a high rate of neck involvement with Hodgkin Lymphoma
- Early treatment response evaluations involve both PET and CT as decisions about chemotherapy drug selection and radiation treatment are frequently made based on both anatomic (CT-based) and metabolic (PET/CT-based) responses.
- Indications and coding for rare circumstances where PET/MRI may be approved are found in **PET Imaging in Pediatric Oncology (PEDONC-1.4)**



## **Pediatric Aggressive Mature B-Cell Non-Hodgkin Lymphomas (NHL)** **(PEDONC-5.3)**

Indication	Imaging Study
Initial staging	<p>ANY or ALL of the following may be approved:</p> <ul style="list-style-type: none"> <li>➤ CT Neck with contrast (CPT® 70491)                             <ul style="list-style-type: none"> <li>◆ May substitute MRI Neck with and without contrast (CPT® 70543) if requested</li> </ul> </li> <li>➤ CT Chest with contrast (CPT® 71260)</li> <li>➤ CT Abdomen and Pelvis with contrast (CPT® 74177)                             <ul style="list-style-type: none"> <li>◆ May substitute MRI Abdomen without and with contrast (CPT® 74183) and MRI Pelvis without and with contrast (CPT® 72197) in place of CT Abdomen and Pelvis, if requested.</li> <li>◆ Abdominal ultrasound (CPT® 76700 or 76705) may be approved at initial presentation if CT/MRI not available.</li> </ul> </li> <li>➤ CT with contrast or MRI without and with contrast any other symptomatic body area</li> <li>➤ PET/CT (CPT® 78815 or CPT® 78816) (may be approved in addition to diagnostic CTs)</li> </ul>
Additional initial staging if symptoms or extent of disease suggest intracranial extension or metastasis	<ul style="list-style-type: none"> <li>➤ MRI Brain without and with contrast (CPT® 70553)</li> </ul>
Additional initial staging if symptoms or extent of disease suggest intraspinal extension or metastasis (back pain)	<ul style="list-style-type: none"> <li>➤ MRI of suspected spinal level involvement without and with contrast</li> </ul>
Restaging for treatment response (following initial response evaluation)	<ul style="list-style-type: none"> <li>➤ ANY OR ALL of the following, as often as every cycle of chemotherapy (~every 3 weeks):                             <ul style="list-style-type: none"> <li>◆ CT with contrast or MRI without and with contrast (should be same modality as initial diagnosis if possible) of previously involved areas</li> <li>◆ PET/CT (CPT® 78815) Until a negative PET is obtained                                     <ul style="list-style-type: none"> <li>■ Whole-body PET/CT (CPT® 78816) may be approved if there is clinical suspicion of, or known, skull or distal lower extremity involvement.</li> <li>■ PET/CT may be approved in conjunction with diagnostic CTs, PET/CT should not replace imaging with contrast-enhanced diagnostic-quality CT or MRI.</li> </ul> </li> </ul> </li> </ul>
Restaging for all subsequent treatment response, including end of therapy evaluation, after negative PET/CT (either Deauville or Lugano 1, 2 or 3 as reported in formal radiology interpretation)	<ul style="list-style-type: none"> <li>➤ CT with contrast or MRI without and with contrast (should be same modality as initial diagnosis if possible) of previously involved areas, as often as every 2 cycles of chemotherapy, and at the end of therapy</li> </ul>

Indication	Imaging Study
Assessment of disease activity in inconclusive residual masses seen on conventional imaging	➤ PET/CT (CPT® 78815 or CPT® 78816)
Individuals being treated with Rituximab who present with abdominal pain, due to risk of bowel perforation and obstruction	➤ CT Abdomen/Pelvis with contrast (CPT® 74177) ◆ US, x-ray, or other red flags are not required prior to CT
Surveillance of asymptomatic individuals with residual masses in the chest or abdomen and pelvis	➤ Chest x-ray and Abdominal (CPT® 76700) and Pelvic (CPT® 76856) ultrasound 3 months after completion of therapy. If stable, no further imaging is indicated.
Clinical symptoms or laboratory findings suggesting recurrence	➤ MRI Brain with and without contrast (CPT® 70553) for history of CNS involvement or new signs or symptoms suggesting intracranial disease <u>And:</u> ➤ CT of the Neck (CPT® 70491) <b>and</b> Chest (CPT® 71260) <b>and</b> CT Abdomen/Pelvis (CPT® 74177) <b>and</b> CT with contrast of other previously involved visceral areas or currently symptomatic areas ◆ PET/CT (CPT® 78815 or CPT® 78816) may be approved if relapse is suspected based on CT scan findings
Suspected PTLD recurrence with documentation of new palpable nodes, rising LDH, or rising quantitative EBV PCR	➤ PET/CT (CPT® 78815 or CPT® 78816)
Clarify inconclusive findings on conventional imaging to evaluate the need for biopsy to establish recurrence	➤ PET/CT (CPT® 78815 or CPT® 78816)

### Background and Supporting Information

- Aggressive mature B-Cell NHL includes all of the following diagnoses, all of which should be imaged according to this section:
  - ◆ Burkitt's lymphoma/leukemia (BL)
  - ◆ Diffuse Large B-Cell Lymphoma (DLBCL)
  - ◆ Primary Mediastinal Large B-Cell Lymphoma (PMBCL)
  - ◆ Post-transplant Lymphoproliferative Disorder (PTLD)
    - Most commonly occurs following solid organ or stem cell transplantation
  - ◆ Viral-associated lymphoproliferative disorders
    - Most commonly occurs following hematopoietic stem cell transplantation or in individuals with primary immunodeficiency
- Initial treatment is usually 7 days of low intensity therapy, with early response evaluation determining next steps in therapy using CT with contrast or MRI without and with contrast of previously involved areas performed around day 6
  - ◆ Individuals are customarily still inpatient for this evaluation so outpatient requests should be rare for this time point

- Routine asymptomatic surveillance with advanced imaging has not been found to impact individual outcomes as the majority of these individuals present clinically at relapse due to the highly aggressive nature of these lymphomas
- Indications and coding for rare circumstances where PET/MRI may be approved are found in **PET Imaging in Pediatric Oncology (PEDONC-1.4)**

### **Anaplastic Large Cell Lymphoma (ALCL) (PEDONC-5.4)**

Indication	Imaging Study
Initial staging	<ul style="list-style-type: none"> <li>➤ ANY OR ALL of the following may be approved:</li> <li>➤ CT of the Neck/Chest/Abdomen/Pelvis (CPT® 70491, CPT® 71260, and CPT® 74177)</li> <li>➤ MRI without and with contrast of affected area                             <ul style="list-style-type: none"> <li>◆ May be substituted for CT in cases of paraspinal or soft tissue extremity primary tumors</li> </ul> </li> <li>➤ CT with contrast or MRI without and with contrast any other symptomatic body area</li> <li>➤ PET/CT (CPT® 78815 or CPT® 78816)</li> </ul>
Additional initial staging for individuals with bony primary tumors or metastatic disease	<ul style="list-style-type: none"> <li>➤ Bone scan (See: <b><u>Modality General Considerations (PEDONC-1.3)</u></b>)</li> </ul>
Restaging at the end of induction chemotherapy (commonly 4 to 6 weeks)	<ul style="list-style-type: none"> <li>➤ CT with contrast or MRI without and with contrast of previously involved areas (should be same modality as initial diagnosis if possible)</li> </ul>
Treatment response in individuals treated with cytotoxic chemotherapy	<ul style="list-style-type: none"> <li>➤ <u>Every 2 cycles:</u> <ul style="list-style-type: none"> <li>◆ CT of previously involved areas                                     <ul style="list-style-type: none"> <li>■ If CT is performed for primary treatment response, PET/CT (CPT® 78815 or 78816) can be approved to clarify inconclusive findings detected on conventional imaging</li> </ul> </li> </ul> </li> <li>OR</li> <li>◆ PET/CT Until a negative PET is obtained                             <ul style="list-style-type: none"> <li>■ If PET/CT (CPT® 78815 or 78816) is performed for primary treatment response, CT or MRI can be approved to clarify inconclusive findings detected on PET imaging</li> </ul> </li> </ul>
Restaging after negative PET/CT (either Deauville or Lugano 1, 2 or 3 as reported in formal radiology interpretation)	<ul style="list-style-type: none"> <li>➤ CT with contrast of previously involved areas</li> </ul>
Surveillance	<ul style="list-style-type: none"> <li>➤ CT with contrast or MRI without and with contrast of all previously involved areas is indicated at 3, 6, 12, and 18 months after therapy is completed.</li> </ul>
Additional surveillance for individuals with bony primary tumors or metastatic disease	<ul style="list-style-type: none"> <li>➤ Bone scan (See: <b><u>Modality General Considerations (PEDONC-1.3)</u></b> for coding) is indicated at 3, 6, 12, and 18 months after therapy is completed</li> </ul>
Clinical symptoms suggesting recurrence	<ul style="list-style-type: none"> <li>➤ CT of the Neck (CPT® 70491), Chest (CPT® 71260), Abdomen and Pelvis (CPT® 74177) and other previously involved or currently symptomatic areas</li> </ul>

Indication	Imaging Study
Clarify inconclusive findings on conventional imaging to evaluate the need for biopsy to establish recurrence	➤ PET/CT (CPT® 78815 or CPT® 78816)

### Background and Supporting Information

- Similar in presentation to Hodgkin Lymphoma, and may be indistinguishable until immunocytology and molecular studies are complete.
- Indications and coding for rare circumstances where PET/MRI may be approved are found in **PET Imaging in Pediatric Oncology (PEDONC-1.4)**

### References

- Davies K, Barth M, Armenian S, et al. National Comprehensive Cancer Network (NCCN) Guidelines Version 1.2022—April 11, 2022, Pediatric Aggressive Mature B-Cell Lymphomas, available at: [https://www.nccn.org/professionals/physician\\_gls/pdf/ped\\_b-cell.pdf](https://www.nccn.org/professionals/physician_gls/pdf/ped_b-cell.pdf), Referenced with permission from the NCCN Clinical Practice Guidelines in Oncology (NCCN Guidelines™) for Pediatric Aggressive Mature B-Cell Lymphomas V1.2022 4/11/2022. ©2022 National Comprehensive Cancer Network, Inc. All rights reserved. The NCCN Guidelines™ and illustrations herein may not be reproduced in any form for any purpose without the express written permission of the NCCN. To view the most recent and complete version of the NCCN Guidelines™, go online to NCCN.org.
- Metzger ML, Krasin MJ, Choi JK, et al. Hodgkin lymphoma. In: Pizzo PA, Poplack DG, eds. Principles and Practice of Pediatric Oncology. 7th ed. Philadelphia, PA: Wolters Kluwer; 2016:568-586.
- Allen CE, Kamdar KY, Bollard CM, et al. Malignant Non-Hodgkin lymphomas in Children. In: Pizzo PA, Poplack DG, eds. Principles and Practice of Pediatric Oncology. 7th ed. Philadelphia, PA: Wolters Kluwer; 2016:587-603.
- Hayashi RJ, Wistinghausen B, Shiramizu B. Lymphoproliferative Disorders and Malignancies Related To Immunodeficiencies. In: Pizzo PA, Poplack DG, eds. Principles and Practice of Pediatric Oncology. 7th ed. Philadelphia, PA: Wolters Kluwer; 2016:604-616.
- Alexander S, Ferrando AA. Pediatric lymphoma. In: Orkin SH, Fisher DE, Ginsburg D, Look AT, Lux SE, Nathan DG, eds. Nathan and Oski's Hematology and Oncology of Infancy and Childhood. 8th ed. Philadelphia, PA: Elsevier Saunders; 2015:1626-1671.
- Lee Chong A, Grant RM, Ahmed BA, Thomas KE, Connolly BL, Greenberg M. Imaging in pediatric patients: time to think again about surveillance. *Pediatr Blood Cancer*. 2010;55(3):407-413. doi:10.1002/pbc.22575.
- Uslu L, Doing J, Link M, Rosenberg J, Quon A, Daldrup-Link H. Value of 18F-FDG-PET and PET/CT for evaluation of pediatric malignancies. *J Nucl Med*. 2015;56(2):274-286. doi:10.2967/jnumed.114.146290.
- Ceppi F, Pope E, Ngan B, Abila O. Primary cutaneous lymphomas in children and adolescents. *Pediatr Blood Cancer*. 2016;63(11):1886-1894. doi:10.1002/pbc.26076.
- Flerlage JE, Kelly KM, Beishuizen A, et al. Staging evaluation and response criteria harmonization (SEARCH) for childhood, adolescent, and young adult Hodgkin Lymphoma (CAYAHL): Methodology statement. *Pediatr Blood Cancer*. 2017;64(7):e26421. doi:10.1002/pbc.26421.
- Friedman DL, Chen L, Wolden S, et al. Dose-intensive response-based chemotherapy and radiation therapy for children and adolescents with newly diagnosed intermediate-risk Hodgkin lymphoma: a report from the Children's Oncology Group Study AHOD0031. *J Clin Oncol*. 2014;32(32):3651-3658. doi:10.1200/JCO.2013.52.5410.
- Schwartz CL, Chen L, McCarten K, et al. Childhood Hodgkin International Prognostic Score (CHIPS) predicts event-free survival in Hodgkin lymphoma: a report from the Children's Oncology Group. *Pediatr Blood Cancer*. 2017;64(4):e26278. doi:10.1002/pbc.26278.
- Friedmann AM, Wolfson JA, Hudson MM, et al. Relapse after treatment of Hodgkin lymphoma: outcome and role of surveillance after therapy. *Pediatr Blood Cancer*. 2013;60(9):1458-1463. doi:10.1002/pbc.24568.
- Mauz-Körholz C, Metzger ML, Kelly KM, et al. Pediatric Hodgkin lymphoma. *J Clin Oncol*. 2015;33(27):2975-2985. doi:10.1200/JCO.2014.59.4853.
- Voss SD, Chen L, Constine LS, et al. Surveillance computed tomography imaging and detection of relapse in intermediate- and advanced-stage pediatric Hodgkin's lymphoma: A report from the Children's Oncology Group. *J Clin Oncol*. 2012;30(21):2635-2640. doi:10.1200/JCO.2011.40.7841.
- Voss SD. Surveillance Imaging in Pediatric Hodgkin Lymphoma. *Curr Hematol Malig Rep*. 2013;8(3):218-225. doi:10.1007/s11899-013-0168-z.

16. Appel BE, Chen L, Buxton AB, et al. Minimal treatment of low-risk, pediatric lymphocyte-predominant Hodgkin lymphoma: a report from the Children's Oncology Group. *J Clin Oncol.* 2016;34(20):2372-2379. doi:10.1200/JCO.2015.65.3469.
17. Rosolen A, Perkins SL, Pinkerton CR, et al. Revised international pediatric non-Hodgkin lymphoma staging system. *J Clin Oncol.* 2015;33:2112-2118. doi:10.1200/JCO.2014.59.7203.
18. Sandlund JT, Guilleman RP, Perkins SL, et al. International pediatric Non-Hodgkin lymphoma response criteria. *J Clin Oncol.* 2015;33(18):2106-2111. doi:10.1200/JCO.2014.59.0745.
19. Eissa HM, Allen CE, Kamdar K, et al. Pediatric Burkitt's lymphoma and Diffuse B-cell lymphoma: are surveillance scans required? *Pediatr Hematol Oncol.* 2014;31(3):253-257. doi:10.3109/08880018.2013.834400.
20. Minard-Colin V, Brugieres L, Reiter A, et al. Non-Hodgkin lymphoma in children and adolescents: progress through effective collaboration, current knowledge, and challenges ahead. *J Clin Oncol.* 2015;33(27):2963-2974. doi:10.1200/JCO.2014.59.5827.
21. Dierickx D, Tousseym T, and Gheysens O. How I treat posttransplant lymphoproliferative disorders. *Blood.* 2015;126(20):2274-2283. doi:10.1182/blood-2015-05-615872.
22. Vali R, Punnett A, Bajno L, Moineddin R, Shammas A. The value of 18F-FDG PET in pediatric patients with post-transplant lymphoproliferative disorder at initial diagnosis. *Pediatr Transplant.* 2015;19(8):932-939. doi:10.1111/ptr.12611.
23. Haggood G and Savage KJ. The biology and management of systemic anaplastic large cell lymphoma. *Blood.* 2015;126(1):17-25. doi:10.1182/blood-2014-10-567461.
24. Kempf W, Kazakov DV, Belousova IE, Mitteldorf C, Kerl K. Pediatric cutaneous lymphomas: a review and comparison with adult counterparts. *J Eur Acad Dermatol Venereol.* 2015;29(9):1696-1709. doi:10.1111/jdv.13044.
25. Hochberg J, Flower A, Brugieres L, Cairo MS. NHL in adolescents and young adults: a unique population. *Pediatr Blood Cancer.* 2018;65:e27073. doi.org/10.1002/pbc.27073.
26. Buhtoiarov IN. Pediatric lymphoma. *Pediatr In Rev.* 2017;38(9):410-423. doi:10.1542/pir.2016-0152.
27. Flerlage JE, Hinikier SM, Armenian SO, et al. National Comprehensive Cancer Network (NCCN) Guidelines Version 1.2022—April 8, 2022, Pediatric Hodgkin Lymphoma, available at: [https://www.nccn.org/professionals/physician\\_gls/pdf/ped\\_hodgkin.pdf](https://www.nccn.org/professionals/physician_gls/pdf/ped_hodgkin.pdf), Referenced with permission from the NCCN Clinical Practice Guidelines in Oncology (NCCN Guidelines™) for Pediatric Hodgkin Lymphoma V1.20224/8/2022. ©2022 National Comprehensive Cancer Network, Inc. All rights reserved. The NCCN Guidelines™ and illustrations herein may not be reproduced in any form for any purpose without the express written permission of the NCCN. To view the most recent and complete version of the NCCN Guidelines™, go online to NCCN.org.
28. Kaste SC. Imaging of pediatric cutaneous melanoma. *Pediatric Radiology.* 2019;49:1476-1487. doi:10.1007/s00247-019-04374-9.

<b>Neuroblastoma (PEDONC-6)</b>
<b>Neuroblastoma – General Considerations (PEDONC-6.1)</b>
<b>Staging and Risk Grouping – Neuroblastoma (PEDONC-6.2)</b>
<b>Neuroblastoma – Initial Staging (PEDONC-6.3)</b>
<b>Neuroblastoma – Treatment Response Imaging (Risk Group Dependent) (PEDONC-6.4)</b>
<b>Neuroblastoma – Surveillance Imaging (Risk Group Dependent) (PEDONC-6.5)</b>

## **Neuroblastoma – General Considerations (PEDONC-6.1)**

- **PEDONC-6** should be used to review neuroblastoma in individuals of all ages, with the exception of esthesioneuroblastoma in individuals of all ages, which should be reviewed using **ONC-3**.
- Neuroblastoma is divided into very low, low, intermediate, and high-risk disease based on International Neuroblastoma Risk Group (INRG) Staging System (see: **Staging and Risk Grouping (PEDONC-6.2)**). The treatment approaches for each risk group vary widely and have distinct imaging strategies. The risk group for a given individual should be provided by the ordering provider in the clinical information provided for review.
- For metabolic imaging in individuals who are MIBG positive at diagnosis and then become MIBG negative in response to treatment:
  - ◆ Continue to use MIBG (see: table below and **PEDONC-1.3** for coding)

Study Type	Coding
Bone scan	<ul style="list-style-type: none"> <li>➤ Any of the following codes can be approved:                             <ul style="list-style-type: none"> <li>◆ CPT® 78300</li> <li>◆ CPT® 78305</li> <li>◆ CPT® 78306</li> <li>◆ CPT® 78803, 78830, or 78832                                     <ul style="list-style-type: none"> <li>■ May be approved alone or in combination with:   <ul style="list-style-type: none"> <li>▪ CPT® 78305</li> <li>▪ CPT® 78306</li> </ul> </li> </ul> </li> </ul> </li> </ul>
<sup>123</sup> I-metaiodobenzylguanidine (MIBG) scintigraphy	<ul style="list-style-type: none"> <li>➤ Any one of the following codes can be approved:                             <ul style="list-style-type: none"> <li>◆ CPT® 78801</li> <li>◆ CPT® 78802</li> <li>◆ CPT® 78804</li> </ul> </li> <li>➤ Any one of the following codes may also be approved, individual or in combination with CPT® 78801, 78802 or 78804                             <ul style="list-style-type: none"> <li>◆ CPT® 78803</li> <li>◆ CPT® 78830</li> <li>◆ CPT® 78831</li> <li>◆ CPT® 78832</li> <li>◆ CPT® 78800 may be approved for KNOWN neuroblastoma when only a single site follow up is desired but is not sufficient for the initial workup of suspected disease.</li> </ul> </li> </ul>
Octreotide scan	<ul style="list-style-type: none"> <li>➤ Same coding as MIBG</li> </ul>
Gallium scan	<ul style="list-style-type: none"> <li>➤ Same coding as MIBG</li> </ul>

- MIBG remains the standard of care metabolic imaging in neuroblastoma, 18F-FDG-PET-CT is not supported unless one of the exceptions below is present. All other radiotracers are considered investigational at this time:

Indication	Imaging Study
<ul style="list-style-type: none"> <li>➤ Any of the following:                             <ul style="list-style-type: none"> <li>◆ Individuals with MIBG-negativity documented at initial diagnosis</li> <li>◆ At major decision points (such as hematopoietic stem cell transplant or surgery), if MIBG and CT/MRI findings are inconclusive</li> </ul> </li> </ul>	<ul style="list-style-type: none"> <li>➤ Whole-body 18F-FDGPET/CT (CPT® 78816)</li> <li>➤ In scenarios where PET/CT is supported, it does not preclude the other diagnostic imaging studies supported throughout PEDONC 6 . PET/CT is viewed as replacing MIBG in these scenarios. Indications and coding for rare circumstances where PET/MRI may be approved are found in <b><u>PET Imaging in Pediatric Oncology (PEDONC-1.4)</u></b></li> </ul>
<ul style="list-style-type: none"> <li>➤ Individuals currently receiving medications that may interfere with MIBG uptake that cannot be safely discontinued prior to imaging, including:                             <ul style="list-style-type: none"> <li>◆ Tricyclic antidepressants (amitriptyline, imipramine, etc.)</li> <li>◆ Selective serotonin reuptake inhibitors (SSRI's, sertraline, paroxetine, escitalopram, etc.)</li> <li>◆ Neuroleptics (risperidone, haloperidol, etc.)</li> <li>◆ Antihypertensive drugs (alpha or beta blockers, calcium channel blockers)</li> <li>◆ Decongestants (phenylephrine, ephedrine, pseudoephedrine)</li> <li>◆ Stimulants (methylphenidate, dextroamphetamine, etc.)</li> </ul> </li> </ul>	<ul style="list-style-type: none"> <li>➤ PET/CT (CPT® 78816) should only be approved for this indication when specific documentation of the medication interaction is included with the current PET imaging request.</li> <li>➤ Indications and coding for rare circumstances where PET/MRI may be approved are found in <b><u>PET Imaging in Pediatric Oncology (PEDONC-1.4)</u></b></li> </ul>

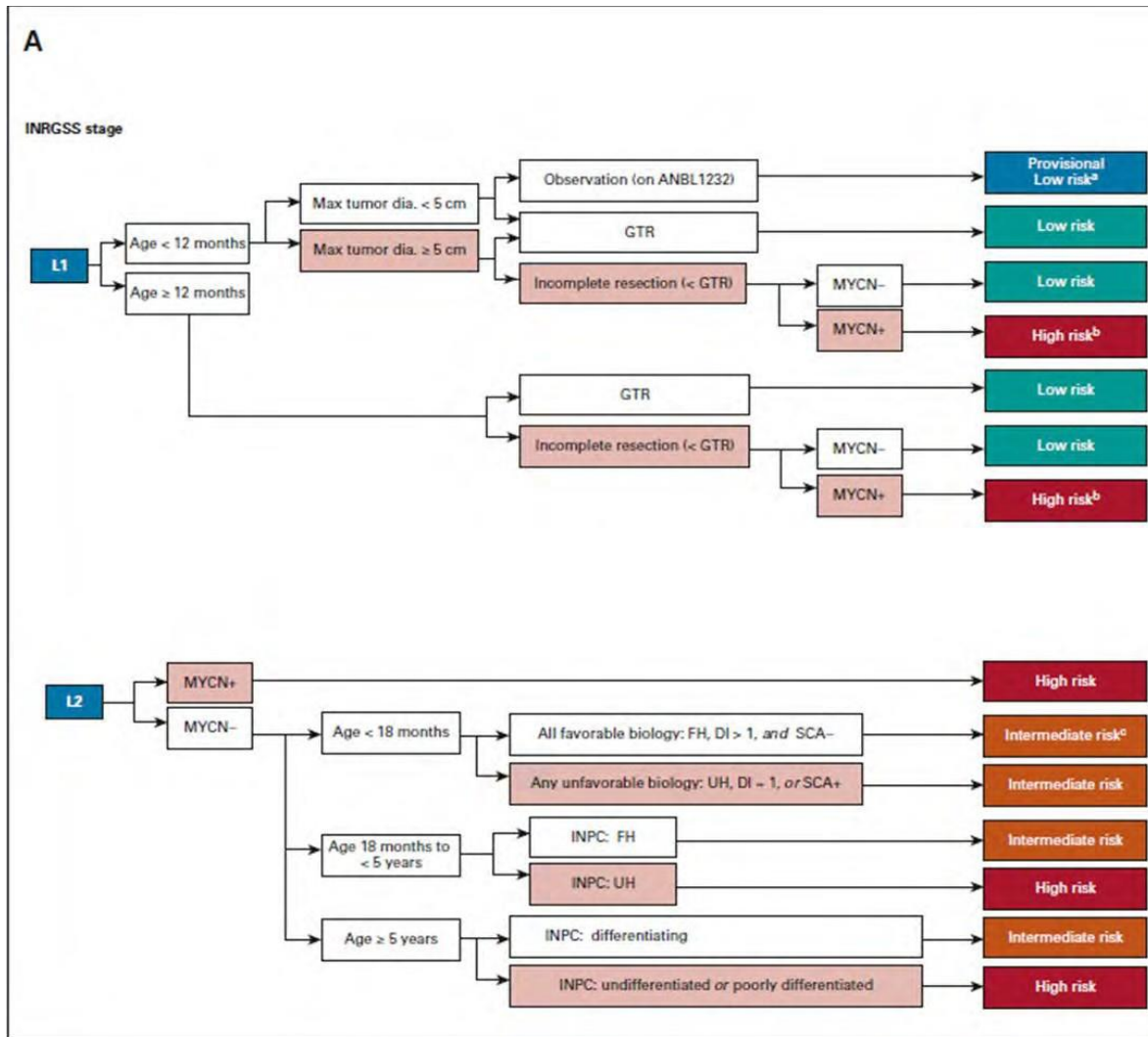
### Background and Supporting Information

- Neuroblastoma is the most common extracranial solid tumor of childhood, and generally arises from the adrenal gland or along the sympathetic chain. Neuroblastoma staging has recently changed to better incorporate the prognostic impact of biological and genetic characteristics, particularly segmental chromosome aberrations (SCA) as an additional genomic marker. SCAs of 1p or 11g are poor prognostic indicators.
- 90% to 95% of neuroblastomas secrete homovanillic acid (HVA) and vanillylmandelic acid (VMA) in the urine, and urine HVA/VMA should be performed at every disease evaluation for individuals with positive HVA or VMA at diagnosis
- 99mTc-MDP bone scan does not identify foci of disease that affect staging or clinical management and provides no advantage over MIBG scintigraphy and is not used for evaluation of most individuals with neuroblastoma

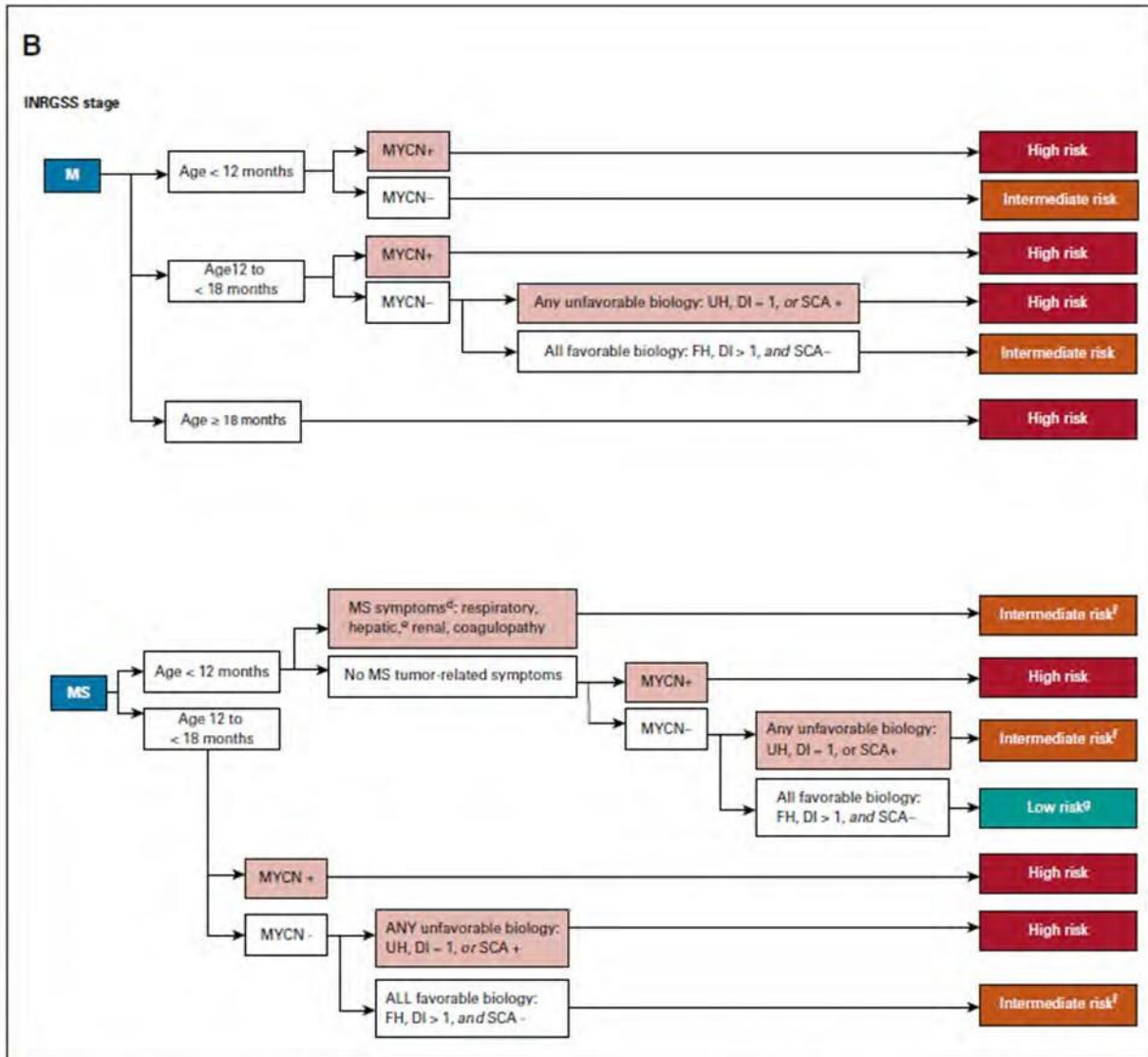


## **Staging and Risk Grouping – Neuroblastoma (PEDONC-6.2)**

- Most recent treatment protocols are using the updated International Neuroblastoma Risk Group (INRG) staging system
  - ◆ L1: Localized tumor not involving vital structures as defined by the list of image-defined risk factors and confined to one body compartment
    - Image-defined risk factors include a list of specific imaging findings defining individuals less likely to be candidates for complete surgical resection
    - These risk factors involve the encasement of major blood vessels, airway, skull base, costovertebral junction, brachial plexus, spinal canal, or major organs or structures
  - ◆ L2: Locoregional tumor with presence of one or more image-defined risk factors
  - ◆ M: Distant metastatic disease (except stage MS)
  - ◆ MS: Metastatic disease in children younger than 18 months with metastases confined to skin, liver, and/or bone marrow with <10% involvement (MIBG must be negative in bone and bone marrow)
- The tables for risk grouping are provided below for reference. The risk group for any given individual should be provided or documented by the requesting provider.



**FIG 1.** Risk classifier v2 algorithm for patients with (A) locoregional and (B) metastatic tumors. (A) Patients with locoregional tumors with neuroblastoma and ganglioneuroblastoma (nodular) are classified based on INRG stage (L1 and L2), age, resection, biomarkers (*MYCN*, ploidy and SCAs), and INPC. Select patients with all favorable features are eligible for surveillance on the current non-high-risk COG ANBL1232 protocol. L1 or L2 tumors with histopathology diagnostic category of ganglioneuroma or ganglioneuroblastoma-intermixed will be classified as low-risk regardless of biomarkers (and thus are not included in the figure). Ages are broken down by < 18 months, 18 months to < 5 years, and ≥ 5 years based on age categories used by INPC. <sup>a</sup>If tumor progresses during observation, biopsy or resect and reclassify with biomarkers (as in COG ANBL1232). <sup>b</sup>Consider complete resection if feasible. <sup>c</sup>If no tumor burden symptoms, consider observation (as in COG ANBL1232). (B) Patients with metastatic tumors are classified by stage (M and MS), age, INPC, and biomarkers. For MS patients, presence or absence of symptoms may influence therapy independent of biomarker status. In previous risk classifiers, missing data were considered as unfavorable. In COG v2, missing data for SCA will not be considered as unfavorable based on the low incidence of SCA in otherwise favorable subsets. (continued on following page)



**FIG 1.** (Continued). <sup>a</sup>Biopsy contraindicated, defer biopsy until stable (note: biomarker results may modify Risk Class). <sup>b</sup>Hepatomegaly alone is an MS symptom in patients age < 3 months of age (see COG ANBL1232). <sup>c</sup>Response-based therapy (as in COG ANBL1232). <sup>d</sup>MS score-based therapy (as in COG ANBL1232). COG, Children's Oncology Group; DI, DNA index; dia., diameter; FH, favorable histology; GTR, gross-total resection; INPC, International Neuroblastoma Pathology Classifier; INRG, International Neuroblastoma Risk Group; MYCN+, MYCN amplified; MYCN-, MYCN not amplified; SCA, segmental chromosomal aberration; UH, unfavorable histology; v1, version 1; v2, version 2.

## **Neuroblastoma – Initial Staging (PEDONC-6.3)**

**The following imaging studies should be considered appropriate in the initial staging of individuals with Neuroblastoma:**

Indication	Imaging Study
Initial staging for all individuals	<ul style="list-style-type: none"> <li>➤ <sup>123</sup>I-metaiodobenzylguanidine (see table in <b><u>Neuroblastoma – General Considerations (PEDONC-6.1)</u></b> for MIBG coding details) scintigraphy</li>   <li>AND</li> <li>➤ <u>ONE of the following sets of imaging:</u> <ul style="list-style-type: none"> <li>◆ CT Neck/Chest/Abdomen/Pelvis with contrast (CPT® 70491, CPT® 71260, and CPT® 74177) OR</li> <li>◆ MRI Neck/Chest/Abdomen/Pelvis without and with contrast (CPT® 70543, CPT® 71552, CPT® 74183, and CPT® 72197)</li> </ul> </li> </ul>
Evaluation of paraspinal tumors where cord compression is a possibility	➤ MRI without and with contrast of the appropriate spinal level
Evaluation of suspected adrenal neuroblastoma, ganglioneuroblastoma, or ganglioneuroma when CT or MRI is inconclusive for an adrenal lesion.	➤ Adrenal nuclear imaging (CPT® 78075)
Clinical signs/symptoms suggest brain involvement	➤ MRI Brain without and with contrast (CPT® 70553)

- PET should not be used unless one of the exceptions stated in section **Neuroblastoma – General Considerations (PEDONC-6.1)** is present

### ***Background and Supporting Information***

- MIBG provides superior sensitivity and sensitivity for detecting viable osseous disease compared with bone scintigraphy so technetium bone scan is not necessary when MIBG is utilized. MIBG is positive in 90% to 95% of neuroblastomas.
- Most MIBG imaging studies are SPECT/CT studies using CT for localization only. Separate diagnostic CT codes should not be approved for this purpose
- Occasionally MIBG cannot be performed prior to initiation of therapy. In this circumstance, MIBG should be completed within 3 weeks of therapy initiation as the reduction in MIBG avidity in response to chemotherapy is not immediate. Inability to complete MIBG before starting therapy is not an indication to approve PET imaging
- MRI Brain of asymptomatic individuals with no history of brain metastases is not indicated for neuroblastoma but may be approved for signs and symptoms of brain involvement.

## **Neuroblastoma – Treatment Response Imaging (Risk Group Dependent) (PEDONC-6.4)**

- Risk Grouping will not be known at the time of initial staging, but is critical for all imaging decisions after initial staging is complete. **The treating oncologist should always know the individual’s risk grouping.** It is not possible to establish the appropriate imaging plan for a neuroblastoma individual without knowing his/her risk group. All Very Low Risk and Low Risk Neuroblastoma Not Receiving Chemotherapy:

Indication	Imaging Study
All individuals, 6 to 8 weeks after diagnosis to determine if additional treatment is necessary	<ul style="list-style-type: none"> <li>➤ CT with contrast or MRI without and with contrast of the primary tumor site                             <ul style="list-style-type: none"> <li>◆ Ultrasound may be used in place of CT or MRI to avoid radiation and/or anesthesia exposure in low risk individuals</li> </ul> </li> </ul>

### ***Background and Supporting Information***

- Many individuals will be treated with surgical resection only without adjuvant therapy, and these individuals enter immediately into surveillance.

## **All Intermediate Risk Neuroblastoma and Very Low Risk or Low Risk Neuroblastoma Receiving Chemotherapy:**

Indication	Imaging Study
Prior to surgical resection	<ul style="list-style-type: none"> <li>➤ Restaging imaging (MIBG and CT or MRI, as performed at initial diagnosis)</li> </ul>
Treatment response, as often as every 2 cycles of chemotherapy (~every 6 weeks and at the end of planned treatment)	<ul style="list-style-type: none"> <li>➤ CT Chest/Abdomen/Pelvis with contrast (CPT® 71260, and CPT® 74177)</li> <li>OR</li> <li>➤ MRI Chest/Abdomen/Pelvis without and with contrast, (CPT® 71552, CPT® 74183, and CPT® 72197)</li> <li>AND</li> <li>➤ CT or MRI of other sites with prior measurable disease</li> </ul>
In addition to treatment response listed above, every 4 cycles, and at the end of planned chemotherapy treatment	<ul style="list-style-type: none"> <li>➤ MIBG scan (see table in <b><u>Neuroblastoma – General Considerations (PEDONC-6.1)</u></b> for MIBG coding details)</li> </ul>

### ***Background and Supporting Information***

- Individuals generally receive 2 to 12 cycles of moderate-intensity chemotherapy depending on response to treatment.

- Surgical resection may occur prior to or following chemotherapy depending on disease stage. Restaging prior to surgery is appropriate.

### **High-Risk Neuroblastoma:**

Indication	Imaging Study
<ul style="list-style-type: none"> <li>➤ <b>ANY of the following:</b> <ul style="list-style-type: none"> <li>◆ Treatment response                             <ul style="list-style-type: none"> <li>■ As often as every 2 cycles of chemotherapy, mAb, or biologic therapy (~every 6 weeks)</li> </ul> </li> <li>◆ Change in modality                             <ul style="list-style-type: none"> <li>■ Prior to surgery, HSCT, XRT, or mAb therapy</li> </ul> </li> <li>◆ End of therapy</li> </ul> </li> </ul>	<ul style="list-style-type: none"> <li>➤ CT with contrast, of the Chest/Abdomen/Pelvis (CPT® 71260, and CPT® 74177)</li> <li>OR</li> <li>➤ MRI without and with contrast, (CPT® 71552, CPT® 74183, and CPT® 72197)</li> <li>AND</li> <li>➤ CT or MRI of other sites with prior measurable disease</li> <li>➤ MIBG scan (see table in <b><u>Neuroblastoma – General Considerations (PEDONC-6.1)</u></b> for MIBG coding details)</li> </ul>
At completion of <sup>131</sup> I-MIBG therapy	<ul style="list-style-type: none"> <li>➤ <sup>123</sup>I-MIBG scan                             <ul style="list-style-type: none"> <li>◆ FDG-PET cannot be used after <sup>131</sup>I-MIBG therapy</li> </ul> </li> </ul>
Preoperative planning	<ul style="list-style-type: none"> <li>➤ More frequent imaging with any of the above modalities can be approved around the time of surgery if needed</li> </ul>

### **Background and Supporting Information**

- This group of individuals receives highly aggressive therapy using sequential chemotherapy, surgery, high dose chemotherapy with stem cell rescue, radiotherapy, monoclonal antibody (mAb) immunotherapy, and biologic therapy.

### **Neuroblastoma – Surveillance Imaging (Risk Group Dependent) (PEDONC-6.5)**

#### **Very Low Risk and Low Risk Neuroblastoma:**

Indication	Imaging Study
All individuals	<ul style="list-style-type: none"> <li>➤ CT with contrast or MRI without and with contrast of the primary tumor site 3, 6, 9, 12, 18, 24, and 36 months after surgery.                             <ul style="list-style-type: none"> <li>◆ If negative at 36 months, no further advanced imaging is necessary.</li> </ul> </li> </ul>
Clarification of findings on CT or MRI suspicious for disease recurrence	<ul style="list-style-type: none"> <li>➤ MIBG (see table in <b><u>Neuroblastoma – General Considerations (PEDONC-6.1)</u></b> for MIBG coding details)</li> </ul>

### Intermediate Risk Neuroblastoma:

Indication	Imaging Study
All individuals	<ul style="list-style-type: none"> <li>➤ CT with contrast or MRI without and with contrast of the primary tumor site and known metastatic sites at 3, 6, 9, 12, 18, 24, and 36 months after completion of therapy.                             <ul style="list-style-type: none"> <li>◆ If negative at 36 months, no further advanced imaging is necessary.</li> <li>◆ Ultrasound may be sufficient to evaluate the primary tumor site for certain individuals and may be approved if requested to replace CT or MR</li> </ul> </li> </ul>
<ul style="list-style-type: none"> <li>➤ <b>BOTH</b> of the following:                             <ul style="list-style-type: none"> <li>◆ Individuals with stage 4, or M disease, or 4S, or MS disease AND</li> <li>◆ Positive MIBG at completion of therapy</li> </ul> </li> </ul>	<ul style="list-style-type: none"> <li>➤ MIBG scan (see table in <b><u>Neuroblastoma – General Considerations (PEDONC-6.1)</u></b> for MIBG coding details) at 3, 6, 9, 12, 24, and 36 months after completion of therapy.                             <ul style="list-style-type: none"> <li>◆ If negative at 36 months, no further MIBG imaging is necessary.</li> </ul> </li> <li>➤ MIBG (or PET, if MIBG-negative at initial diagnosis) not indicated for all other intermediate risk individuals</li> </ul>

### High-Risk Neuroblastoma:

Indication	Imaging Study
All individuals	<ul style="list-style-type: none"> <li>➤ CT with contrast or MRI without and with contrast of the primary tumor site at 3, 6, 9, 12, 18, 24, 30, 36, 42, 48, 54, and 60 months, then annually until 10 years after completion of therapy.                             <ul style="list-style-type: none"> <li>◆ If negative at 10 years, no further advanced imaging is necessary.</li> </ul> </li> <li>➤ MIBG scan (see table in <b><u>Neuroblastoma – General Considerations (PEDONC-6.1)</u></b> for MIBG coding details) at 3, 6, 9, 12, 18, 24, 30, and 36 months after completion of therapy.                             <ul style="list-style-type: none"> <li>◆ If negative at 36 months, no further MIBG or PET imaging is necessary.</li> </ul> </li> </ul>
Suspected recurrence	<ul style="list-style-type: none"> <li>➤ CT Chest/Abdomen/Pelvis with contrast (CPT® 71260, and CPT® 74177) or MRI without and with contrast, (CPT® 71552, CPT® 74183, and CPT® 72197) and other sites of prior measurable disease or current symptoms</li> <li>➤ MRI Brain with and without contrast (CPT® 70553) may be approved if signs or symptoms of brain involvement</li> <li>➤ MIBG scan (see table in <b><u>Neuroblastoma – General Considerations (PEDONC-6.1)</u></b> for MIBG coding details)</li> </ul>

### Background and Supporting Information

- Very Low Risk and Low Risk Neuroblastoma:
  - ◆ Urine HVA/VMA (if positive at diagnosis) at 1, 2, 3, 6, 9, 12, 18, 24, 36, 48, and 60 months after surgery

- ◆ CT Chest is not indicated in asymptomatic surveillance imaging of any stages of neuroblastoma individuals with no prior history of thoracic disease
- Intermediate Risk Neuroblastoma:
  - ◆ Urine HVA/VMA (if positive at diagnosis) every month until 12 months after completion of therapy, then at 14, 16, 18, 21, 24, 30, and 36 months after completion of therapy, then annually until 10 years after completion of therapy
- High-Risk Neuroblastoma:
  - ◆ Early detection of recurrence with <sup>123</sup>I-MIBG has been shown to improve post-relapse outcomes in high-risk neuroblastoma
  - ◆ Urine HVA/VMA (if positive at diagnosis) at 3, 6, 9, 12, 18, 24, 30, 36, 42, 48, 54, and 60 months after completion of therapy, then annually until 10 years after completion of therapy, and for suspected recurrence.

## References

1. Brodeur GM, Hogarty MD, Bagatell R, et al. Neuroblastoma. In: Pizzo PA, Poplack DG, eds. Principles and Practice of Pediatric Oncology. 7th ed. Philadelphia, PA: Wolters Kluwer; 2016:772-797.
2. Shusterman S and George RE. Neuroblastoma. In: Orkin SH, Fisher DE, Ginsburg D, Look AT, Lux SE, Nathan DG, eds. Nathan and Oski's Hematology and Oncology of Infancy and Childhood. 8th ed. Philadelphia, PA: Elsevier Saunders; 2015:1675-1713.
3. Sharp SE, Gelfand MJ, Shulkin BL. Pediatrics: diagnosis of neuroblastoma. Semin Nucl Med. 2011;41(5):345-353. doi:10.1053/j.semnuclmed.2011.05.001.
4. Kushner BH, Kramer K, Modak S, et al. Sensitivity of surveillance studies for detecting asymptomatic and unsuspected relapse of high-risk neuroblastoma. J Clin Oncol. 2009;27(7):1041-1046. doi:10.1200/JCO.2008.17.6107.
5. Uslu L, Doing J, Link M, Rosenberg J, Quon A, Daldrup-Link HE. Value of 18F-FDG PET and PET/CT for evaluation of pediatric malignancies. J Nucl Med. 2015;56(2):274-286. doi:10.2967/jnumed.114.146290.
6. Nuchtern JG, London WB, Barnewolt CE, et al. A prospective study of expectant observation as primary therapy for neuroblastoma in young infants: A Children's Oncology Group Study. Ann Surg. 2012 October;256(4):573-580. doi:10.1097/SLA.0b013e31826cbbbd.
7. Brisse HJ, McCarville MB, Granata C, et al. Guidelines for imaging and staging of neuroblastic tumors: Consensus report from the International Neuroblastoma Risk Group Project. Radiology. 2011;261(1):243-257. doi:10.1148/radiol.11101352.
8. Monclair T, Brodeur GM, Ambros PF, et al. The International Neuroblastoma Risk Group (INRG) staging system: an INRG task force report. J Clin Oncol. 2009;27(2):298-303. doi:10.1200/JCO.2008.16.6876.
9. Cohn SL, Pearson ADJ, London WB, et al. The International Neuroblastoma Risk Group (INRG) classification system: an INRG Task Force Report. J Clin Oncol. 2009;27(2):289-297. doi:10.1200/JCO.2008.16.6785.
10. GE Healthcare. AdreView™ Iobenguane I 123 Injection prescribing information. Revised September 2008. [https://www.accessdata.fda.gov/drugsatfda\\_docs/label/2008/22290lbl.pdf](https://www.accessdata.fda.gov/drugsatfda_docs/label/2008/22290lbl.pdf)
11. Bombardieri E, Giammarile F, Aktolun C, et al. 131I/123I-Metaiodobenzylguanidine (MIBG) scintigraphy: procedure guidelines for tumor imaging. Eur J Nucl Med Mol Imaging. 2010;37(12):2436-2446. [http://snmmi.files.cms-plus.com/docs/hpra/2010\\_published\\_OC\\_131I\\_123I\\_Metaiodobenzylguanidine\\_Scintigraphy.pdf](http://snmmi.files.cms-plus.com/docs/hpra/2010_published_OC_131I_123I_Metaiodobenzylguanidine_Scintigraphy.pdf).
12. Mueller WP, Copenrath E, Pfluger T. Nuclear medicine and multimodality imaging of pediatric neuroblastoma. Pediatr Radiol. 2013;43(4):418-427. doi:10.1007/s00247-012-2512-1.
13. Sharp SE, Gelfand MJ, Shulkin BL. Pediatrics: Diagnosis of neuroblastoma. Semin Nucl Med. 2011;41(5):345-353. doi:10.1053/j.semnuclmed.2011.05.001.
14. McCarville MB. What MRI can tell us about neurogenic tumors and rhabdomyosarcoma. Pediatr Radiol. 2016;46(6):881-890. doi:10.1007/s00247-016-3572-4.
15. Pinto NR, Applebaum MA, Volchenboum SL, et al. Advances in risk classification and treatment strategies for neuroblastoma. J Clin Oncol. 2015;33(27):3008-3017. doi:10.1200/JCO.2014.59.4648.
16. Park JR, Bagatell R, Cohn SL, et al. Revisions to the International Neuroblastoma Response Criteria: A consensus statement from the National Cancer Institute clinical trials planning meeting. J Clin Oncol. 2017;35(22):2580-2587. doi:10.1200/JCO.2016.72.0177.
17. Federico SM, Brady SK, Pappo A, et al. The role of chest computed tomography (CT) as a surveillance tool in children with high risk neuroblastoma. Pediatr Blood Cancer. 2015;62(6):976-981. doi:10.1002/pbc.25400.
18. Gauguet J-M, Pace-Emerson T, Grant FD, et al. Evaluation of the utility of 99mTc-MDP bone scintigraphy versus MIBG scintigraphy and cross-sectional imaging for staging patients with neuroblastoma. Pediatr Blood Cancer. 2017;64:e26601. doi:10.1002/pbc.26601.



19. Venkatramani R, Pan H, Furman WL, et al. Multimodality treatment of pediatric esthesioneuroblastoma. *Pediatr Blood Cancer*. 2016;63(3):465-470. doi:10.1002/pbc.25817.
20. Owens C, Li BK, Thomas KE, et al. Surveillance imaging and radiation exposure, in the detection of relapsed neuroblastoma. *Pediatr Blood Cancer*. 2016;63(10):1786-1793. doi:10.1002/pbc.26099.
21. Allen-Rhoades W, Whittle SB, Rainusso N. Pediatric solid tumors of infancy: an overview. *Pediatr In Rev*. 2018;39(2):57-67. doi:10.1542/pir.2017-0057.
22. Park JR, Kreissman SG, London WB. Effect of tandem autologous stem cell transplant vs single transplant on event-free survival in patients with high-risk neuroblastoma. *JAMA*. doi:10.1001/jama.2019.11642
23. Irwin MS, Naranjo A, Zhang FF, et al. Revised neuroblastoma risk classification system: a report from the Children's Oncology Group. *J Clin Oncol*. 2021;39(29):3229-3241. doi:10.1200/JCO.21.00278.
24. Maaz AUR, O'Doherty J, Djekidel M. 68Ga-DOTATATE PET/CT for neuroblastoma staging: utility for clinical use. *J Nucl Med Technol*. 2021;49(3):265-268. doi:10.2967/jnmt.120.258939.
25. Bar-Sever Z, Biassoni L, Shulkin B, et. al. Guidelines on nuclear medicine imaging in neuroblastoma. *Eur J Nucl Med Mol Imaging*. 2018;45(11):2009-2024. doi:10.1007/s00259-018-4070-8.
26. Bleeker G, Tytgat GAM, Adam JA, Caron HN, Kremer LCM, Hoo L, Van Dalen EC, 123I-MIBG and 18F-FDG PET imaging for diagnosing neuroblastoma. *Cochrane Database of Systematic Reviews*. 2015;9. Art. No.: CD009263. doi:10.1002/14651858.CD009263.pub2.

<b>Pediatric Renal Tumors (PEDONC-7)</b>
<b>Pediatric Renal Tumors – General Considerations (PEDONC-7.1)</b>
<b>Unilateral Wilms Tumor (UWT) (PEDONC-7.2)</b>
<b>Bilateral Wilms Tumor (BWT) (PEDONC-7.3)</b>
<b>Pediatric Renal Cell Carcinoma (RCC) (PEDONC-7.4)</b>
<b>Clear Cell Sarcoma of the Kidney (CCSK) (PEDONC-7.5)</b>
<b>Malignant Rhabdoid Tumor of the Kidney (MRT) and Other Extracranial Sites (PEDONC-7.6)</b>
<b>Congenital Mesoblastic Nephroma (CMN) (PEDONC-7.7)</b>

## **Pediatric Renal Tumors – General Considerations (PEDONC-7.1)**

- Ultrasound is considered first-line imaging for suspected pediatric renal mass, given the lack of radiation exposure and need for sedation. Advanced imaging for suspected Wilms Tumor should be done after initial assessment with ultrasound, which has often been completed prior to diagnosis.
- A variety of tumors can occur in the pediatric kidney, and include the following:
  - ◆ Wilms Tumor
    - Favorable Histology (FHWT)
    - Focal Anaplasia (FAWT)
    - Diffuse Anaplasia (DAWT)
    - Bilateral Wilms Tumor (BWT)
  - ◆ Renal Cell Carcinoma (RCC)
  - ◆ Clear Cell Sarcoma of the Kidney (CCSK)
  - ◆ Malignant Rhabdoid Tumor of the Kidney (MRT)
  - ◆ Congenital Mesoblastic Nephroma (CMN)
  - ◆ Other cancers occurring in the kidney:
    - Neuroblastoma
    - Primitive Neuroectodermal Tumor
    - Rhabdomyosarcoma
    - Non-Rhabdomyosarcoma Soft Tissue Sarcomas
    - These and other rare tumors have been reported occurring primarily in the kidney and should be imaged according to the guidelines for the specific histologic diagnosis.
- For suspected renal tumor, cell type unknown, image according to **Pediatric Renal Cell Carcinoma (RCC) (PEDONC-7.4)**
- PET is not **routinely** supported for initial staging, treatment response or surveillance of any pediatric renal tumor-rare circumstances where an exception to routine may be considered are listed in the relevant guideline sections

## **Unilateral Wilms Tumor (UWT) (PEDONC-7.2)**

Indication	Imaging Study
Initial Staging	<ul style="list-style-type: none"> <li>➤ CT Abdomen with contrast (CPT® 74160)                             <ul style="list-style-type: none"> <li>◆ CT Abdomen and Pelvis with contrast (CPT® 74177) may be approved in lieu of CPT® 74160 included if mass is presumed to extend into the pelvis.                                     <ul style="list-style-type: none"> <li>■ Doppler ultrasound to evaluate for tumor thrombus is not necessary unless CT findings are inconclusive</li> </ul> </li> </ul> </li> <li>➤ CT Chest with (CPT® 71260) or without contrast (CPT® 71250)                             <ul style="list-style-type: none"> <li>◆ Should be completed prior to anesthesia exposure if possible</li> </ul> </li> <li>➤ PET is not routinely indicated in the initial staging of any pediatric renal tumor</li> </ul>
Bilateral renal lesions noted on ultrasound or CT	<ul style="list-style-type: none"> <li>➤ MRI Abdomen (CPT® 74183) and Pelvis (CPT® 72197) without and with contrast</li> </ul>

Indication	Imaging Study
Additional initial staging imaging for any individual with neurologic signs or symptoms raising suspicion of CNS metastases	<ul style="list-style-type: none"> <li>➤ MRI Brain without and with contrast (CPT® 70553)</li> </ul>
Additional initial staging imaging for any individual with signs or symptoms raising suspicion of bony metastases	<ul style="list-style-type: none"> <li>➤ Bone scan (see: <b>PEDONC-1.3</b> for coding)</li> </ul>
Treatment response ~every 2 cycles during treatment and at the end of planned therapy	<ul style="list-style-type: none"> <li>➤ CT Chest with (CPT® 71260) or without contrast (CPT® 71250)</li> <li>➤ CT Abdomen with contrast (CPT® 74160) or CT Abdomen and Pelvis with contrast (CPT® 74177) or MRI Abdomen (CPT® 74183) and Pelvis (CPT® 72197) without and with contrast</li> </ul>
Rare circumstances to establish the presence of active disease only when a major therapeutic decision depends on PET avidity	<ul style="list-style-type: none"> <li>➤ PET/CT (CPT® 78815)</li> </ul>
Surveillance, very low risk FHWT treated with nephrectomy only	<ul style="list-style-type: none"> <li>➤ At months 3, 6, 12, and 18 months after nephrectomy:                             <ul style="list-style-type: none"> <li>◆ CT Chest with contrast (CPT® 71260) or without contrast (CPT® 71250), or chest x-ray AND</li> <li>◆ CT Abdomen and Pelvis with contrast (CPT® 74177) or Abdominal and Pelvic US (CPT® 76700 +/- 76856)</li> </ul> </li> <li>➤ At months 9, 15, 21 after nephrectomy:                             <ul style="list-style-type: none"> <li>◆ Abdominal Ultrasound (CPT® 76700) AND</li> <li>◆ Chest x-ray</li> </ul> </li> <li>➤ Every 3 months, from month 24 to month 30 after nephrectomy:                             <ul style="list-style-type: none"> <li>◆ Abdominal Ultrasound (CPT® 76700) and</li> <li>◆ CXR</li> </ul> </li> <li>➤ After month 30, every 6 months up to 5 years off therapy:                             <ul style="list-style-type: none"> <li>◆ Abdominal Ultrasound (CPT® 76700)</li> </ul> </li> </ul>
Surveillance, FHWT treated with chemotherapy with or without XRT	<ul style="list-style-type: none"> <li>➤ At months 6, 12, 18, 24, 30, and 36 months after completion of all therapy:                             <ul style="list-style-type: none"> <li>◆ CT Chest with contrast (CPT® 71260) or without contrast (CPT® 71250), or CXR and</li> <li>◆ CT Abdomen with contrast (CPT® 74177), MRI Abdomen without and with contrast (CPT® 74183), or Abdominal US (CPT® 76700)</li> </ul> </li> <li>➤ At months 3, 9, 15, 21, 27, and 33 after completion of all therapy:                             <ul style="list-style-type: none"> <li>◆ Abdominal Ultrasound (CPT® 76700) and</li> <li>◆ CXR</li> </ul> </li> <li>➤ After month 36, every 6 months up 5 years off therapy:                             <ul style="list-style-type: none"> <li>◆ Abdominal Ultrasound (CPT® 76700)</li> </ul> </li> </ul>

Indication	Imaging Study
	<ul style="list-style-type: none"> <li>➤ Pelvic imaging is not indicated for surveillance unless prior pelvic involvement has been documented or there was tumor rupture at diagnosis</li> </ul>
Surveillance, FAWT or DAWT treated with chemotherapy with or without XRT	<ul style="list-style-type: none"> <li>➤ At months 3, 6, 9, 12, 15, 18, 21, and 24 after completion of all therapy:                             <ul style="list-style-type: none"> <li>◆ CT Chest with (CPT® 71260) or without contrast (CPT® 71250) and</li> <li>◆ CT Abdomen and Pelvis with contrast (CPT® 74177), MRI Abdomen and Pelvis without and with contrast (CPT® 74183 and CPT® 72197), or Abdominal US (CPT® 76700)</li> </ul> </li> <li>➤ Every 3 months, from months 27 through 60:                             <ul style="list-style-type: none"> <li>◆ Abdominal US and</li> <li>◆ CXR</li> </ul> </li> </ul>
Surveillance, stage III or IV	<ul style="list-style-type: none"> <li>➤ At months 3, 6, 9, 12, 18 and 24 months after completion of all therapy:                             <ul style="list-style-type: none"> <li>◆ CT Abdomen with contrast (CPT® 74160)                                     <ul style="list-style-type: none"> <li>■ CT Abdomen and Pelvis with contrast (CPT® 74177) may be substituted if history of pelvic disease or pelvic signs and symptoms)</li> </ul> </li> <li>◆ CT Chest with (CPT® 71260) or without contrast (CPT® 71250)</li> </ul> </li> <li>➤ At months 15, 21, 30, 36, 42, 48, and 60                             <ul style="list-style-type: none"> <li>◆ Abdominal US (CPT® 76700) and</li> <li>◆ CXR</li> </ul> </li> </ul>
Surveillance, recurrent unilateral Wilms tumor	<ul style="list-style-type: none"> <li>➤ At months 3, 6, 9, and 12 after completing therapy for recurrence:                             <ul style="list-style-type: none"> <li>◆ CT of the Chest/Abdomen/Pelvis (CPT® 71260 and CPT® 74177)</li> </ul> </li> <li>➤ Surveillance imaging later than 12 months after completing therapy for recurrence should follow the standard timing listed in this surveillance section</li> </ul>
<ul style="list-style-type: none"> <li>➤ There are no data to support the use of PET imaging for routine surveillance in any individual with Wilms tumor.</li> </ul>	

**Background and Supporting Information**

- Many individuals will present with an asymptomatic abdominal mass, and will undergo ultrasound as a primary evaluation.
- Only ~0.5% of individuals with Wilms tumor will ever develop brain metastases
- A very low risk subset of stage I FHWT will be observed after nephrectomy, and enter directly into surveillance.
- The majority of individuals will receive chemotherapy with or without XRT, beginning within 14 days of initial surgery.

## Bilateral Wilms Tumor (BWT) (PEDONC-7.3)

Indication	Imaging Study
Initial Staging	<ul style="list-style-type: none"> <li>➤ MRI Abdomen and Pelvis without and with contrast (CPT® 74183 and CPT® 72197)                             <ul style="list-style-type: none"> <li>◆ CT Abdomen and Pelvis with contrast (CPT® 74177) may be approved in lieu of MRI per provider request.</li> <li>◆ CT Abdomen and Pelvis with contrast (CPT® 74177) is often performed prior to discovery of bilateral lesions and should not prevent MRI from being approved if requested                                     <ul style="list-style-type: none"> <li>■ Doppler ultrasound to evaluate for tumor thrombus is not necessary unless CT findings are inconclusive</li> </ul> </li> </ul> </li> <li>➤ CT Chest with (CPT® 71260) or without contrast (CPT® 71250)                             <ul style="list-style-type: none"> <li>◆ Should be completed prior to anesthesia exposure if possible</li> </ul> </li> <li>➤ PET is not indicated in the initial staging of any pediatric renal tumor</li> </ul>
Additional initial staging imaging for any individual with neurologic signs or symptoms raising suspicion of CNS metastases	<ul style="list-style-type: none"> <li>➤ MRI Brain without and with contrast (CPT® 70553)</li> </ul>
Additional initial staging imaging for any individual with signs or symptoms raising suspicion of bony metastases	<ul style="list-style-type: none"> <li>➤ Bone scan (see: <a href="#">PEDONC-1.3</a> for coding)</li> </ul>
Treatment response ~every 2 cycles during treatment and at the end of planned therapy	<ul style="list-style-type: none"> <li>➤ MRI Abdomen and Pelvis without and with contrast (CPT® 74183 and CPT® 72197)                             <ul style="list-style-type: none"> <li>◆ CT Abdomen and Pelvis with contrast (CPT® 74177) may be used for individuals with a contraindication to MRI</li> </ul> </li> <li>➤ CT Chest with (CPT® 71260) or without contrast (CPT® 71250)</li> </ul>
Rare circumstances to establish the presence of active disease only when a major therapeutic decision depends on PET avidity	<ul style="list-style-type: none"> <li>➤ PET/CT (CPT® 78815)</li> </ul>
Surveillance, stage I or II	<ul style="list-style-type: none"> <li>➤ At months 6, 12, 18, 24, 30, and 36 after completion of all therapy:                             <ul style="list-style-type: none"> <li>◆ CT Chest with (CPT® 71260) or without contrast (CPT® 71250)</li> </ul> </li> <li>➤ At months 3, 6, 12, 18, 24, 30, and 36 after completion of all therapy:</li> </ul>

Indication	Imaging Study
	<ul style="list-style-type: none"> <li>◆ CT Abdomen with contrast (CPT® 74160), MRI Abdomen without and with contrast (CPT® 74183), or Abdominal US (CPT® 76700)</li> <li>➤ At months 9, 15, 21, 27, 33, 39, 42, 45, 48, 51, 54, 57, and 60 after completion of all therapy:                             <ul style="list-style-type: none"> <li>◆ Abdominal US (CPT® 76700)</li> </ul> </li> <li>➤ Pelvic imaging is not indicated for surveillance unless prior pelvic involvement has been documented or there was tumor rupture at diagnosis</li> <li>➤ Surveillance imaging after month 36:                             <ul style="list-style-type: none"> <li>◆ Abdominal US (CPT® 76700) every 3 months until age 8</li> <li>◆ CXR</li> </ul> </li> <li>➤ Surveillance imaging with CT of the Chest/Abdomen/Pelvis (CPT® 71260 and CPT® 74177) following successful treatment for recurrent bilateral Wilms tumor can be approved every 3 months for 1 year after completing therapy for recurrence.                             <ul style="list-style-type: none"> <li>◆ Surveillance imaging later than 12 months after completing therapy for recurrence should follow the standard timing listed in this surveillance section.</li> </ul> </li> </ul>
Surveillance, stage III or IV	<ul style="list-style-type: none"> <li>➤ At months 3, 6, 9, 12, 18 and 24 after completion of all therapy:                             <ul style="list-style-type: none"> <li>◆ CT Abdomen with contrast (CPT® 74160)                                     <ul style="list-style-type: none"> <li>■ CT Abdomen/Pelvis with contrast (CPT® 74177) may be substituted if history of pelvic disease or pelvic signs and symptoms</li> </ul> </li> <li>◆ CT Chest with (CPT® 71260) or without contrast (CPT® 71250)</li> </ul> </li> <li>➤ At months 15, 21, 30, 36, 42, 48 and 60 after completion of all therapy:                             <ul style="list-style-type: none"> <li>◆ CXR</li> <li>◆ Abdominal US (CPT® 76700)</li> </ul> </li> </ul>
<ul style="list-style-type: none"> <li>➤ PET is not routinely utilized to assess treatment response or for surveillance in Wilms tumor.</li> </ul>	

**Background and Supporting Information:**

- Many individuals will present with an asymptomatic abdominal mass, and will undergo ultrasound as a primary evaluation.
- Individuals with bilateral Wilms Tumor may begin therapy without a histologic diagnosis to preserve a localized disease stage and attempt to shrink the tumors to allow for renal-sparing surgical approaches.
- Only ~0.5% of Wilms tumor individuals will ever develop brain metastases
- If treating with chemotherapy without a biopsy, disease evaluation is indicated at week 6. If either tumor has not shrunk 50%, then open biopsy is indicated to confirm favorable histology.
- If partial nephrectomy still not feasible at week 6, the next disease evaluation is at week 12. Surgical resection should occur no later than week 12.

## Pediatric Renal Cell Carcinoma (RCC) (PEDONC-7.4)

Indication	Imaging Study
Initial Staging	<ul style="list-style-type: none"> <li>➤ CT Abdomen and Pelvis with contrast (CPT® 74177)                             <ul style="list-style-type: none"> <li>◆ If bilateral renal lesions are noted on ultrasound or CT, MRI Abdomen and Pelvis without and with contrast (CPT® 74183 and CPT® 72197) should be strongly considered</li> </ul> </li> <li>➤ CT Chest with (CPT® 71260) or without contrast (CPT® 71250)                             <ul style="list-style-type: none"> <li>◆ Should be completed prior to anesthesia exposure if possible</li> </ul> </li> <li>➤ PET scan is not indicated in the initial staging of any pediatric renal tumor</li> </ul>
Additional initial staging for any individual with neurologic signs or symptoms raising suspicion of CNS metastases	<ul style="list-style-type: none"> <li>➤ MRI Brain without and with contrast (CPT® 70553)</li> </ul>
Additional initial staging for any individual with signs or symptoms raising suspicion of bony metastases	<ul style="list-style-type: none"> <li>➤ Bone scan (See: <b><u>PEDONC-1.3</u></b> for coding)</li> </ul>
Treatment response in individuals with residual measurable disease after initial surgery and receiving adjuvant medical therapy	<ul style="list-style-type: none"> <li>➤ Every 2 cycles during active treatment:                             <ul style="list-style-type: none"> <li>◆ CT Chest with (CPT® 71260) or without contrast (CPT® 71250) and</li> <li>◆ CT Abdomen with contrast (CPT® 74160)                                     <ul style="list-style-type: none"> <li>■ Pelvic imaging is not indicated unless prior pelvic involvement has been documented</li> </ul> </li> </ul> </li> </ul>
Rare circumstances to establish the presence of active disease only when a major therapeutic decision depends on PET avidity	<ul style="list-style-type: none"> <li>➤ PET/CT (CPT® 78815)</li> <li>➤ Indications and coding for rare circumstances where PET/MRI may be approved are found in <b><u>PET Imaging in Pediatric Oncology (PEDONC-1.4)</u></b></li> </ul>
Surveillance in individuals with documented CNS metastases	<ul style="list-style-type: none"> <li>➤ Every 6 months for 2 years after completion of all therapy:                             <ul style="list-style-type: none"> <li>◆ MRI Brain without and with contrast (CPT® 70553)</li> </ul> </li> </ul>
Surveillance in individuals with TFE3 or TFEB subtype	<ul style="list-style-type: none"> <li>➤ Every 3 months for 2 years, then every 6 months for 2 years after completion of all therapy:                             <ul style="list-style-type: none"> <li>◆ CT Chest with (CPT® 71260) or without contrast (CPT® 71250)</li> <li>◆ CT Abdomen with contrast (CPT® 74160) or MRI Abdomen without and with contrast (CPT® 74183)                                     <ul style="list-style-type: none"> <li>■ Pelvic imaging is not indicated for surveillance unless prior pelvic involvement has been documented</li> </ul> </li> </ul> </li> </ul>
Surveillance in all other histologies	<ul style="list-style-type: none"> <li>➤ See: <b><u>Renal Cell Cancer (RCC) – Surveillance (ONC-17.4)</u></b></li> </ul>



Indication	Imaging Study
New signs/symptoms suggestive of CNS recurrence	<ul style="list-style-type: none"> <li>➤ MRI Brain without and with contrast (CPT® 70553)</li> </ul>
<ul style="list-style-type: none"> <li>➤ PET is not routinely utilized to assess treatment response in pediatric RCC.</li> </ul>	

### **Background and Supporting Information**

- A majority of pediatric cases have a novel subtype involving TFE3 or TFEB translocations, which have a different natural history than “adult type” RCC
- Individuals of any age with TFE3 or TFEB translocated RCC should be imaged according to this guideline section.
- 40% to 45% of pediatric RCC cases have similar histologies to adult RCC (clear cell, papillary, chromophobe, etc.) and imaging decisions will be similar to general oncology guidelines.
- Individuals with all other subtypes of RCC should be imaged according to **Renal Cell Cancer (RCC) (ONC-17)** in the Oncology Imaging Guidelines
- Many individuals will present with an asymptomatic abdominal mass, and will undergo ultrasound as a primary evaluation. Doppler ultrasound to evaluate for tumor thrombus is no longer necessary unless CT findings are inconclusive, and should not be performed if CT is already completed.
- Other staging imaging than what is stated in the above table should be deferred until a histologic diagnosis is made, by complete nephrectomy for most unilateral renal tumors and biopsy for bilateral renal tumors or inoperable unilateral tumors
- Most individuals will have surgical resection of all disease at the time of diagnosis and will enter directly into surveillance

### **Clear Cell Sarcoma of the Kidney (CCSK) (PEDONC-7.5)**

**Be careful not to confuse the diagnosis with clear cell RCC. See: Renal Cell Cancer (RCC) (ONC-17) for imaging guidelines.**

Indication	Imaging Study
Initial Staging	<ul style="list-style-type: none"> <li>➤ CT Abdomen and Pelvis with contrast (CPT® 74177)                             <ul style="list-style-type: none"> <li>◆ Doppler ultrasound to evaluate for tumor thrombus is not necessary unless CT findings are inconclusive</li> </ul> </li> <li>➤ CT Chest with (CPT® 71260) or without contrast (CPT® 71250)                             <ul style="list-style-type: none"> <li>◆ Should be completed prior to anesthesia exposure if possible</li> </ul> </li> <li>➤ Bone scan (see: <b><u>PEDONC-1.3</u></b> for coding)</li> <li>➤ MRI Brain without and with contrast (CPT® 70553)</li> <li>➤ PET is not indicated in the initial staging of any pediatric renal tumor</li> </ul>

Indication	Imaging Study
Bilateral renal lesions are noted on ultrasound or CT in initial staging	<ul style="list-style-type: none"> <li>➤ MRI Abdomen and Pelvis without and with contrast</li> </ul>
Treatment response ~every 2 cycles during treatment and at the end of planned therapy	<ul style="list-style-type: none"> <li>➤ CT Chest with (CPT® 71260) <i>or</i> without contrast (CPT® 71250)</li> <li>➤ CT Abdomen and Pelvis with contrast (CPT® 74177) <i>or</i> MRI Abdomen and Pelvis without and with contrast (CPT® 74183 and CPT® 72197)</li> <li>➤ Additionally, for individuals with CNS metastases at initial staging:                             <ul style="list-style-type: none"> <li>◆ MRI Brain without and with contrast (CPT® 70553) Bone scan (see: <b><u>PEDONC-1.3</u></b> for coding) at the end of planned therapy</li> </ul> </li> </ul>
Rare circumstances to establish the presence of active disease only when a major therapeutic decision depends on PET avidity	<ul style="list-style-type: none"> <li>➤ PET/CT (CPT® 78815)</li> <li>➤ Indications and coding for rare circumstances where PET/MRI may be approved are found in <b><u>PET Imaging in Pediatric Oncology (PEDONC-1.4)</u></b></li> </ul>
Surveillance	<ul style="list-style-type: none"> <li>➤ Every 3 months for 2 years after completion of all therapy:                             <ul style="list-style-type: none"> <li>◆ CT Chest with (CPT® 71260) <i>or</i> without contrast (CPT® 71250)</li> <li>◆ CT Abdomen and Pelvis with contrast (CPT® 74177) <i>or</i> MRI Abdomen and Pelvis without and with contrast (CPT® 74183 and CPT® 72197)</li> </ul> </li> <li>➤ Every 6 months for 3 years after completion of all therapy:                             <ul style="list-style-type: none"> <li>◆ MRI Brain without and with contrast (CPT® 70553)</li> </ul> </li> <li>➤ Every 3 months for 1 year, then every 6 months for 2 years after completion of all therapy:                             <ul style="list-style-type: none"> <li>◆ Bone scan (see: <b><u>PEDONC-1.3</u></b> for coding)</li> <li>◆ If negative at 36 months, no further advanced imaging is necessary.</li> </ul> </li> <li>➤ Other surveillance imaging should be by Abdominal US (CPT® 76700) and chest x-ray</li> </ul>

### **Background and Supporting Information**

- Many individuals will present with an asymptomatic abdominal mass, and will undergo ultrasound as a primary evaluation.
- Other staging imaging should be deferred until a histologic diagnosis is made, by complete nephrectomy for most unilateral renal tumors and biopsy for bilateral renal tumors or inoperable unilateral tumors

### **Malignant Rhabdoid Tumor of the Kidney (MRT) and Other**

## **Extracranial Sites (PEDONC-7.6)**

**Be careful not to confuse the diagnosis with rhabdomyosarcoma. See: Rhabdomyosarcoma (RMS) (PEDONC-8.2) for Imaging Guidelines**

<b>Indication</b>	<b>Imaging Study</b>
Initial Staging	<ul style="list-style-type: none"> <li>➤ CT Abdomen and Pelvis with contrast (CPT® 74177)                             <ul style="list-style-type: none"> <li>◆ Doppler ultrasound to evaluate for tumor thrombus is not necessary unless CT findings are inconclusive</li> </ul> </li> <li>➤ CT Chest with (CPT® 71260) or without contrast (CPT® 71250)                             <ul style="list-style-type: none"> <li>◆ Should be completed prior to anesthesia exposure if possible</li> </ul> </li> <li>➤ Bone scan (see: <b><u>PEDONC-1.3</u></b> for coding)</li> <li>➤ MRI Brain without and with contrast (CPT® 70553)</li> <li>➤ PET is not indicated in the initial staging of any pediatric renal tumor</li> </ul>
Bilateral renal lesions are noted on ultrasound or CT in initial staging	<ul style="list-style-type: none"> <li>➤ MRI Abdomen and Pelvis without and with contrast</li> </ul>
Treatment response ~every 2 cycles during treatment and at the end of planned therapy	<ul style="list-style-type: none"> <li>➤ CT Chest with (CPT® 71260) or without contrast (CPT® 71250)</li> <li>➤ CT Abdomen and Pelvis with contrast (CPT® 74177) or MRI Abdomen and Pelvis without and with contrast (CPT® 74183 and CPT® 72197)                             <ul style="list-style-type: none"> <li>◆ If primary site other than kidney, perform CT with contrast or MRI without and with contrast of primary site in place of abdominal and pelvic imaging</li> </ul> </li> <li>➤ MRI Brain without and with contrast (CPT® 70553) can be performed:                             <ul style="list-style-type: none"> <li>◆ Every 2 cycles during treatment for individuals with CNS metastases at initial staging</li> <li>◆ At the end of planned therapy for all individuals</li> </ul> </li> <li>➤ Bone scan (see: <b><u>PEDONC-1.3</u></b> for coding) at the end of planned therapy only if positive at initial diagnosis</li> </ul>
Rare circumstances to establish the presence of active disease only when a major therapeutic decision depends on PET avidity	<ul style="list-style-type: none"> <li>➤ PET/CT (CPT® 78815)</li> <li>➤ Indications and coding for rare circumstances where PET/MRI may be approved are found in <b><u>PET Imaging in Pediatric Oncology (PEDONC-1.4)</u></b></li> </ul>
Surveillance	<ul style="list-style-type: none"> <li>➤ Every 3 months for 2 years after completion of all therapy:                             <ul style="list-style-type: none"> <li>◆ CT Chest with (CPT® 71260) or without contrast (CPT® 71250)</li> </ul> </li> <li>➤ Every 3 months for 3 years after completion of all therapy:</li> </ul>

Indication	Imaging Study
	<ul style="list-style-type: none"> <li>◆ CT Abdomen and Pelvis with contrast (CPT® 74177) or MRI Abdomen and Pelvis without and with contrast (CPT® 74183 and CPT® 72197)                             <ul style="list-style-type: none"> <li>■ If primary site other than kidney, perform CT with contrast or MRI without and with contrast of primary site in place of abdominal imaging</li> </ul> </li> <li>➤ Every 3 months for 1 year, then every 6 months for 1 year after completion of all therapy:                             <ul style="list-style-type: none"> <li>◆ MRI Brain without and with contrast (CPT® 70553)</li> </ul> </li> <li>➤ If bone scan positive at initial diagnosis:                             <ul style="list-style-type: none"> <li>◆ Every 3 months for 1 year, then every 6 months for 2 years:                                     <ul style="list-style-type: none"> <li>■ Bone scan (see: <b><u>PEDONC-1.3</u></b> for coding)</li> </ul> </li> <li>◆ If negative at 36 months, no further advanced imaging is necessary</li> </ul> </li> <li>➤ The role of surveillance imaging beyond these timeframes in unclear. Abdominal US (CPT® 76700) and chest x-ray may be considered</li> </ul>
Continued Surveillance of individuals with Rhabdoid Tumor predisposition Syndrome	<ul style="list-style-type: none"> <li>➤ See: <b><u>Rhabdoid Tumor Predisposition Syndrome (PEDONC-2.11)</u></b></li> </ul>

### ***Background and Supporting Information***

- MRT is a highly aggressive histologic variant that can also occur in other locations and all non-CNS sites should follow these guidelines.
- Primary CNS rhabdoid malignancies should be imaged according to **Atypical Teratoid/Rhabdoid Tumors (ATRT) (PEDONC-4.5)**
- Many individuals will present with an asymptomatic abdominal mass, and will undergo ultrasound as a primary evaluation.
- Other staging imaging should be deferred until a histologic diagnosis is made, by complete nephrectomy for most unilateral renal tumors and biopsy for bilateral renal tumors or inoperable unilateral tumors

### **Congenital Mesoblastic Nephroma (CMN) (PEDONC-7.7)**

#### **Congenital Mesoblastic Nephroma Initial Staging**

- CT Abdomen and Pelvis with contrast (CPT® 74177) is indicated in all individuals
- CT Chest with (CPT® 71260) can be approved to evaluate inconclusive findings on chest x-ray

### **Congenital Mesoblastic Nephroma Treatment Response:**

- CT Abdomen and Pelvis with contrast (CPT® 74177) once following resection to establish baseline imaging, and those with a complete resection should then be imaged according to surveillance guidelines
- CT Abdomen and Pelvis with contrast (CPT® 74177) for individuals receiving preoperative chemotherapy every 2 cycles of therapy until surgery and then should be imaged according to surveillance guidelines after their postoperative baseline imaging study

### **Congenital Mesoblastic Nephroma Surveillance Imaging**

- Ultrasound is the preferred surveillance imaging modality to avoid radiation and anesthesia exposures
- CT Abdomen and Pelvis with contrast (CPT® 74177) **or** MRI Abdomen and Pelvis without and with contrast (CPT® 74183 and CPT® 72197) for residual abnormalities present on post-operative imaging or inconclusive findings on ultrasound every 3 months for 1 year after completion of all therapy

### ***Background and Supporting Information***

- This is the most common primary renal tumor occurring in young infants, and the overall prognosis is very good
- Complete surgical removal is curative in most cases, and histologically confirmed metastatic disease or bilateral disease has never been reported
- Many individuals will present with an asymptomatic abdominal mass at the time of birth or abnormal prenatal ultrasound, and will undergo ultrasound as a primary evaluation.
- PET is not indicated in the initial staging of any pediatric renal tumor
- Recurrences are rare but most occur within 12 months of diagnosis

## References

1. Fernandez C, Geller JI, Ehrlich PF, et al. Renal tumors. In: Pizzo PA, Poplack DG, eds. Principles and Practice of Pediatric Oncology. 7th ed. Philadelphia, PA: Wolters Kluwer; 2016:753-771.
2. Dome JS, Mullen EA, and Argani P. Pediatric renal tumors. In: Orkin SH, Fisher DE, Ginsburg D, Look AT, Lux SE, Nathan DG, eds. Nathan and Oski's Hematology and Oncology of Infancy and Childhood. 8th ed. Philadelphia, PA: Elsevier Saunders; 2015:1714-1746.
3. Kaste SC, Brady SL, Yee B, et al. Is routine pelvic surveillance imaging necessary in patients with Wilms tumor? Cancer. 2013;119(1):182-188. doi:10.1002/cncr.27687.
4. Malkan AD, Loh A, Bahrami A, et al. An approach to renal masses in pediatrics. Pediatrics. 2015;135(1):142-158. doi:10.1542/peds.2014-1011.
5. Khanna G, Rosen N, Anderson JR, et al. Evaluation of diagnostic performance of CT for detection of tumor thrombus in children with Wilms tumor: a report from the Children's Oncology Group. Pediatr Blood Cancer. 2012;58(4):551-555. doi:10.1002/pbc.23222.
6. Kieran K and Ehrlich PF. Current surgical standards of care in Wilms tumor. Urol Oncol. 2016;34(1):13-23. doi:10.1016/j.urolonc.2015.05.029.
7. Moinul Hossain AK, Shulkin BL, Gelfand MJ, et al. FDG positron emission tomography/computed tomography studies of Wilms' tumor. Eur J Nucl Med Mol Imaging. 2010;37(7):1300-1308. doi:10.1007/s00259-010-1396-2.
8. Misch D, Steffen IG, Schönberger S, et al. Use of positron emission tomography for staging, preoperative response assessment and post therapeutic evaluation in children with Wilms tumor. Eur J Nucl Med Mol Imaging. 2008;35(9):1642-1650. doi:10.1007/s00259-008-0819-9.
9. Servaes S, Khanna G, Naranjo A, et al. Comparison of diagnostic performance of CT and MRI for abdominal staging of pediatric renal tumors: a report from the Children's Oncology Group. Pediatr Radiol. 2015;45(2):166-172. doi:10.1007/s00247-014-3138-2.
10. Servaes SE, Hoffer FA, Smith EA, Khanna G. Imaging of Wilms tumor: an update. Pediatr Radiol. 2019;49(11):1441-1452. doi:10.1007/s00247-019-04423-3.
11. Uslu L, Doing J, Link M, Rosenburg J, Quon A, Daldrup-Link HE. Value of 18F-FDG PET and PET/CT for Evaluation of Pediatric Malignancies. J Nucl Med. 2015;56(2):274-286. doi:10.2967/jnumed.114.146290.
12. Dome JS, Graf N, Geller JI, et al. Advances in Wilms tumor treatment and biology: progress through international collaboration. J Clin Oncol. 2015;33(27):2999-3007. doi:10.1200/JCO.2015.62.1888.
13. Venkatramani R, Chi Y-Y, Coppes MJ, et al. Outcome of patients with intracranial relapse enrolled on National Wilms Tumor Study Group clinical trials. Pediatr Blood Cancer. 2017;64(7):e26406. doi:10.1002/pbc.26406.
14. Mullen EA, Chi Y-Y, Hibbitts E, et al. Impact of surveillance imaging modality on survival after recurrence in patients with favorable-histology Wilms tumor: a report from the Children's Oncology Group. J Clin Oncol. 2018;36:3396-3403. doi:10.1200/JCO.18.00076.
15. Ehrlich P, Chi Y-Y, Chintagumpala MM, et al. results of the first prospective multi-institutional treatment study in children with bilateral Wilms tumor (AREN0534): a report from the Children's Oncology Group. Ann Surg. 2017;266(3):470-478. doi:10.1097/SLA.0000000000002356.
16. Geller JI, Ehrlich PF, Cost NG, et al. Characterization of adolescent and pediatric renal cell carcinoma: a report from the Children's Oncology Group study AREN03B2. Cancer. 2015 July; 121(14):2457-2464. doi:10.1002/cncr.29368.
17. Rialon KL, Gulack BC, Englum BR, Routh JC, Rice HE. Factors impacting survival in children with renal cell carcinoma. J Pediatr Surg. 2015;50(6):1014-1018. doi:10.1016/j.jpedsurg.2015.03.027.
18. Young EE, Brown CTG, Merguerian PA, Akhavan A. Pediatric and adolescent renal cell carcinoma. Urol Oncol. 2016;34(1):42-49. doi:10.1016/j.urolonc.2015.06.009.
19. Gooskens SL, Houwing ME, Vujanic GM, et al. Congenital mesoblastic nephroma 50 years after its recognition: a narrative review. Pediatr Blood Cancer. 2017; 64(7):e26437. doi:10.1002/pbc.26437.
20. Seibel NL, Chi YY, et al. Impact of cyclophosphamide and etoposide on outcome of clear cell sarcoma of the kidney treated on the National Wilms Tumor Study-5 (NWTS-5). Pediatr Blood and Cancer. 2019;66(1):e27450. doi:10.1002/pbc.27450.
21. Balis F, Green DM, Anderson C, et al. National Comprehensive Cancer Network (NCCN) Guidelines Version 1.2022 – April 12, 2022. Wilms Tumor (Nephroblastoma), available at: [https://www.nccn.org/professionals/physician\\_gls/pdf/wilms\\_tumor.pdf](https://www.nccn.org/professionals/physician_gls/pdf/wilms_tumor.pdf), Referenced with permission from the NCCN Clinical Practice Guidelines in Oncology (NCCN Guidelines™) for Wilms Tumor (Nephroblastoma) V1.2022 – 4/12/2022. ©2022 National Comprehensive Cancer Network, Inc. All rights reserved. The NCCN Guidelines™ and illustrations herein may not be reproduced in any form for any purpose without the express written permission of the NCCN. To view the most recent and complete version of the NCCN Guidelines™, go online to [NCCN.org](https://www.nccn.org)
22. Servaes SE, Hoffer FA, Smith EA, Khanna G. Imaging of Wilms tumor: an update. Pediatric Radiol. 2019;49(11):1441-1452. doi:10.1007/s00247-019-04423-3.
23. Dix DB, Seibel NL, Chi Y, et al. Treatment of stage IV favorable histology Wilms tumor with lung metastases: a report from the Children's Oncology Group AREN0533 study. J Clin Oncol. 2018;36(16):1564-1570. doi:10.1200/JCO.2017.77.1931.

## **Pediatric Soft Tissue Sarcomas (PEDONC-8)**

**Pediatric Soft Tissue Sarcomas – General Considerations (PEDONC-8.1)**

**Rhabdomyosarcoma (RMS) (PEDONC-8.2)**

**Non-Rhabdomyosarcoma Soft Tissue Sarcomas (NRSTS) (PEDONC-8.3)**

## **Pediatric Soft Tissue Sarcomas – General Considerations (PEDONC-8.1)**

- Unless specified below, individuals age <18 years old should be imaged according to this guideline section. Exceptions include:
  - ◆ Rhabdomyosarcoma in individuals (except uterine rhabdomyosarcoma) of all ages should be imaged according to guidelines in **Rhabdomyosarcoma (RMS) (PEDONC-8.2)**
  - ◆ Uterine rhabdomyosarcoma individuals of all ages should be imaged according to guidelines in Uterine Cancer (ONC-22). See: **Uterine Cancer – General Considerations (ONC-22.0)** in the Oncology Imaging Guidelines
  - ◆ Kaposi’s sarcoma in individuals of all ages should be imaged according to guidelines in **Kaposi’s Sarcoma (ONC-31.10)** in the Oncology Imaging Guidelines
- Evaluation of soft tissue masses of uncertain nature prior to biopsy should follow general imaging guidelines:
  - ◆ Individuals age 0 to 17 years, see: **Soft Tissue and Bone Masses (PEDMS-3)** in the Pediatric Musculoskeletal Imaging Guidelines
  - ◆ Individuals age ≥18 years, see: **Soft Tissue Mass or Lesion of Bone (MS-10)** in the Musculoskeletal Imaging Guidelines
- Where there are indications for PET/CT in these guidelines, note that indications and coding for rare circumstances where PET/MRI may be approved are found in **PET Imaging in Pediatric Oncology (PEDONC-1.4)**

## **Rhabdomyosarcoma (RMS) (PEDONC-8.2)**

- Individuals of all ages are imaged according to this guideline, with exception of uterine rhabdomyosarcoma, which is imaged according to Uterine Cancer (ONC-22). See: **Uterine Cancer – General Considerations (ONC-22.0)** in the Oncology Imaging Guidelines.

Indication	Imaging Study
Initial staging for all individuals	<b><u>ALL of the following:</u></b> <ul style="list-style-type: none"> <li>◆ CT with contrast of primary site or MRI without and with contrast of primary site</li> <li>◆ CT Chest with contrast or CT Chest without contrast                             <ul style="list-style-type: none"> <li>■ Should be completed prior to anesthesia exposure if possible</li> </ul> </li> <li>◆ Whole-body PET/CT (CPT® 78816)                             <ul style="list-style-type: none"> <li>■ Bone scan may be substituted for PET, if PET not available</li> </ul> </li> </ul>
<b><u>Additional initial staging for ANY of the following:</u></b>	<ul style="list-style-type: none"> <li>◆ CT Abdomen and Pelvis with contrast (CPT® 74177)</li> </ul>



Indication	Imaging Study
<ul style="list-style-type: none"> <li>◆ Evaluation of inconclusive PET findings in the abdomen or pelvis</li> <li>◆ Primary site of abdomen or pelvis</li> <li>◆ Lower extremity primary site</li> </ul>	
<p><u>Additional initial staging for ANY of the following:</u></p> <ul style="list-style-type: none"> <li>◆ Primary site involving the paraspinal or paravertebral region</li> <li>◆ PET or bone scan-avid lesions in skull, neck, vertebrae</li> <li>◆ Neurologic signs or symptoms raising suspicion of CNS metastases</li> </ul>	<p><u>ALL of the following:</u></p> <ul style="list-style-type: none"> <li>◆ MRI Brain (CPT® 70553)</li> <li>◆ MRI Spine without and with contrast (Cervical-CPT® 72156, Thoracic-CPT® 72157, Lumbar-CPT® 72158)</li> </ul>
<p>Treatment response, every 2 cycles during treatment and at the end of planned therapy</p>	<p><u>ALL of the following:</u></p> <ul style="list-style-type: none"> <li>◆ CT Chest with (CPT® 71260) contrast or CT Chest without contrast (CPT® 71250)</li> <li>◆ CT with contrast or MRI without and with contrast of primary site</li> <li>◆ CT with contrast or MRI without and with contrast of all known metastatic sites using the same conventional imaging modality as per initial staging</li> </ul>
<p><u>ANY of the following:</u></p> <ul style="list-style-type: none"> <li>◆ Response assessment prior to local control surgery or radiation therapy</li> <li>◆ Evaluation of residual mass visible on conventional imaging as part of end of therapy evaluation</li> <li>◆ Response assessment of disease visible on PET but not conventional imaging</li> <li>◆ PET results are likely to result in a treatment change for the individual, including a change from active treatment to surveillance.</li> </ul>	<ul style="list-style-type: none"> <li>◆ Whole-body PET/CT (CPT 78816) <ul style="list-style-type: none"> <li>■ Once PET has been documented to be negative for a given individual’s cancer or all PET-avid disease has been surgically resected, PET should not be used for continued disease monitoring or surveillance unless one of the exceptions in section <b><u>General Guidelines (PEDONC-1)</u></b> applies.</li> </ul> </li> </ul>
<p><u>Restaging following local control surgery</u></p>	<p><u>ALL of the following:</u></p> <ul style="list-style-type: none"> <li>◆ CT with contrast or MRI without and with contrast of primary site</li> </ul>

Indication	Imaging Study
	<ul style="list-style-type: none"> <li>◆ CT with contrast or MRI without and with contrast of all known metastatic sites using the same conventional imaging modality as per initial staging</li> </ul>
Surveillance, localized RMS	<p><u>ALL of the following, every 3 months for 1 year, then every 4 months for 2 years, then every 6 months for 1 year after completion of all therapy:</u></p> <ul style="list-style-type: none"> <li>◆ CT with contrast <b>or</b> MRI without and with contrast of primary tumor site</li> <li>◆ Chest x-ray                             <ul style="list-style-type: none"> <li>■ CT Chest with (CPT® 71260) <b>or</b> CT Chest without contrast (CPT® 71250) is indicated for new or worsening clinical symptoms of chest disease or new findings on chest x-ray</li> </ul> </li> </ul>
Surveillance, metastatic RMS	<p><u>ALL of the following, every 3 months for 1 year, then every 4 months for 2 years, then every 6 months for 1 year after completion of all therapy:</u></p> <ul style="list-style-type: none"> <li>◆ CT with contrast <b>or</b> MRI without and with contrast of primary tumor site</li> <li>◆ CT Chest with (CPT® 71260) <i>or</i> without contrast (CPT® 71250)</li> <li>◆ CT with or without contrast of all known metastatic sites</li> <li>◆ Nuclear bone scan (see: <b>PEDONC-1.3</b> for coding) for surveillance of known bony metastases</li> </ul>
<u>Suspected recurrence</u>	<ul style="list-style-type: none"> <li>◆ Repeat conventional imaging as per initial staging for all individuals</li> </ul>
<p><u>ONE of the following:</u></p> <ul style="list-style-type: none"> <li>◆ Biopsy-proven recurrence</li> </ul>	<ul style="list-style-type: none"> <li>◆ Whole-body PET/CT (CPT® 78816)</li> </ul>

Indication	Imaging Study
<ul style="list-style-type: none"> <li>◆ Conventional imaging (CT, MRI, US, plain film) reveals findings that are inconclusive or suspicious for recurrence, and PET avidity will determine whether biopsy or continued observation is appropriate</li> <li>◆ Rare circumstances where obvious clinical symptoms show strong evidence suggesting recurrence, and PET would replace conventional imaging modalities.</li> </ul>	

### **Background and Supporting Information**

- Soft tissue sarcomas occur in both adult and pediatric individuals, but some are more common in one age group than the other.
- Pediatric soft tissue sarcomas are divided into **two** groups:
  - ◆ Rhabdomyosarcoma (RMS) accounts for ~60% of soft tissue sarcomas in young individuals, but only ~25% of soft tissue sarcomas in adolescents
  - ◆ Non-rhabdomyosarcoma soft tissue sarcomas (NRSTS) which encompasses all other histologic subtypes
- Because RMS can arise from any muscle tissue, the presenting symptoms and primary tumor sites vary widely and strongly influence the appropriate imaging decisions
- CT with contrast is the preferred primary site imaging modality for RMS arising in the thoracic cavity (not the chest wall)
- MRI without and with contrast is the preferred primary site imaging modality for RMS occurring in all other anatomic locations, including the chest wall.
- PET/CT is superior to conventional imaging for detection of nodal and bony metastases in pediatric RMS and is indicated in the initial staging of all individuals after histologic diagnosis is established
- CT Abdomen and Pelvis with contrast (CPT® 74177) is not routinely indicated in the initial metastatic staging of pediatric RMS
- PET is not routinely utilized to assess treatment response in RMS
- PET is generally not indicated during active treatment for recurrent pediatric cancer
- Residual mass that has not changed in size since the last conventional imaging does not justify PET imaging during surveillance
- PET avidity in a residual mass at the end of planned therapy is not an indication for PET imaging during surveillance

## Non-Rhabdomyosarcoma Soft Tissue Sarcomas (NRSTS) (PEDONC-8.3)

Indication	Imaging Study
Initial staging of all individuals	<p><u>ALL of the following:</u></p> <ul style="list-style-type: none"> <li>◆ CT with contrast or MRI without and with contrast of primary site</li> <li>◆ CT chest with contrast or without contrast                             <ul style="list-style-type: none"> <li>■ Should be completed prior to anesthesia if possible</li> </ul> </li> <li>◆ For primary tumor of the chest wall, both MRI chest wall without and with contrast (71552) and CT Chest with contrast or without contrast to assess for pulmonary metastatic disease (indicated simultaneously)</li> <li>◆ Nuclear bone scan (see: <b><u>PEDONC-1.3</u></b> for coding) if criteria below for PET not met, or if PET is not available</li> </ul>
<p>ANY of the following:</p> <ul style="list-style-type: none"> <li>◆ Prior to neoadjuvant chemotherapy (i.e. individuals who will not undergo up front resection)</li> <li>◆ Initial staging of desmoplastic small round cell tumor</li> <li>◆ Inconclusive findings on conventional imaging</li> </ul>	<ul style="list-style-type: none"> <li>◆ PET/CT (CPT® 78815)                             <ul style="list-style-type: none"> <li>■ Whole-body PET/CT (CPT® 78816) if there is clinical suspicion of skull or distal lower extremity involvement</li> </ul> </li> </ul>
<p><u>ANY of the following:</u></p> <ul style="list-style-type: none"> <li>◆ Additional initial staging for individuals with disease in the abdomen, pelvis, or lower extremities</li> <li>◆ Inconclusive findings in the abdomen on PET/CT</li> </ul>	<ul style="list-style-type: none"> <li>◆ CT Abdomen and Pelvis with contrast (CPT® 74177) if not already performed</li> </ul>
Additional staging for individuals with primary site arising in the paraspinal or paravertebral region	<ul style="list-style-type: none"> <li>◆ MRI Brain (CPT® 70553) and Spine (Cervical-CPT® 72156, Thoracic-CPT® 72157, Lumbar-CPT® 72158) without and with contrast</li> </ul>
Further evaluation of ANY of the following:	<p><u>ALL of the following:</u></p> <ul style="list-style-type: none"> <li>◆ MRI Brain (CPT® 70553)</li> </ul>

Indication	Imaging Study
<ul style="list-style-type: none"> <li>◆ PET or nuclear bone scan-avid lesions in skull, neck, or vertebrae seen on initial imaging</li> <li>◆ Neurologic signs or symptoms raising suspicion of CNS metastases</li> </ul>	<ul style="list-style-type: none"> <li>◆ MRI Spine (Cervical-CPT® 72156, Thoracic-CPT® 72157, Lumbar-CPT® 72158)</li> </ul>
<p>Treatment response, every 2 cycles of treatment, and at the end of planned therapy</p>	<p><u>Either of the following:</u></p> <ul style="list-style-type: none"> <li>◆ CT Chest with (CPT® 71260) or CT Chest without contrast (CPT® 71250), and</li> <li>◆ CT with contrast or MRI without and with contrast of primary site, and</li> <li>◆ Imaging of all known metastatic sites using the same conventional imaging modality as per initial staging</li> </ul> <p>OR</p> <ul style="list-style-type: none"> <li>◆ PET/CT (CPT® 78815) if disease visible on initial staging PET but not on conventional imaging                             <ul style="list-style-type: none"> <li>■ Whole-body PET/CT (CPT® 78816) if there is clinical suspicion of skull or distal lower extremity involvement</li> </ul> </li> </ul>
<p>ANY of the following, if PET positive at initial diagnosis:</p> <ul style="list-style-type: none"> <li>◆ Assessment prior to local control surgery or radiation therapy</li> <li>◆ Evaluation of residual mass visible on conventional imaging as part of end of therapy evaluation</li> <li>◆ Rare circumstances when PET results are likely to result in a treatment change for the individual, including a change from active treatment to surveillance</li> </ul>	<ul style="list-style-type: none"> <li>◆ PET/CT (CPT® 78815)                             <ul style="list-style-type: none"> <li>■ Whole-body PET/CT (CPT® 78816) if there is clinical suspicion of skull or distal lower extremity involvement</li> <li>■ Once PET has been documented to be negative for a given individual's cancer or all PET-avid disease has been surgically resected, PET should not be used for continued disease monitoring or surveillance unless one of the exceptions in section <b>General Guidelines (PEDONC-1)</b> applies.</li> </ul> </li> </ul>
<p>Restaging following local control surgery</p>	<p><u>ALL of the following:</u></p> <ul style="list-style-type: none"> <li>◆ CT with contrast or MRI without and with contrast of the primary site</li> </ul>

Indication	Imaging Study
	<ul style="list-style-type: none"> <li>◆ Imaging of all known metastatic sites using the same conventional imaging modality as per initial staging</li> </ul>
<p>Surveillance, localized NRSTS treated with chemotherapy</p>	<p><u>Every 6 months for 5 years after completion of all therapy:</u></p> <ul style="list-style-type: none"> <li>◆ CT with contrast or MRI without and with contrast of the primary site AND</li> </ul> <p>Every 6 months for 3 years after completion of all therapy:</p> <ul style="list-style-type: none"> <li>◆ CT Chest with (CPT® 71260) or CT Chest without contrast (CPT® 71250).                             <ul style="list-style-type: none"> <li>■ CT Chest only supported for new symptoms or new findings on chest x-ray thereafter.</li> </ul> </li> </ul>
<p>Surveillance, localized NRSTS treated with resection (with or without radiation)</p>	<p><u>Every 3 months for the first 12 months, then every 6 months in years 2-5 to complete 5 years surveillance after completion of therapy:</u></p> <ul style="list-style-type: none"> <li>◆ CT with contrast or MRI without and with contrast of the primary site AND</li> </ul> <p><u>Every 6 months for 3 years after completion of all therapy:</u></p> <ul style="list-style-type: none"> <li>◆ CT Chest with (CPT® 71260) or CT Chest without contrast (CPT® 71250)                             <ul style="list-style-type: none"> <li>■ CT Chest only supported for new symptoms or new findings on chest x-ray thereafter.</li> </ul> </li> </ul>
<p>Surveillance of metastatic NRSTS, and no prior history of disease in the chest</p>	<p><u>ALL of the following, after completion of all therapy, every 6 months for 5 years:</u></p> <ul style="list-style-type: none"> <li>◆ CT with contrast or MRI without and with contrast of primary site</li> <li>◆ CT with contrast of all known metastatic sites                             <ul style="list-style-type: none"> <li>■ Nuclear bone scan (see: <b>PEDONC-1.3</b> for coding) for surveillance of known bony metastases</li> </ul> </li> </ul>

Indication	Imaging Study
	<p>AND                      Every 6 months for 3 years:</p> <ul style="list-style-type: none"> <li>◆ CT Chest with (CPT® 71260) or CT Chest without contrast (CPT® 71250)</li> </ul>
<p>Surveillance of metastatic NRSTS, and known prior history of metastatic disease in the chest</p>	<p><u>ALL of the following, after completion of all therapy, every 6 months for 5 years:</u></p> <ul style="list-style-type: none"> <li>◆ CT with contrast or MRI without and with contrast of primary site</li> <li>◆ CT Chest with (CPT® 71260) or without contrast (CPT® 71250)</li> <li>◆ CT with contrast of all known metastatic sites</li> <li>◆ Nuclear bone scan (see: <b>PEDONC-1.3</b> for coding) for surveillance of known bony metastases</li> </ul>
<p>Surveillance, recurrent NRSTS</p>	<p><u>ALL of the following after successful treatment for recurrent disease, every 3 months for 1 year:</u></p> <ul style="list-style-type: none"> <li>◆ CT Chest (CPT® 71260) with contrast</li> <li>◆ CT with contrast or MRI without and with contrast of the primary site</li> </ul> <p>➤ Surveillance in years 2 through 5 after completing therapy for recurrence should follow the standard timing listed in the appropriate surveillance section</p>
<p>ANY of the following:</p> <ul style="list-style-type: none"> <li>◆ Conventional imaging (CT, MRI, US, plain film) during surveillance reveals findings that are inconclusive or suspicious for recurrence, and PET avidity will determine whether biopsy or continued observation is appropriate</li> <li>◆ Obvious clinical symptoms show strong evidence suggesting recurrent and PET would replace conventional imaging modalities</li> </ul>	<ul style="list-style-type: none"> <li>◆ PET/CT (CPT® 78815)                             <ul style="list-style-type: none"> <li>■ Whole-body PET/CT (CPT® 78816) if there is clinical suspicion of skull or distal lower extremity involvement</li> </ul> </li> </ul>

## Background and Supporting Information

- All soft tissue sarcomas other than RMS fall into this category
- Because soft tissue sarcomas can arise from any soft tissue, the presenting symptoms and primary tumor sites vary widely and strongly influence the appropriate imaging decisions
- CT Abdomen and Pelvis with contrast (CPT® 74177) is not routinely indicated in the initial metastatic staging of pediatric NRSTS
- Many individuals with NRSTS will be treated with surgical resection alone, and these individuals enter immediately into surveillance
- PET imaging is not routinely utilized to assess treatment response in NRSTS
- PET imaging is generally not indicated during active treatment for recurrent pediatric cancer.
- Residual mass that has not changed in size since the last conventional imaging does not justify PET
- PET avidity in a residual mass at the end of planned therapy is not an indication for PET imaging during surveillance

## References

1. Wexler LH, Skapek SX, Helman LJ. Rhabdomyosarcoma. In: Pizzo PA, Poplack DG, eds. Principles and Practice of Pediatric Oncology. 7th edition. Philadelphia, PA: Wolters Kluwer; 2016:798-826.
2. Spunt SL, Million L, and Coffin C. The Nonrhabdomyosarcoma soft tissue sarcomas. In: Pizzo PA, Poplack DG, eds. Principles and Practice of Pediatric Oncology. 7th edition. Philadelphia, PA: Wolters Kluwer; 2016:827-854.
3. Womer RB, Barr FG, Linardic CM. Rhabdomyosarcoma. In: Orkin SH, Fisher DE, Ginsburg D, Look AT, Lux SE, Nathan DG, eds. Nathan and Oski's Hematology and Oncology of Infancy and Childhood. 8th edition. Philadelphia, PA: Elsevier Saunders; 2015:1906-1945.
4. Davis IJ, Perez-Atayde AR, Fisher DE. Nonrhabdomyosarcoma soft tissue sarcomas and other soft tissue tumors. In: Orkin SH, Fisher DE, Ginsburg D, Look AT, Lux SE, Nathan DG, eds. Nathan and Oski's Hematology and Oncology of Infancy and Childhood. 8th edition. Philadelphia, PA: Elsevier Saunders; 2015:1946-1982.
5. McCarville MB. What MRI can tell us about neurogenic tumors and rhabdomyosarcoma. *Pediatr Radiol*. 2016;46(6):881-890. doi:10.1007/s00247-016-3572-4.
6. Federico SM, Spunt SL, Krasin MJ, et al. Comparison of PET-CT and Conventional Imaging in staging pediatric rhabdomyosarcoma. *Pediatr Blood Cancer*. 2013;60(7):1128-1134. doi:10.1002/psc.24430.
7. Dharmarajan KV, Wexler LH, Gavane S, et al. Positron Emission Tomography (PET) evaluation after initial chemotherapy and radiation therapy predicts local control in rhabdomyosarcoma. *Int J Radiat Biol Oncol Phys*. 2012;84(4):996-1002. doi:10.1016/j.ijrobp.2012.01.077.
8. Arnold MA, Anderson JA, Gastier-Foster JM, et al. Histology, fusion status, and outcome in alveolar rhabdomyosarcoma with low-risk clinical features: a report from the Children's Oncology Group. *Pediatr Blood Cancer*. 2016;63(4):634-639. doi:10.1002/pbc.25862.
9. Völker T, Denecke T, Steffen I, et al. Positron Emission Tomography for staging of pediatric sarcoma patients: results of a prospective multicenter trial. *J Clin Oncol*. 2007; 25(34):5435-5441. doi:10.1200/JCO.2007.12.2473.
10. Ostermeier A, McCarville MB, Navid F, et al. FDG PET/CT imaging of desmoplastic small round cell tumor: findings at staging, during treatment and at follow-up. *Pediatr Radiol*. 2015;45(9):1308-1315. doi:10.1007/s00247-015-3315-y.
11. Uslu L, Doing J, Link M, Rosenberg J, Quon A, Daldrup-Link HE. Value of 18F-FDG PET and PET/CT for evaluation of pediatric malignancies. *J Nucl Med*. 2015;56(2):274-286. doi:10.2967/jnumed.114.146290.
12. Roberts CC, Kransdorf MJ, Beaman FD, et al. Follow-Up of malignant or aggressive musculoskeletal tumors. ACR Appropriateness Criteria® 2015:1-15.Revised: 2022. <https://acsearch.acr.org/docs/69428/Narrative/>.
13. Ferrari A, Chi Y-Y, De Salvo GL, et al. Surgery alone is sufficient therapy for children and adolescents with low-risk synovial sarcoma: a joint analysis from the European paediatric soft tissue sarcoma Study Group and the Children's Oncology Group. *Eur J Cancer*. 2017;78:1-6. doi:10.1016/j.ejca.2017.03.003.
14. Spunt SL, Million L, Chi YY, et. al. A risk-based treatment strategy for non-rhabdomyosarcoma soft-tissue sarcomas in patients younger than 30 years (ARST0332): a Children's Oncology Group prospective study. *Lancet Oncol*. 2020;21(1):145-161. doi:10.1016/S1470-2045(19)30672-2.



<b>Bone Tumors (PEDONC-9)</b>
<b>Bone Tumors – General Considerations (PEDONC-9.1)</b>
<b>Benign Bone Tumors (PEDONC-9.2)</b>
<b>Osteogenic Sarcoma (OS) (PEDONC-9.3)</b>
<b>Ewing Sarcoma Family of Tumors (ESFT), Including Primitive Neuroectodermal Tumors (PNET) (PEDONC-9.4)</b>

## **Bone Tumors – General Considerations (PEDONC-9.1)**

These guidelines include both benign and malignant lesions.

- Unless specified below, individuals who are <18 years old should be imaged according to this guideline section. Exceptions include:
  - ◆ Osteogenic sarcoma individuals of all ages should be imaged according to guidelines in **Osteogenic Sarcoma (OS) (PEDONC-9.3)**
  - ◆ Ewing Sarcoma and Primitive Neuroectodermal Tumor individuals of all ages should be imaged according to guidelines in **Ewing Sarcoma and Primitive Neuroectodermal Tumors (ESFT) (PEDONC-9.4)**
  - ◆ Chondrosarcoma individuals of all ages should be imaged according to guidelines in **Bone Sarcomas – Initial Work-up/Staging (ONC-12.6)**
  - ◆ Chordoma individuals of all ages should be imaged according to guidelines in **Bone Sarcomas – Initial Work-up/Staging (ONC-12.6)**
  - ◆ Giant cell tumor of bone and enchondroma individuals of all ages should be imaged according to guidelines in **Benign Bone Tumors – General Considerations (ONC-12.9)**
  - ◆ Other benign bone tumor individuals of all ages should be imaged according to guidelines in **Benign Bone Tumors (PEDONC-9.2)**
- Prosthetic devices for children after surgery for bony tumors are nearly all customized.
  - ◆ CT, contrast as requested in alignment with prosthetic manufacturer specifications, is appropriate when requested by the operating surgeon for planning for customized-to-individual joint replacement or prosthetic surgery
- All bone tumors should be evaluated by plain x-ray prior to any advanced imaging
- PET does not reliably distinguish between benign and malignant bone tumors and should not be performed prior to biopsy.
- Where indications for PET/CT are noted, please note that indications and coding for rare circumstances where PET/MRI may be approved are found in **PET Imaging in Pediatric Oncology (PEDONC-1.4)**
- CT Chest is superior to PET/CT for the detection of pulmonary metastases, and is indicated in the initial workup of all suspected malignant bone tumors.
  - ◆ CT Chest should be completed prior to anesthesia exposure, if possible.

## **Benign Bone Tumors (PEDONC-9.2)**

- Osteochondroma

Indication	Imaging Study
Preoperative planning	<ul style="list-style-type: none"> <li>➤ MRI without and with contrast can be approved after evaluation by the operating surgeon</li> <li>➤ See: <b><u>General Considerations (PEDONC-9.1)</u></b> for requests related to prosthetic planning</li> </ul>

Indication	Imaging Study
<ul style="list-style-type: none"> <li>➤ ANY of the following:                             <ul style="list-style-type: none"> <li>◆ Concern for malignant transformation</li> <li>◆ New or worsening pain/symptoms</li> <li>◆ Change on a recent plain x-ray</li> </ul> </li> </ul>	<ul style="list-style-type: none"> <li>➤ MRI without contrast or without and with contrast</li> </ul>

➤ Osteoid osteoma

Indication	Imaging Study
Suspected, based on clinical history and plain film findings	<ul style="list-style-type: none"> <li>➤ CT without contrast</li> </ul>
<ul style="list-style-type: none"> <li>➤ ANY of the following:                             <ul style="list-style-type: none"> <li>◆ CTs are not characteristic for diagnosis</li> <li>◆ Individual has bone pain not localized to the area of findings on CT or x-ray</li> </ul> </li> </ul>	<ul style="list-style-type: none"> <li>➤ ONE of the following:                             <ul style="list-style-type: none"> <li>◆ Triple phase bone scan (CPT® 78315)</li> <li>◆ SPECT (CPT® 78803)</li> <li>◆ Hybrid SPECT/CT (CPT® 78830)</li> </ul> </li> </ul>
<ul style="list-style-type: none"> <li>➤ Individuals with new pain who have been previously treated with radiofrequency ablation or curettage</li> </ul>	<ul style="list-style-type: none"> <li>➤ Bone scan (CPT® code 78830, 78315, or 78803 – as requested)</li> </ul>

➤ Other benign tumors

- ◆ Refer to **Mass Involving Bone (Including suspected Lytic and Blastic Metastatic Disease) (PEDMS-3.4)**

**Background and Supporting Information**

- Plain x-ray appearance is diagnostic for many benign bone tumors, and advanced imaging is generally unnecessary except for preoperative planning
- Plain x-ray appearance is diagnostic for osteochondroma for the majority of individuals and advanced imaging is generally unnecessary

## Osteogenic Sarcoma (OS) (PEDONC-9.3)

Indication	Imaging Study
Suspected or Biopsy Proven Diagnosis	<ul style="list-style-type: none"> <li>➤ MRI without and with contrast of the primary site OR</li> <li>➤ CT, contrast as request, of the primary site if there is a contraindication to MRI</li> <li>AND</li> <li>➤ CT Chest with (CPT® 71260) or without contrast (CPT® 71250)                             <ul style="list-style-type: none"> <li>◆ CT Chest is indicated in initial workup of all suspected malignant bone tumors in children and should be completed prior to anesthesia exposure if possible</li> </ul> </li> <li>➤ These studies may be approved even when PET/CT has already been authorized or performed</li> </ul>
Initial Staging of Biopsy Proven Disease	<ul style="list-style-type: none"> <li>➤ PET/CT whole-body (CPT® 78816)                             <ul style="list-style-type: none"> <li>◆ Nuclear bone scan (see: <b>PEDONC-1.3</b> for coding) may be substituted if PET not available</li> <li>◆ PET/CT may be approved in addition to the conventional imaging listed in the suspected/diagnosis sections</li> </ul> </li> <li>➤ CT Abdomen and Pelvis with contrast (CPT® 74177) is not routinely indicated in the initial metastatic staging of pediatric OS but can be approved in the following situations:                             <ul style="list-style-type: none"> <li>◆ Evaluation of inconclusive PET findings</li> <li>◆ Primary site of abdomen or pelvis</li> </ul> </li> </ul>
Suspected bony metastatic sites noted on PET or bone scan	<ul style="list-style-type: none"> <li>➤ MRI without and with contrast of the suspected metastatic site OR</li> <li>➤ CT with contrast of the suspected metastatic site</li> </ul>
Restaging after 10 to 12 weeks of neoadjuvant chemotherapy prior to local control surgery	<ul style="list-style-type: none"> <li>➤ MRI without and with contrast of primary site</li> <li>➤ CT Chest with (CPT® 71260) or without contrast (CPT® 71250)</li> <li>➤ PET/CT whole-body (CPT® 78816) or bone scan (see: <b>PEDONC-1.3</b> for coding)</li> </ul>

Indication	Imaging Study
Individuals with metastatic disease undergoing current chemotherapy	<ul style="list-style-type: none"> <li>➤ CT Chest with (CPT®) or without contrast (CPT® 71250) can be performed every 2 cycles during treatment and at the end of planned chemotherapy</li> <li>➤ MRI without and with contrast of primary site can be performed every 2 cycles during treatment and at the end of planned chemotherapy</li> <li>➤ If previously positive for bony metastases, PET/CT whole-body (CPT® 78816) or bone scan (see: <b>PEDONC-1.3</b> for coding) every 2 cycles during treatment and at the end of planned chemotherapy</li> <li>➤ Imaging may be indicated more frequently around the time of surgical resection of primary or metastatic lesions to assess for resectability</li> </ul>
Preoperative planning for local control surgery	<ul style="list-style-type: none"> <li>➤ CT, contrast as requested</li> <li>➤ MRA and/or CTA may rarely be indicated for complicated surgical resections, and can be approved after evaluation by the operating surgeon to clarify inconclusive MRI findings for preoperative planning</li> <li>➤ See: <b>General Considerations (PEDONC-9.1)</b> for advancing imaging requests related to prosthetic planning</li> </ul>
Following local control surgery, until the end of planned adjuvant chemotherapy	<ul style="list-style-type: none"> <li>➤ MRI without and with contrast of primary site ~6 weeks after surgical procedure, and at the end of planned chemotherapy</li> <li>➤ Plain x-rays of the primary site and chest immediately after local control and then every 2 months between the supported, listed advanced imaging studies.</li> <li>➤ CT Chest with (CPT® 71260) or without contrast (CPT® 71250): <ul style="list-style-type: none"> <li>◆ Measurable pulmonary metastases: every 6 weeks, and at the end of planned chemotherapy</li> <li>◆ No measurable pulmonary metastases: every 4 months, and at the end of planned chemotherapy</li> </ul> </li> <li>➤ Bone scan (see: <b>PEDONC-1.3</b> for coding) every 4 months, and at the end of planned chemotherapy <ul style="list-style-type: none"> <li>◆ PET/CT whole-body (CPT® 78816) can be used in place of bone scan, if positive for distant bone metastases at initial diagnosis</li> </ul> </li> </ul>

Indication	Imaging Study
<p>Recurrent metastatic or recurrent unresectable disease on treatment</p>	<ul style="list-style-type: none"> <li>➤ The following may be approved every 2 cycles of treatment, and at the end of planned chemotherapy:                             <ul style="list-style-type: none"> <li>◆ CT Chest with (CPT® 71260) or without contrast (CPT® 71250)</li> <li>◆ MRI without and with contrast of primary site can be performed every 2 cycles during treatment and at the end of planned chemotherapy</li> <li>◆ PET is generally not indicated during active treatment for recurrent pediatric cancer. In rare circumstances, PET/CT imaging with CPT® 78816 may be appropriate when results are likely to result in a treatment change for the individual, including a change from active treatment to surveillance.</li> </ul> </li> </ul>
<p>Surveillance (all individuals regardless of primary site)</p>	<ul style="list-style-type: none"> <li>➤ CT or MRI of primary site as performed during suspected or initial disease workup (provided the individual does not have an endoprosthesis that will cause MRI or CT artifact):                             <ul style="list-style-type: none"> <li>◆ Every 3 months for 1 year, then every 4 months for 1 year, then every 6 months for 1 year, then annually for 2 years after completion of all therapy</li> </ul> </li> <li>➤ CT Chest with (CPT® 71260) or without contrast (CPT® 71250) every 3 months for 1 year, then every 4 months for 1 year after completion of all therapy                             <ul style="list-style-type: none"> <li>◆ After 24 months, chest x-ray (CXR) should be used for pulmonary recurrence surveillance, and CT Chest can be approved to clarify inconclusive CXR findings</li> </ul> </li> <li>➤ Bone scan (see: <b>PEDONC-1.3</b> for coding) every 3 months for 1 year, then every 4 months for 1 year, then every 6 months for 1 year, then annually for 2 years after completion of all therapy</li> </ul>
<p>Additional surveillance for individuals with recurrent or metastatic disease</p>	<ul style="list-style-type: none"> <li>➤ CT Chest with (CPT® 71260) or without contrast (CPT® 71250) every 3 months for 1 year, then every 4 months for 1 year, then every 6 months for 1 year, then annually for 2 years after completion of all therapy                             <ul style="list-style-type: none"> <li>◆ Bone scan (see: <b>PEDONC-1.3</b> for coding) should be used for evaluation of distant bony metastases every 3 months for 1 year, then every 6 months for 2 years, then annually for 2 years after completion of all therapy</li> </ul> </li> </ul>

Indication	Imaging Study
Suspected recurrence	<ul style="list-style-type: none"> <li>➤ MRI without and with contrast of the primary site and /or site of suspected recurrence based on symptoms or other imaging OR</li> <li>➤ CT, contrast as request, of the primary site and /or site of suspected recurrence based on symptoms or other imaging if there is a contraindication to MRI</li> </ul> <p>AND</p> <ul style="list-style-type: none"> <li>➤ CT Chest with (CPT® 71260) or without contrast (CPT® 71250)                             <ul style="list-style-type: none"> <li>◆ CT Chest is indicated in initial workup of all suspected malignant bone tumors in children and should be completed prior to anesthesia exposure if possible</li> </ul> </li> <li>➤ CT Abdomen and Pelvis with contrast (CPT® 74177) is not routinely indicated in the metastatic staging of pediatric OS, but can be approved in the following situations:                             <ul style="list-style-type: none"> <li>◆ Evaluation of inconclusive PET findings</li> <li>◆ Primary site of abdomen or pelvis</li> </ul> </li> </ul> <p>These studies may be approved even when PET/CT has already been authorized or performed</p>
<ul style="list-style-type: none"> <li>➤ For suspected recurrence, ANY of the following:                             <ul style="list-style-type: none"> <li>◆ Conventional imaging reveals findings that are inconclusive or suspicious for recurrence and PET avidity will determine whether biopsy or continued observation is appropriate</li> <li>◆ Rare circumstances where obvious clinical symptoms show strong evidence suggesting recurrence and PET would replace conventional imaging modalities</li> </ul> </li> </ul>	<ul style="list-style-type: none"> <li>➤ PET/CT                             <ul style="list-style-type: none"> <li>◆ If PET is approved in osteosarcoma, it should be whole-body PET/CT (CPT® 78816)</li> </ul> </li> </ul>
<ul style="list-style-type: none"> <li>➤ Biopsy proven recurrence</li> </ul>	<ul style="list-style-type: none"> <li>➤ PET/CT whole-body (CPT® 78816) may be approved for biopsy proven recurrence                             <ul style="list-style-type: none"> <li>◆ If disease is considered potentially resectable, follow osteosarcoma treatment response as previous</li> </ul> </li> </ul>

## Ewing Sarcoma Family of Tumors (ESFT), Including Primitive Neuroectodermal Tumors (PNET) (PEDONC-9.4)

Indication	Imaging Study
Suspected/Diagnosis – ill-defined or non-discrete soft tissue mass without bony involvement	<ul style="list-style-type: none"> <li>➤ US (CPT® 76881 or 76882)</li> </ul>
Suspected or Biopsy Proven Diagnosis – Primary site	<ul style="list-style-type: none"> <li>➤ MRI without and with contrast                             <ul style="list-style-type: none"> <li>◆ CT, contrast as requested, if there is a contraindication to MRI</li> </ul> </li> <li>➤ MRA and/or CTA may rarely be indicated for complicated surgical resections, and can be approved after evaluation by the operating surgeon to clarify inconclusive MRI findings for preoperative planning</li> <li>➤ CT Chest with (CPT® 71260) or without contrast (CPT® 71250)                             <ul style="list-style-type: none"> <li>◆ CT Chest is indicated in initial workup of all suspected or confirmed malignant bone tumors in children and should be completed prior to anesthesia exposure if possible</li> </ul> </li> <li>➤ These studies may be approved even when PET/CT has already been authorized or performed</li> </ul>
Suspected or Biopsy Proven Diagnosis – Chest wall primary	<ul style="list-style-type: none"> <li>➤ MRI Chest without and with contrast AND</li> <li>➤ CT Chest with (CPT® 71260) or without contrast (CPT® 71250)                             <ul style="list-style-type: none"> <li>◆ CT Chest is indicated in initial workup of all suspected or confirmed malignant bone tumors in children and should be completed prior to anesthesia exposure if possible</li> </ul> </li> <li>➤ These studies may be approved even when PET/CT has already been authorized or performed</li> </ul>
Initial Staging (additional imaging after biopsy confirmed disease)	<ul style="list-style-type: none"> <li>➤ PET/CT whole-body (CPT® 78816)                             <ul style="list-style-type: none"> <li>◆ Bone scan (see: <b>PEDONC-1.3</b> for coding) may be substituted for PET imaging if PET not available</li> <li>◆ PET/CT may be approved in addition to the conventional imaging listed in the suspected/diagnosis sections</li> </ul> </li> </ul>



Indication	Imaging Study
<ul style="list-style-type: none"> <li>➤ For ANY of the following:                             <ul style="list-style-type: none"> <li>◆ Evaluation of inconclusive PET findings</li> <li>◆ Primary site involving the abdomen or pelvis</li> </ul> </li> </ul>	<ul style="list-style-type: none"> <li>➤ CT Abdomen and Pelvis with contrast (CPT® 74177)</li> </ul>
<p>Restaging after 10 to 12 weeks of neoadjuvant chemotherapy prior to local control surgery</p>	<ul style="list-style-type: none"> <li>➤ MRI without and with contrast of the primary site</li> <li>➤ CT (contrast as requested) may be approved if requested per valuation by the operating surgeon for pre-operative planning                             <ul style="list-style-type: none"> <li>◆ See: <b>General Considerations (PEDONC-9.1)</b> for imaging requests related to prosthetic planning</li> </ul> </li> <li>➤ CT Chest with (CPT® 71260) or without contrast (CPT® 71250)</li> <li>➤ PET/CT whole-body (CPT® 78816) or bone scan (see: <b>PEDONC-1.3</b> for coding)</li> </ul>
<p>Treatment response following local control surgery</p>	<ul style="list-style-type: none"> <li>➤ MRI without and with contrast of primary site 3 months after surgical procedure and at the end of planned chemotherapy</li> <li>➤ Plain x-rays of the primary site and chest immediately after local control then every 3 months</li> <li>➤ CT Chest with (CPT® 71260) or without contrast (CPT® 71250):                             <ul style="list-style-type: none"> <li>◆ Measurable pulmonary metastases: every 6 weeks and at the end of planned chemotherapy</li> <li>◆ No measurable pulmonary metastases: every 3 months and at the end of planned chemotherapy</li> </ul> </li> <li>➤ PET/CT whole-body (CPT® 78816) or bone scan (see: <b>PEDONC-1.3</b> for coding) at the end of planned chemotherapy</li> </ul>

Indication	Imaging Study
<p>Individuals with metastatic disease undergoing current chemotherapy</p>	<ul style="list-style-type: none"> <li>➤ CT Chest with (CPT® 71260) or without contrast (CPT® 71250) can be performed every 2 cycles during treatment and at the end of planned chemotherapy</li> <li>➤ MRI without and with contrast of primary site can be performed every 2 cycles during treatment and at the end of planned chemotherapy</li> <li>➤ If previously positive for bony metastases, whole-body PET/CT whole-body (CPT® 78816) or bone scan (see: <b>PEDONC-1.3</b> for coding) every 2 cycles during treatment and at the end of planned chemotherapy</li> <li>➤ Imaging may be indicated more frequently around the time of surgical resection of primary or metastatic lesions to assess for resectability</li> </ul>
<p>Recurrent metastatic or recurrent unresectable disease on treatment</p>	<ul style="list-style-type: none"> <li>➤ The following may be approved every 2 cycles of treatment, and at the end of planned chemotherapy:                             <ul style="list-style-type: none"> <li>◆ CT Chest with (CPT® 71260) or without contrast (CPT® 71250)</li> <li>◆ MRI without and with contrast of primary site can be performed every 2 cycles during treatment and at the end of planned chemotherapy</li> <li>◆ PET is generally not indicated during active treatment for recurrent pediatric cancer. In rare circumstances, PET imaging may be appropriate when results are likely to result in a treatment change for the individual, including a change from active treatment to surveillance.</li> </ul> </li> </ul>

Indication	Imaging Study
Surveillance – any primary site	<ul style="list-style-type: none"> <li>➤ Plain film x-rays AND</li> <li>➤ MRI without and with contrast OR CT with contrast of the primary tumor site:               <ul style="list-style-type: none"> <li>◆ Every 3 months for 1 year, then every 4 months for 1 year, then every 6 months for 1 year, then annually for 2 years after completion of all therapy</li> </ul> </li> <li>➤ Bone scan (see: <b><u>PEDONC-1.3</u></b> for coding) every 3 months for one year, then every 4 months for one year, then every 6 months for one year, and then annually for 2 years after completion of all therapy</li> <li>➤ CT Chest with (CPT® 71260) or without contrast (CPT® 71250) every 3 months for 1 year then every 4 months for 1 year after completion of all therapy</li> <li>➤ Individuals with metastatic or recurrent ESFT may have CT Chest annually for an additional two years (for a total of four years of surveillance)</li> <li>➤ For individuals with localized ESFT, Chest x-ray (CXR) should be used for pulmonary recurrence surveillance after the initial 24 months of surveillance, and CT Chest can be approved to clarify inconclusive CXR findings</li> </ul>

Indication	Imaging Study
<ul style="list-style-type: none"> <li>➤ Suspected Recurrence</li> </ul>	<ul style="list-style-type: none"> <li>➤ MRI without and with contrast of the primary site and/or site of suspected recurrence based on symptoms or other imaging, OR</li> <li>➤ CT, contrast as request, of the primary site and/or site of suspected recurrence based on symptoms or other imaging if there is a contraindication to MRI</li> <li>AND</li> <li>➤ CT Chest with (CPT® 71260) or without contrast (CPT® 71250)                             <ul style="list-style-type: none"> <li>◆ CT Chest is indicated in initial workup of all suspected malignant bone tumors in children and should be completed prior to anesthesia exposure if possible</li> </ul> </li> <li>➤ CT Abdomen and Pelvis with contrast (CPT® 74177) is not routinely indicated in the metastatic staging of pediatric EWS but can be approved in the following situations:                             <ul style="list-style-type: none"> <li>◆ Evaluation of inconclusive PET findings</li> <li>◆ Primary site of abdomen or pelvis</li> </ul> </li> <li>➤ These studies may be approved even when PET/CT has already been authorized or performed</li> </ul>
<ul style="list-style-type: none"> <li>➤ For suspected recurrence, any of the following:                             <ul style="list-style-type: none"> <li>◆ Conventional imaging reveals findings that are inconclusive or suspicious for recurrence and PET avidity will determine whether biopsy or continued observation is appropriate</li> <li>◆ Rare circumstances where obvious clinical symptoms show strong evidence suggesting recurrence and PET would replace conventional imaging modalities</li> </ul> </li> </ul>	<ul style="list-style-type: none"> <li>➤ PET/CT whole-body (CPT® 78816)</li> </ul>
<ul style="list-style-type: none"> <li>➤ Biopsy proven recurrence</li> </ul>	<ul style="list-style-type: none"> <li>➤ Refer to ESFT initial imaging for studies for suspected recurrence.</li> <li>➤ PET/CT whole-body (CPT® 78816)</li> <li>➤ If disease is considered potentially resectable, follow ESFT treatment response as previously noted</li> </ul>

## Background and Supporting Information

- Bone and bone marrow metastases can occur in ESFT, and cause a significant change in treatment approach.
- PET/CT can replace bone scan and bone marrow biopsy in ESFT individuals and is indicated in the initial staging of all ESFT individuals after histologic diagnosis is established

## References

1. Hawkins DS, Brennan BMD, Bölling T, et al. Ewing Sarcoma. In: Pizzo PA, Poplack DG, eds. Principles and Practice of Pediatric Oncology. 7th edition. Philadelphia, PA: Wolters Kluwer; 2016:855-876.
2. Gorlick R, Janeway K, and Marina N. Osteosarcoma. In: Pizzo PA, Poplack DG, eds. Principles and Practice of Pediatric Oncology. 7th edition. Philadelphia, PA: Wolters Kluwer; 2016:877-898.
3. DuBois SG, Grier HE, and Lessnick SL. Ewing Sarcoma. In: Orkin SH, Fisher DE, Ginsburg D, Look AT, Lux SE, Nathan DG, eds. Nathan and Oski's Hematology and Oncology of Infancy and Childhood. 8th edition. Philadelphia, PA: Elsevier Saunders; 2015:1983-2017.
4. Janeway KA. Osteosarcoma. In: Orkin SH, Fisher DE, Ginsburg D, Look AT, Lux SE, Nathan DG, eds. Nathan and Oski's Hematology and Oncology of Infancy and Childhood. 8th edition. Philadelphia, PA: Elsevier Saunders; 2015:2018-2055.
5. Azouz EM. Magnetic resonance imaging of benign bone lesions: cysts and tumors. Top Magn Reson Imaging. 2002 August;13(4):219-230.
6. Wolf M. Knee pain in children, part III: stress injuries, benign bone tumors, growing pains. Pediatr Rev. 2016;37(3):114-119. doi:10.1542/pir.2015-0042.
7. Uslu L, Doing J, Link M, Rosenberg J, Quon A, Daldrup-Link HE. Value of 18F-FDG PET and PET/CT for Evaluation of Pediatric Malignancies. J Nucl Med. 2015;56(2):274-286. doi:10.2967/jnumed.114.146290.
8. Reed DR, Hayashi M, Wagner L, et al. Treatment pathway of bone sarcoma in children, adolescents, and young adults. Cancer. 2017 March;123(12):2206-2218.
9. Hurley C, McCarville MB, Shulkin BL, et al. Comparison of 18F-FDG-PET-CT and Bone Scintigraphy for evaluation of osseous metastases in newly diagnosed and recurrent osteosarcoma. Pediatr Blood Cancer. 2016;63(8):1381-1386. Accessed January 4, 2018. doi:10.1002/pbc.26014.
10. Byun BH, Kong CB, Lim I, et al. Comparison of (18)F-FDG PET/CT and (99m)TC-MDP bone scintigraphy for detection of bone metastasis in osteosarcoma. Skeletal Radiol. 2013;42(12):1673-1681.
11. Quartuccio N, Treglia G, Saisano M, et al. The role of Fluorine-18-Fluorodeoxyglucose positron emission tomography in staging and restaging of patients with osteosarcoma. Radiol Oncol. 2013;47(2):97-102. doi:10.2478/raon-2013-0017.
12. Isakoff MS, Bielack SS, Meltzer P, Gorlick R. Osteosarcoma: current treatment and a collaborative pathway to success. J Clin Oncol. 2015;33(27):3029-3035. doi:10.1200/JCO.2014.59.4895.
13. Newman EN, Jones RL, Hawkins DS. An evaluation of [F-18]-Fluorodeoxy-D-Glucose positron emission tomography, bone scan, and bone marrow aspiration/biopsy as staging investigations in Ewing sarcoma. Pediatr Blood Cancer. 2013;60(7):1113-1117. doi:10.1002/pbc.24406.
14. Roberts CC, Kransdorf MJ, Beaman FD, et al. Follow-up of malignant or aggressive musculoskeletal tumors. ACR Appropriateness Criteria® 2015:1-15. Revised: 2022. <https://acsearch.acr.org/docs/69428/Narrative/>.
15. Meyer JS, Nadel HR, Marina N, et al. Imaging guidelines for children with Ewing sarcoma and osteosarcoma: a report from the Children's Oncology Group Bone Tumor Committee. Pediatr Blood Cancer. 2008;51(2):163-170. doi:10.1002/pbc.21596.
16. Gaspar N, Hawkins DS, Dirksen U, et al. Ewing sarcoma: current management and future approaches through collaboration. J Clin Oncol. 2015;33(27):3036-3046. doi:10.1200/JCO.2014.59.5256.
17. Mascarenhas L, Felgenhauer JL, Bond MC, et al. Pilot study of adding vincristine, topotecan, and cyclophosphamide to interval-compressed chemotherapy in newly diagnosed patients with localized Ewing sarcoma: a report from the Children's Oncology Group. Pediatr Blood Cancer. 2016;63(3):493-498. doi:10.1002/pbc.25837.
18. Weiser DA, Kaste SC, Siegel MJ, et al. Imaging in childhood cancer: a society for pediatric radiology and children's oncology group joint task force report. Pediatr Blood Cancer. 2013;60(8):1253-1260. doi:10.1002/pbc.24533.
19. Dimitrakopoulou-Strauss A, Strauss LG, Heichel T, et al. The role of quantitative 18F-FDG PET studies for the differentiation of malignant and benign bone lesions. J Nucl Med. 2002;43(4):510-518.
20. Bestic JM, Wessell DE, Beaman FD, et al. Primary bone tumors. ACR Appropriateness Criteria®, 2019;1-13. Date of origin: 1995 Revised: 2019 <https://acsearch.acr.org/docs/69421/Narrative/>.
21. Biermann JS, Chow W, Adkins DR, et al. National Comprehensive Cancer Network (NCCN) Guidelines Version 1.2023 – August 2, 2022. Bone cancer, available at: [https://www.nccn.org/professionals/physician\\_gls/pdf/bone.pdf](https://www.nccn.org/professionals/physician_gls/pdf/bone.pdf). Referenced with permission from the NCCN Clinical Practice Guidelines in Oncology (NCCN Guidelines™) for Bone Cancer V1.2023– August 2, 2022. ©2022 National Comprehensive Cancer Network, Inc. All rights reserved. The NCCN Guidelines™ and illustrations

herein may not be reproduced in any form for any purpose without the express written permission of the NCCN. To view the most recent and complete version of the NCCN Guidelines™, go online to NCCN.org.

22. Jeys L, Abudu A, Grimer R. Expandable prostheses. In: Wiesel SW, ed. Operative Techniques in Orthopaedic Surgical Oncology. Philadelphia, PA: Lippincott Williams & Wilkins; 2015:1-9.
23. PDQ® Pediatric Treatment Editorial Board. PDQ Osteosarcoma and Malignant Fibrous Histiocytoma of Bone Treatment. Bethesda, MD: National Cancer Institute. Updated 6/8/2022. Available at: <https://www.cancer.gov/types/bone/hp/osteosarcoma-treatment-pdq>. [PMID: 26389179]

## Pediatric Germ Cell Tumors (PEDONC-10)

Indication	Imaging Study
Initial staging	<ul style="list-style-type: none"> <li>➤ CT Abdomen/Pelvis with contrast (CPT® 74177)                             <ul style="list-style-type: none"> <li>◆ Testicular primary tumors can defer abdominal imaging until after histologic confirmation at the discretion of the operating surgeon</li> </ul> </li> <li>➤ CT Chest with contrast (CPT® 71260)                             <ul style="list-style-type: none"> <li>◆ Should be completed prior to anesthesia exposure if possible</li> </ul> </li> </ul>
Clarify inconclusive initial staging CT findings or for a known contraindication to CT contrast	<ul style="list-style-type: none"> <li>➤ MRI Abdomen and Pelvis without and with contrast (CPT® 74183 and CPT® 72197)</li> </ul>
Additional initial evaluation for individuals with symptoms suggesting CNS metastases	<ul style="list-style-type: none"> <li>➤ MRI Brain without and with contrast (CPT® 70553)</li> </ul>
Additional initial evaluation for individuals with systemic symptoms or bone pain	<ul style="list-style-type: none"> <li>➤ Nuclear bone scan (See: <b>PEDONC-1.3</b> for coding)</li> </ul>
Restaging in individuals with disease not completely resected at initial diagnosis	<ul style="list-style-type: none"> <li>➤ Every 2 cycles (~every 6 weeks) and at the end of planned therapy:                             <ul style="list-style-type: none"> <li>◆ CT Chest/Abdomen/Pelvis (CPT® 71260 and CPT® 74177) with contrast                                     <ul style="list-style-type: none"> <li>■ CT imaging may be indicated more frequently to assess for surgical resectability in individuals who have received more than 4 cycles of chemotherapy</li> </ul> </li> <li>◆ Imaging of any metastatic sites with the same modality used during initial staging</li> </ul> </li> </ul>
<ul style="list-style-type: none"> <li>➤ Suspicious lesion seen on CT and both of the following:                             <ul style="list-style-type: none"> <li>◆ Relapse risk is determined to be low by the treating physician</li> <li>◆ Biopsy would cause unnecessary morbidity for the individual</li> </ul> </li> </ul>	<ul style="list-style-type: none"> <li>➤ Short-interval CT study of the involved area can be approved</li> </ul>
Surveillance, individuals with normal (not elevated) tumor markers at the time of diagnosis	<ul style="list-style-type: none"> <li>➤ CT Abdomen and Pelvis with contrast (CPT® 74177) every 6 months for 2 years, then every 12 months for 3 years to complete a total of 5 years of surveillance</li> </ul>

Indication	Imaging Study
<p>Stage I individuals age 0-10 years treated with surgery only</p>	<ul style="list-style-type: none"> <li>➤ Chest x-ray should be completed every 3 months for 1 year, then every 6 months in year two, to complete two years surveillance after completion of all therapy                             <ul style="list-style-type: none"> <li>◆ For those with primary mediastinal tumors at diagnosis, CT Chest with contrast (CPT® 71260) should be approved in lieu of CXR according to the above schedule.</li> </ul> </li> <li>➤ CT Abdomen/Pelvis with contrast (CPT® 74177) every 3 months for 1 year, then every 6 months in year two, to complete two years surveillance after completion of all therapy</li> </ul>
<p>Stage I individuals ages 11+ years treated with surgery only</p>	<ul style="list-style-type: none"> <li>➤ Chest x-ray should be completed every 4 months for 2 years, then every 6 months for 1 year, then every 12 months for 2 years to complete 5 years surveillance imaging after completion of all therapy.                             <ul style="list-style-type: none"> <li>◆ For individuals with primary mediastinal tumors at diagnosis, CT Chest with contrast (CPT® 71260) should be approved in lieu of chest x-ray on the above schedule.</li> </ul> </li> <li>➤ CT Abdomen/Pelvis with contrast (CPT® 74177) every 4 months for 2 years, then every 6 months for 1 year, then every 12 months for two years to complete 5 years surveillance</li> </ul>
<p>Stage II-IV individuals</p>	<ul style="list-style-type: none"> <li>➤ Chest x-ray should be completed every 3 months for 1 year, then every 6 months in year 2, then annually in years 3-5 after completion of all therapy.                             <ul style="list-style-type: none"> <li>◆ For individuals with primary mediastinal tumors at diagnosis, CT Chest with contrast (CPT® 71260) should be approved in lieu of chest x-ray on the above schedule.</li> </ul> </li> <li>➤ CT Abdomen/Pelvis with contrast (CPT® 74177) every 3 months for 1 year then every 6 months in year 2, then annually in years 3-5 year after completion of all therapy.</li> <li>➤ Individuals with brain or bone metastases should have surveillance imaging of those areas on the same schedule as the primary site imaging with the same modality used during initial staging</li> </ul>
<ul style="list-style-type: none"> <li>➤ Suspected Recurrence:                             <ul style="list-style-type: none"> <li>◆ Any clinically significant rise in tumor markers</li> <li>◆ Symptoms suggesting recurrent disease</li> <li>◆ Abnormal chest x-ray</li> </ul> </li> </ul>	<ul style="list-style-type: none"> <li>➤ CT Chest/Abdomen/Pelvis with contrast (CPT® 71260 and CPT® 74177)</li> <li>➤ Whole-body bone scan (CPT® 78306) for individuals with a history of bone involvement or with bone pain.</li> </ul>



## **Background and Supporting Information**

### **General Considerations:**

- Malignant pediatric germ cell tumors commonly include one of four histologic subtypes:
  - ◆ Yolk sac tumor
  - ◆ Choriocarcinoma
  - ◆ Embryonal carcinoma
  - ◆ Mixed histology
- Tumors can occur in testicular, ovarian or extragonadal primary locations
- Ovarian masses that are <10 cm in size, have minimal or no visible solid component on ultrasound, and have normal tumor markers are almost universally benign teratomas or functional cysts
  - ◆ Advanced imaging is not necessary
- Sex cord stromal tumors (granulosa cell, theca, sertoli, and leydig tumors) are rare in pediatrics and should be imaged according to general guidelines in: **Testicular, Ovarian and Extragonadal Germ Cell Tumors (ONC-20)** in the Oncology Imaging Guidelines.
- This section applies to primary germ cell tumors occurring outside the central nervous system in children who are ≤15 years old at the time of initial diagnosis.
  - ◆ For individuals who are >15 years old at diagnosis, the overall prognosis is inferior and these individuals should be imaged according to general guidelines in: **Testicular, Ovarian and Extragonadal Germ Cell Tumors (ONC-20)** in the Oncology Imaging Guidelines.
- For CNS germ cell tumors, use the imaging guidelines in: **CNS Germinomas and Non-Germinomatous Germ Cell Tumors (NGGCT) (PEDONC-4.7)**.

### **Treatment Considerations:**

- Overall treatment strategies are similar for all malignant germ cell tumors.
- Individuals with localized GCT are often cured with surgery alone and do not receive adjuvant therapy.
  - ◆ These individuals should be imaged using surveillance guidelines after surgery is completed.
- Individuals receiving adjuvant chemotherapy are usually treated with 4 to 6 cycles of combination chemotherapy.

### **Imaging Modality Considerations:**

- Initial evaluation of: Ovarian, testicular, and abdominal extragonadal suspected GCT should be completed by ultrasound and tumor markers (AFP, β-hCG)
  - ◆ Once a primary mass suspected to be GCT is discovered, initial staging is indicated prior to histologic confirmation
  - ◆ The degree of abdominal exploration and node sampling necessary for adequate staging is determined in part by imaging findings and is required for preoperative planning

- The primary method of response assessment is by tumor marker decrease
- The primary method of surveillance in pediatric GCT is frequent assessment of serum tumor markers, unless tumor markers were not elevated at diagnosis
- Surveillance imaging of the chest in disease stages I-IV should generally be performed using chest x-ray
  - ◆ See surveillance indications for specific imaging recommendations
- There has been no published evidence to date supporting the routine use of PET/CT in the evaluation of pediatric GCT
  - ◆ Additionally, PET has been found to have similar efficacy to CT imaging in initial staging of adults with non-seminomatous GCT (the majority of pediatric GCT are non-seminomatous)
- PET as a marker of treatment response has been shown not to be predictive of individual outcomes in GCT and should not be approved
  - ◆ Suspicious lesions seen on conventional imaging should be biopsied to confirm active disease

### References

1. Frazier AL, Olson TA, Schneider DT, et al. Germ cell tumors. In: Pizzo PA, Poplack DG, eds. Principles and Practice of Pediatric Oncology. 7th edition. Philadelphia, PA: Wolters Kluwer; 2016:899-918.
2. Frazier AL, Billmire D, Amatruda J. Pediatric germ cell tumors. In: Orkin SH, Fisher DE, Ginsburg D, Look AT, Lux SE, Nathan DG, eds. Nathan and Oski's Hematology and Oncology of Infancy and Childhood. 8th edition. Philadelphia, PA: Elsevier Saunders; 2015:2056-2099.
3. Gilligan T, Lin DW, Aggarwal R, et al. National Comprehensive Cancer Network (NCCN) Guidelines Version 2.2022—January 4, 2022, Testicular Cancer, available at: [https://www.nccn.org/professionals/physician\\_gls/pdf/testicular.pdf](https://www.nccn.org/professionals/physician_gls/pdf/testicular.pdf), Referenced with permission from the NCCN Clinical Practice Guidelines in Oncology (NCCN Guidelines™) for Testicular Cancer V2.2022 1/4/2022. ©2022 National Comprehensive Cancer Network, Inc. All rights reserved. The NCCN Guidelines™ and illustrations herein may not be reproduced in any form for any purpose without the express written permission of the NCCN. To view the most recent and complete version of the NCCN Guidelines™, go online to NCCN.org
4. Armstrong DK, Plaxe SC, Alvarez RD, et al. National Comprehensive Cancer Network (NCCN) Guidelines Version 4.2022—August 25, 2022 Ovarian Cancer, available at: [https://www.nccn.org/professionals/physician\\_gls/pdf/ovarian.pdf](https://www.nccn.org/professionals/physician_gls/pdf/ovarian.pdf), Referenced with permission from the NCCN Clinical Practice Guidelines in Oncology (NCCN Guidelines™) for Ovarian Cancer V4.2022 8/5/2022. ©2022 National Comprehensive Cancer Network, Inc. All rights reserved. The NCCN Guidelines™ and illustrations herein may not be reproduced in any form for any purpose without the express written permission of the NCCN. To view the most recent and complete version of the NCCN Guidelines™, go online to NCCN.org
5. de Wit M, Brenner W, Hartmann M, et al. [18F]-FDG-PET in clinical stage I/II non-seminomatous germ cell tumors: results of the German multicentre trial. *Ann Oncol.* 2008;19(9):1619-1623. doi:10.1093/annonc/mdn170.
6. Huddart RA, O'Doherty MJ, Padhani A, et al. 18Fluorodeoxyglucose positron emission tomography in the prediction of relapse in patients with high-risk, clinical stage I nonseminomatous germ cell tumors: preliminary report of MRC trial TE22--the NCRI testis tumor clinical study group. *J Clin Oncol.* 2007;25(21):3090-3095. doi:10.1200/JCO.2006.09.3831.
7. Papic JC, Finnell MA, Slaven JE, et al. Predictors of ovarian malignancy in children: overcoming clinical barriers of ovarian preservation. *J Pediatr Surg.* 2014;49(1):144-148. doi:10.1016/j.jpedsurg.2013.09.068.
8. Olson TA, Murray MJ, Rodriguez-Galindo C, et al. Pediatric and adolescent extracranial germ cell tumors: the road to collaboration. *J Clin Oncol.* 2015;33(27):3018-3028. doi:10.1200/JCO.2014.60.5337.
9. Fresneau B, Orbach D, Faure-Conter C, et al. Sex-cord stromal tumors in children and teenagers: results of the TGM-95 study. *Pediatr Blood Cancer.* 2015;62(12):2114-2119. doi:10.1002/pbc.25614.
10. Fonseca A, Xia C, Lorenzo AJ et al, Detection of Relapse by Tumor Markers Versus Imaging in Children and Adolescents With Nongerminomatous Malignant Germ Cell Tumors: A Report From the Children's Oncology Group, *J Clin Oncol* 2019;37:396-402. doi:10.1200/JCO.18.00790.

<b>Pediatric Liver Tumors (PEDONC-11)</b>
<b>Pediatric Liver Tumors – General Considerations (PEDONC-11.1)</b>
<b>Hepatoblastoma (PEDONC-11.2)</b>
<b>Pediatric Hepatocellular Carcinoma (HCC) (PEDONC-11.3)</b>

**[Pediatric Liver Tumors – General Considerations \(PEDONC-11.1\)](#)**

- Primary hepatic germ cell tumors should follow imaging guidelines in: **Pediatric Germ Cell Tumors (PEDONC-10)**.
- Primary hepatic sarcomas should follow imaging guidelines in: **Non-Rhabdomyosarcoma Soft Tissue Sarcomas (NRSTS) (PEDONC-8.3)**.
- Imaging requests relating to liver transplant surgery and surveillance should follow guidelines in section **Transplant (AB-42)** in the Abdomen Imaging Guidelines.

## **Hepatoblastoma (PEDONC-11.2)**

### **Hepatoblastoma Initial Staging:**

- Ultrasound may be approved even after MRI or CT imaging in order to allow evaluation for tumor thrombus
- Once a primary liver mass is discovered, definitive imaging is indicated prior to histologic diagnosis, and may involve ANY of the following:
  - ◆ MRI Abdomen and Pelvis without and with contrast (CPT® 74183 and CPT® 72197) is preferred for evaluating tumor margins and vascular anatomy
  - ◆ CT Abdomen and Pelvis with contrast (CPT® 74177)
    - Noncontrast imaging is not indicated due to the increased radiation exposure and limited additive benefit
  - ◆ MRI **and** CT imaging for some tumors during initial evaluation
  - ◆ MRA Abdomen (CPT® 74185) or CTA Abdomen (CPT® 74175) to evaluate vascular invasion
- CT Chest with (CPT® 71260) **or** CT Chest without contrast (CPT® 71250) is indicated in the initial work-up of all pediatric liver tumors and should be completed prior to anesthesia exposure if possible
- Bone scan (See: **Modality General Considerations (PEDONC-1.3)**) for initial evaluation of bony metastases only with systemic symptoms or bone pain.
- MRI Brain without and with contrast (CPT® 70553) only for symptoms suggesting CNS metastases
- PET/CT only in very rare circumstances for preoperative planning when MRI and CT scans are insufficient for surgical decision making.
  - ◆ Indications and coding for rare circumstances where PET/MRI may be approved are found in **PET Imaging in Pediatric Oncology (PEDONC-1.4)**

### **Hepatoblastoma Treatment Response:**

- CT Chest with (CPT® 71260) **or** without contrast (CPT® 71250) every 2 cycles **and** at the end of planned therapy for individuals with incomplete resection at initial diagnosis
- CT Abdomen and Pelvis with contrast (CPT®74177) **or** MRI Abdomen and Pelvis without and with contrast (CPT® 74183 and CPT® 72197) every 2 cycles **and** at the end of planned therapy for individuals with incomplete resection at initial diagnosis

- While the majority of individuals will require abdomen and pelvis imaging at all time points, the pelvis imaging may be omitted at the discretion of the ordering physician
- MRA Abdomen (CPT® 74185) or CTA Abdomen (CPT® 74175) to evaluate vascular invasion
- Imaging of any metastatic sites with the same modality used during initial staging every 2 cycles and at the end of planned therapy for individuals with incomplete resection at initial diagnosis
- Imaging more frequently to assess for surgical resectability in individuals who have received more than 4 cycles of chemotherapy.
- Abdominal ultrasound is indicated if tumor thrombus was detected at initial diagnosis
  - ◆ If no tumor thrombus was present, continued ultrasound evaluations are not indicated without a specific reason documented in the clinical records
- PET/CT should only be considered in very rare circumstances for preoperative planning when MRI and CT scans are insufficient for surgical decision making.

### **Hepatoblastoma Surveillance Imaging:**

- For surveillance in individuals with an AFP of >100 ng/ml
  - ◆ CT Chest and Abdomen with contrast (CPT® 71260 and CPT® 74160) for any clinically significant rise in tumor markers or symptoms suggesting recurrent disease
- For individuals with AFP ≤100 ng/ml at diagnosis or recurrence, the following imaging is appropriate:
  - ◆ CT Abdomen with contrast (CPT® 74160) every 3 months for 2 years, then every 4 months for 2 years after completion of all therapy
  - ◆ Chest x-ray or CT Chest with contrast (CPT® 71260) every 3 months for 2 years, then every 4 months for 2 years after completion of all therapy
  - ◆ Individuals with brain or bone metastases should have surveillance imaging on the same schedule as the primary site imaging with the same modality used during initial staging

### ***Background and Supporting Information***

- Pediatric liver tumors primarily include hepatoblastoma and hepatocellular carcinoma, but hepatic germ cell tumors and primary hepatic sarcomas occur with some frequency. Tumor markers are useful for initial evaluation as well as treatment response, particularly in hepatoblastoma. Early consideration of liver transplant may be undertaken in children and adolescents with unresectable localized disease, provided that the disease remains confined to the liver.
- Hepatoblastoma occurs most commonly in very young children (median diagnosis age of 19 months). Most cases of hepatoblastoma are sporadic, but some are associated with genetic abnormalities, including Beckwith-Wiedemann syndrome, familial adenomatous polyposis, and trisomy 18. Most suspected liver tumors will have ultrasound and tumor markers (AFP, β-HCG, CEA) as part of the initial evaluation.

- There has been no published evidence to date supporting the routine use of PET/CT imaging in the evaluation of pediatric Hepatoblastoma during initial imaging, treatment response, or surveillance.
- PET/CT should not be approved in lieu of biopsy of suspicious lesions
- Individuals with localized hepatoblastoma of pure fetal histology are often cured with surgery alone and do not receive adjuvant therapy. These individuals should be imaged using surveillance guidelines after surgery is completed.
- Individuals receiving adjuvant chemotherapy are usually treated with 2 to 8 cycles of combination chemotherapy. Tumor marker decrease is important in response assessment but does not eliminate the need for advanced imaging in individuals with unresected hepatoblastoma.
- The primary method of surveillance in hepatoblastoma is frequent assessment of serum tumor markers (primarily AFP).
- No specific imaging for surveillance in individuals with an AFP of >100 ng/mL at diagnosis or recurrence.

### **Pediatric Hepatocellular Carcinoma (HCC) (PEDONC-11.3)**

#### **Pediatric HCC Initial Staging:**

- Ultrasound may be approved even after MRI or CT imaging in order to allow evaluation for tumor thrombus
- Once a primary liver mass is discovered, definitive imaging prior to histologic diagnosis including ANY of the following:
  - ◆ CT Abdomen and Pelvis with contrast (CPT® 74177)
  - ◆ MRI Abdomen and Pelvis without and with contrast (CPT® 74183 and CPT® 72197)
  - ◆ Some tumors may require both MRI and CT during initial evaluation
  - ◆ MRA Abdomen (CPT® 74185) or CTA Abdomen (CPT® 74175) to evaluate vascular invasion
- CT Chest with (CPT® 71260) **or** without contrast (CPT® 71250) in the initial work-up of all pediatric liver tumors and should be completed prior to anesthesia exposure if possible
- MRI Brain without and with contrast (CPT® 70553) only for symptoms suggesting CNS metastases
- Nuclear bone scan (See **Modality General Considerations (PEDONC-1.3)**) should be used for initial evaluation of bony metastases only in individuals with systemic symptoms or bone pain
- PET/CT should only be considered in very rare circumstances for preoperative planning when MRI and CT are insufficient for surgical decision making.
  - ◆ PET/CT should not be approved in lieu of biopsy of suspicious lesions
  - ◆ Indications and coding for rare circumstances where PET/MRI may be approved are found in **PET Imaging in Pediatric Oncology (PEDONC-1.4)**

### **Pediatric HCC Treatment Response:**

- For individuals with disease not completely resected at initial diagnosis, the following every 2 cycles (~6 weeks) **and** at the end of planned therapy:
  - ◆ CT Chest with (CPT® 71260) **or** CT Chest without contrast (CPT® 71250)
  - ◆ CT Abdomen and Pelvis with contrast (CPT®74177) **or** MRI Abdomen and Pelvis without and with contrast (CPT® 74183 and CPT® 72197)
    - While the majority of individuals will require abdomen and pelvis imaging at all time points, the pelvis imaging may be omitted at the discretion of the ordering physician
    - MRA Abdomen (CPT® 74185) or CTA Abdomen (CPT® 74175) to evaluate vascular invasion
- Imaging of any metastatic sites with the same modality used during initial staging
- Abdominal ultrasound if tumor thrombus was detected at initial diagnosis
  - ◆ If no tumor thrombus was present, continued ultrasound evaluations are not indicated without a specific reason documented in the clinical records
- PET/CT in very rare circumstances for preoperative planning when MRI and CT scans are insufficient for surgical decision making.

### **Pediatric HCC Surveillance Imaging:**

- CT Abdomen and Pelvis with contrast (CPT® 74177) every 3 months for 1 year, then every 6 months for 1 year, then annually for 3 years after completion of all therapy
- Chest x-ray or CT Chest with contrast (CPT® 71260) every 3 months for 1 year, then every 6 months for 1 year, then annually for 3 years after completion of all therapy

### ***Background and Supporting Information***

- Individuals with brain or bone metastases should have surveillance imaging on the same schedule as the primary site imaging with the same modality used during initial staging.
- HCC, including its rare histologically distinct variant fibrolamellar hepatocellular carcinoma (FL-HCC), occurs mostly in older children and adolescents. Despite recent advances in treatment, overall survival of pediatric HCC diagnosed in advanced stages remains exceedingly poor, with five-year survival of only 17% to 22% for all stages of pediatric HCC (and FL-HCC). Most suspected liver tumors will have ultrasound and tumor markers (AFP,  $\beta$ -HCG, CEA) as initial evaluation.
- PET/CT should not be approved in lieu of biopsy of suspicious lesions
- The majority of hepatocellular carcinoma individuals are treated with surgery alone and do not receive adjuvant therapy. Individuals with successful upfront gross total resection should be imaged using surveillance guidelines after surgery is completed.
- PET/CT has no documented role in the surveillance evaluation of pediatric hepatocellular carcinoma.

## References

1. Meyers RL, Trobaugh-Lotario AD, Malogolowkin MH, et al. Pediatric liver tumors. In: Pizzo PA, Poplack DG, eds. Principles and Practice of Pediatric Oncology. 7th edition. Philadelphia, PA: Wolters Kluwer; 2016:726-752.
2. Tomlinson GE. Hepatoblastoma and other liver tumors in children. In: Orkin SH, Fisher DE, Ginsburg D, Look AT, Lux SE, Nathan DG, eds. Nathan and Oski's Hematology and Oncology of Infancy and Childhood. 8th edition. Philadelphia, PA: Elsevier Saunders; 2015:1886-1905.
3. Pugmire BS, Towbin AJ. Magnetic resonance imaging of primary pediatric liver tumors. *Pediatr Radiol*. 2016;46:764-777. doi:10.1007/s00247-016-3612-0.
4. Chavhan GB, Shelmerdine S, Jhaveri K, Babyn PS. Liver MR Imaging in children: current concepts and technique. *RadioGraphics*. 2016;36(5):1517-1532. doi:10.1148/rg.2016160017.
5. Rai P, Feusner H. Cerebral metastasis of hepatoblastoma: a review. *J Pediatr Hematol Oncol*. 2016;38(4):279-282. doi:10.1097/MPH.0000000000000554.
6. Allen-Rhoades W, Whittle SB, and Rainusso N, Pediatric Solid Tumors of Infancy: An Overview, *Pediatr Rev* 2018;39:57-67. doi:10.1542/pir.2017-0057.
7. Allan BJ, Wang B, Davis JS, et al. A review of 218 pediatric cases of hepatocellular carcinoma. *J Pediatr Surg*. 2014;49(1):166-171. doi:10.1016/j.jpedsurg.2013.09.050.
8. Pappo AS, Furman WL, Schulz KA, Ferrari A, Helman L, Krailo MD. Rare tumors in children: progress through collaboration. *J Clin Oncol*. 2015;33(27):3047-3054. doi:10.1200/JCO.2014.59.3632.
9. Benson AB, D'Angelica MI, Abbott DE, et al. National Comprehensive Cancer Network (NCCN) Guidelines Version 2.2022—July 15, 2022, Hepatobiliary Cancers, available at: [https://www.nccn.org/professionals/physician\\_gls/pdf/hepatobiliary.pdf](https://www.nccn.org/professionals/physician_gls/pdf/hepatobiliary.pdf), Referenced with permission from the NCCN Clinical Practice Guidelines in Oncology (NCCN Guidelines™) for Hepatobiliary Cancers V2.2022 6/15/2022. ©2022 National Comprehensive Cancer Network, Inc. All rights reserved. The NCCN Guidelines™ and illustrations herein may not be reproduced in any form for any purpose without the express written permission of the NCCN. To view the most recent and complete version of the NCCN Guidelines™, go online to NCCN.org.
10. D'Souza AM, Shah R, Gupta A, et al, Surgical management of children and adolescents with upfront completely resected hepatocellular carcinoma, *Pediatr Blood Cancer* 2019;65:e27293. doi:10.1002/pbc.27293.
11. Weeda VB, Aronson DC, Verheij J, and Lamers WH, Is hepatocellular carcinoma the same disease in children and adults? Comparison of histology, molecular background, and treatment in pediatric and adult patients, *Pediatr Blood Cancer* 2019;66:e27475. doi:10.1002/pbc.27475.



## **Retinoblastoma (PEDONC-12)**

**Retinoblastoma – General Considerations (PEDONC-12.1)**

**Retinoblastoma – Imaging (PEDONC-12.2)**

## **Retinoblastoma – General Considerations (PEDONC-12.1)**

- Retinoblastoma (RB) is primarily a disease of the infant and young child, and presents with leukocoria (loss of red reflex).
- About 75% of individuals are diagnosed before the age of two years (bilateral RB presents at 12 months of age).
- Retinoblastoma can occur as heritable (25% of cases) or nonheritable (75%) disease.
  - ◆ Heritable RB is associated with a germline mutation in the RB1 gene often resulting typically in bilateral disease.
  - ◆ Individuals who carry the RB1 mutation also have increased risk of developing other cancers, such as osteosarcoma, soft tissue sarcomas, or melanoma. For more information on heritable retinoblastoma, see: **Familial Retinoblastoma Syndrome (PEDONC-2.12)**.
  - ◆ Whole-body MRI has shown poor sensitivity and specificity in individuals with predisposition to systemic malignancy due to germline RB1 mutations, and is not supported.
- Detailed evaluation by a physician with significant training and/or experience in retinoblastoma (most commonly a pediatric ophthalmologist or pediatric oncologist) is indicated prior to considering advanced imaging.
- Retinoblastoma can be unilateral, bilateral, or trilateral (involving the pineal gland). Extraocular spread of retinoblastoma is rare and generally confined to the brain.

## **Retinoblastoma – Imaging (PEDONC-12.2)**

### **Retinoblastoma Initial Staging**

- Tumor biopsy is NOT required prior to imaging
- MRI Orbits (CPT® 70543) and Brain (CPT® 70553) without and with contrast c in the initial work-up
  - ◆ Brain imaging may be omitted or deferred at the discretion of the treating ophthalmologist or oncologist
- MRI Spine without and with contrast (Cervical-CPT® 72156, Thoracic-CPT® 72157, Lumbar-CPT® 72158) if there is evidence of CNS metastasis on:
  - ◆ Ophthalmologic exam
  - ◆ MRI Brain
  - ◆ Lumbar CSF cytology
- CT Chest (CPT® 71260) and MRI Abdomen and Pelvis without and with contrast (CPT® 74183 and CPT® 72197) with clinical symptoms to suggest metastatic disease
- CT Orbital (contrast as requested) and orbital ultrasound can be approved if ordered by the treating ophthalmologist for a specified indication
- Nuclear bone scan (See: **Modality General Considerations (PEDONC-1.3)**) is the preferred imaging modality for individuals with systemic bone pain suggestive of bony metastases
- PET has no documented role in the evaluation of retinoblastoma

## **Retinoblastoma Treatment Response:**

- MRI Orbits (CPT® 70543) and/or Brain (CPT® 70553) can be approved every 2 cycles (~ every 6 weeks) and at the end of planned therapy
- For individuals with metastatic disease, imaging of known positive areas using the same modality at initial staging can be approved every 2 cycles (~6 to 8 weeks) and at the end of planned therapy

## **Retinoblastoma Surveillance:**

- Surveillance using advanced imaging for unilateral retinoblastoma after enucleation or exenteration only for evaluation of specific clinical concerns.
- MRI Orbits (CPT® 70543) and Brain (CPT® 70553) for individuals undergoing ocular salvage treatment approaches every 6 months for 2 years following completion of therapy
- MRI Brain without and with contrast (CPT® 70553) can be approved every 6 months for 5 years from the time of diagnosis with retinoblastoma

## **Background and Supporting Information**

- CT should generally be avoided in retinoblastoma individuals under one year of age or with family history of retinoblastoma (heritable) due to substantially increased risks for secondary malignancy
- The primary method of surveillance in retinoblastoma is examination under anesthesia (EUA), although some older children can be sufficiently evaluated by exam without anesthesia (EWA).
- Surveillance using advanced imaging is generally not indicated for unilateral retinoblastoma after enucleation or exenteration but can be approved for evaluation of specific clinical concerns.
- Individuals with bilateral retinoblastoma or germline mutation in RB1 are at increased risk for subsequent pineoblastoma
- Routine MRI follow up for pineal disease is not currently supported by evidence in unilateral retinoblastoma individuals without germline RB1 mutations

## **References**

1. Hurwitz RL, Shields CL, Shields JA, et al. Retinoblastoma. In: Pizzo PA, Poplack DG, eds. Principles and Practice of Pediatric Oncology. 7th ed. Philadelphia, PA: Wolters Kluwer; 2016:700-725.
2. Rodriguez-Galindo C, Wilson MW, and Dyer M. Retinoblastoma. In: Orkin SH, Fisher DE, Ginsburg D, Look AT, Lux SE, Nathan DG, eds. Nathan and Oski's Hematology and Oncology of Infancy and Childhood. 8th edition. Philadelphia, PA: Elsevier Saunders; 2015:1747-1778.
3. de Jong MC, Kors WA, de Graaf P, Castelijns JA, Kivelä T, Moll AC. Trilateral retinoblastoma: a systematic review and meta-analysis. *Lancet Oncol.* 2014;15(10):1157-1167. doi:10.1016/S1470-2045(14)70336-5.
4. De Graaf P, Göricke S, Rodjan F, et al. Guidelines for imaging retinoblastoma: imaging principles and MRI standardization, *Pediatr Radiol.* 2012;42(1):2-14. doi:10.1007/s00247-011-2201-5.
5. Allen-Rhoades W, Whittle SB, and Rainusso N, Pediatric Solid Tumors of Infancy: An Overview, *Pediatr Rev* 2018;39:57-67. doi:10.1542/pir.2017-0057.
6. Lohmann DR, Gallie BL. Retinoblastoma. In: Pagon RA, Adam MP, Ardinger HH et al, eds. GeneReviews™ [Internet]. Seattle, WA: University of Washington, Seattle; 1993-2019. version November 21, 2018. <https://www.ncbi.nlm.nih.gov/books/NBK1452/>.
7. Freidman DN, Lis E, Sklar CA, et al. Whole-body magnetic resonance imaging (WB-MRI) as surveillance for subsequent malignancies in survivors of hereditary retinoblastoma: a pilot study. *Pediatr Blood Cancer.* 2014;61(8):1440-4. doi:10.1002/pbc.24835.

## **Pediatric Nasopharyngeal Carcinoma (PEDONC-13)**

**Pediatric Nasopharyngeal Carcinoma – General Considerations  
(PEDONC-13.1)**

**Pediatric NPC – Imaging (PEDONC-13.2)**

## **Pediatric Nasopharyngeal Carcinoma – General Considerations (PEDONC-13.1)**

- Pediatric nasopharyngeal carcinoma (NPC) is rare in comparison to adult NPC but is responsible for up to 50% of nasopharyngeal cancers in children and has higher rates of aggressive type III EBV-associated histology than adult NPC.
- Standard upfront treatment in pediatric NPC consists of 3 to 4 cycles of neoadjuvant chemotherapy followed by definitive chemoradiotherapy. Rare individuals with lower stage disease may be treated with radiotherapy alone.

## **Pediatric NPC – Imaging (PEDONC-13.2)**

### **Pediatric NPC Initial Staging:**

- MRI Brain without and with contrast (CPT® 70553) **and** MRI Neck without and with contrast (CPT® 70543)
  - ◆ CT Head without and with contrast (CPT® 70470), CT Maxillofacial without and with contrast (CPT® 70488), **and/or** CT Neck with contrast (CPT® 70491) for individuals with documented contraindication to MRI imaging (avoidance of sedation should not be the sole reason)
- CT Chest with contrast (CPT® 71260) in initial staging
- Whole-body PET/CT (CPT® 78816) after histologic confirmation of NPC to evaluate for distant metastases
  - ◆ Bone scan when PET/CT is unavailable (See: **Modality General Considerations (PEDONC-1.3)**)
  - ◆ Indications and coding for rare circumstances where PET/MRI may be approved are found in **PET Imaging in Pediatric Oncology (PEDONC-1.4)**
  - ◆ CT Abdomen with contrast (CPT® 74160) for ANY of the following if PET/CT unavailable:
    - Initial EBV DNA load ≥4000 copies/mL
    - Signs and symptoms of liver disease (including abdominal pain and elevated LFTs)

### **Pediatric NPC Treatment Response:**

- MRI Brain without and with contrast (CPT® 70553) **and** MRI Neck without and with contrast (CPT® 70543) for response assessment at the following time points:
  - ◆ Following completion of neoadjuvant chemotherapy
  - ◆ Following completion of chemoradiotherapy
- CT Chest with contrast (CPT® 71260) **and** Whole-body PET/CT (CPT® 78816) **or** bone scan (See: **Modality General Considerations (PEDONC-1.3)**) at the following time points:
  - ◆ Following completion of neoadjuvant chemotherapy only if positive at initial diagnosis
  - ◆ Following completion of chemoradiotherapy

- PET during active treatment for recurrent pediatric cancer in rare circumstances when results are likely to result in a treatment change, including a change from active treatment to surveillance.

### **Pediatric NPC Surveillance:**

- MRI Brain without and with contrast (CPT® 70553) **and** MRI Neck without and with contrast (CPT® 70543) every 3 months for 1 year, then every 6 months for 2 years after completion of all planned therapy
- CT Chest with contrast (CPT® 71260) is indicated every 3 months for 1 year, then every 6 months for 2 years after completion of all planned therapy

### **Pediatric NPC Suspected Recurrence:**

- MRI Brain without and with contrast (CPT® 70553) and MRI Neck without and with contrast (CPT® 70543)
  - ◆ CT Head without and with contrast (CPT® 70470), CT Maxillofacial without and with contrast (CPT® 70488), and/or CT Neck with contrast (CPT® 70491) can be approved for individuals with documented contraindication to MRI imaging
- CT Chest with contrast (CPT® 71260)
- Whole-body PET/CT (CPT® 78816) or bone scan (See: **Modality General Considerations (PEDONC-1.3)**) for histologically confirmed recurrence of NPC. These studies may also be approved for:
  - ◆ Clarification of specified inconclusive findings seen on conventional imaging
  - ◆ Restaging to identify sites of disease when EBV PCR levels are abnormally high and conventional imaging is negative

### **Background and Supporting Information**

- Metastasis frequently occurs in cervical lymph nodes and retropharyngeal space. Distal metastasis usually appears in bones, lungs, mediastinum, and rarely, in the liver. In many individuals, the initial presentation is a cervical adenopathy, and diagnosis is made with a lymph node biopsy.
- Quantitative EBV DNA PCR measured at initial diagnosis, as it can serve as an effective tumor marker if elevated at initial diagnosis.
- Skull base invasion is common in pediatric NPC and has a dramatic impact on prognosis, and is more easily recognized on MRI imaging
- PET is generally not indicated during active treatment for recurrent pediatric cancer
  - ◆ Whole-body PET/CT (CPT® 78816) or bone scan (See: **Modality General Considerations (PEDONC-1.3)**) are not indicated for routine surveillance in asymptomatic individuals

## References

1. Pappo AS, Rodriguez-Galindo C, and Furman WL. Management of infrequent cancers of childhood. In: Pizzo PA, Poplack DG, eds. Principles and Practice of Pediatric Oncology. 7th edition. Philadelphia, PA: Wolters Kluwer; 2016:1098-1123.
2. Goldberg JM, Pappo AS, and Bishop M. Rare tumors of childhood. In: Orkin SH, Fisher DE, Ginsburg D, Look AT, Lux SE, Nathan DG, eds. Nathan and Oski's Hematology and Oncology of Infancy and Childhood. 8th edition. Philadelphia, PA: Elsevier Saunders; 2015:2123-2145.
3. Cheuk DKL, Sabin ND, Hossain M, et al. Positron emission tomography-computed tomography for staging and follow-up of pediatric nasopharyngeal carcinoma. Eur J Nucl Med Mol Imaging. 2012;39(7):1097-1106. doi:10.1007/s00259-012-2091-2.
4. Stambuk HE, Patel SG, Mosier KM, Wolder SL, Holodny AI. Nasopharyngeal carcinoma: recognizing the radiographic features in children. Am J Neuroradiol. 2005;26(6):1575-1579.
5. Sahai P, Mohanti BK, Sharma A, et al. Clinical outcome and morbidity in pediatric patients with nasopharyngeal cancer treated with chemotherapy. Pediatr Blood Cancer. 2017;64(2):259-266. doi:10.1002/pbc.26240.
6. PDQ® Pediatric Treatment Editorial Board. PDQ Childhood Nasopharyngeal Cancer Treatment – Health Professional Version. Bethesda, MD: National Cancer Institute. Updated 03/01/2022. Available at: <https://www.cancer.gov/types/head-and-neck/hp/child/nasopharyngeal-treatment-pdq>.
7. Zhang, Lu et al. Plasma Epstein-Barr viral DNA complements TNM classification of nasopharyngeal carcinoma in the era of intensity-modulated radiotherapy. ONcotarget. 2015;7(5):6221-6231.

## **Pediatric Adrenocortical Carcinoma (PEDONC-14)**

**Pediatric Adrenocortical Carcinoma – General Considerations  
(PEDONC-14.1)**

**Pediatric ACC – Imaging (PEDONC-14.2)**



## **Pediatric Adrenocortical Carcinoma – General Considerations (PEDONC-14.1)**

- Pediatric Adrenocortical Carcinoma (ACC) is a rare but aggressive tumor, with fewer than 25 cases diagnosed each year.
- Most individuals are diagnosed because of virilizing symptoms, Cushing syndrome, and rarely with feminization and hyperaldosteronism or detection on screening imaging recommended for specified cancer predisposition syndromes.
- See: **Li-Fraumeni Syndrome (LFS) (PEDONC-2.2)** and **Beckwith-Wiedemann Syndrome (BWS) (PEDONC-2.4)** for screening recommendations for individuals known to have these syndromes.

## **Pediatric ACC – Imaging (PEDONC-14.2)**

Indication	Imaging Study
Initial staging	<ul style="list-style-type: none"> <li>➤ CT Chest without contrast (CPT® 71250) or with (CPT® 71260) contrast</li> <li>➤ CT Abdomen without and with contrast (CPT® 74170) or MRI Abdomen without and with contrast (CPT® 74183)</li> <li>➤ Nuclear bone scan (see: <b>PEDONC-1.3</b> for coding)</li> </ul>
After complete resection, with no plans for chemotherapy or radiotherapy	<ul style="list-style-type: none"> <li>➤ See surveillance below</li> </ul>
Restaging, for all unresected primary or metastatic disease on chemotherapy	<ul style="list-style-type: none"> <li>➤ Every 2 cycles (~6 weeks) during chemotherapy, and following completion of all planned chemotherapy:                             <ul style="list-style-type: none"> <li>◆ CT Chest without contrast (CPT® 71250) or with (CPT® 71260) contrast</li> <li>◆ CT Abdomen without and with contrast (CPT® 74170) or MRI Abdomen without and with contrast (CPT® 74183)</li> </ul> </li> <li>➤ If positive for distant metastases at initial diagnosis:                             <ul style="list-style-type: none"> <li>◆ Nuclear bone scan (see: <b>PEDONC-1.3</b> for coding) every 2 cycles (~6 weeks) during chemotherapy and following completion of all planned chemotherapy</li> </ul> </li> </ul>
Response assessment at the completion of radiotherapy	<ul style="list-style-type: none"> <li>➤ CT Abdomen without and with contrast (CPT® 74170) or MRI Abdomen without and with contrast (CPT® 74183)</li> </ul>

Surveillance, individuals with only localized disease at diagnosis	<ul style="list-style-type: none"> <li>➤ Every 3 months for 2 years, then every 6 months for 3 years:                             <ul style="list-style-type: none"> <li>◆ CT Abdomen without and with contrast (CPT® 74170) or MRI Abdomen without and with contrast (CPT® 74183)</li> </ul> </li> </ul>
--	---

Indication	Imaging Study
Surveillance, individuals with metastatic ACC	<ul style="list-style-type: none"> <li>➤ Every 3 months for 2 years, then every 6 months for 3 years:                             <ul style="list-style-type: none"> <li>◆ CT Chest without contrast (CPT® 71250) or with (CPT® 71260) contrast</li> <li>◆ CT Abdomen without and with contrast (CPT® 74170) or MRI Abdomen without and with contrast (CPT® 74183)</li> </ul> </li> </ul>
Recurrence	<ul style="list-style-type: none"> <li>➤ CT Chest without contrast (CPT® 71250) or with (CPT® 71260) contrast</li> <li>➤ CT Abdomen without and with contrast (CPT® 74170) or MRI Abdomen without and with contrast (CPT® 74183)</li> </ul>
Suspected bone recurrence	➤ Nuclear bone scan (see: <b>PEDONC-1.3</b> for coding)

### Background and Supporting Information

- The mainstay of treatment is surgery.
  - ◆ Chemotherapy, adrenal suppression, and radiotherapy typically follow resection.
  - ◆ Many ACC individuals are treated with surgery alone and do not receive adjuvant therapy. These individuals should be imaged using surveillance guidelines after surgery is completed.

### References

1. Waguespack SG, Huh WW, and Bauer AJ. Endocrine tumors. In: Pizzo PA, Poplack DG, eds. Principles and Practice of Pediatric Oncology. 7th edition. Philadelphia, PA: Wolters Kluwer; 2016:919-945.
2. Michalkiewicz E, Sandrini R, Figueiredo B, et al. Clinical and outcome characteristics of children with adrenocortical tumors: a report from The International Pediatric Adrenocortical Tumor Registry. J Clin Oncol. 2004;22(5):838-845. doi:10.1200/JCO.2004.08.085.
3. Flynt KA, Dillman JR, Davenport MS, et al. Pediatric adrenocortical neoplasms: can imaging reliably discriminate adenomas from carcinomas? Pediatr Radiol. 2015;45(8):1160-1168. doi:10.1007/s00247-015-3308-x.
4. Gupta N, Rivera M, Novotny P, et al. Adrenocortical Carcinoma in Children: A Clinicopathological Analysis of 41 Patients at the Mayo Clinical from 1950 to 2017, Horm Res Paediatr 2018;90:8-18. doi:10.1159/000488855.
5. PDQ® Pediatric Treatment Editorial Board. PDQ Childhood Adrenocortical Carcinoma Treatment. Bethesda, MD: National Cancer Institute. Updated 08/26/2022. Available at: <https://www.cancer.gov/types/adrenocortical/hp/child-adrenocortical-treatment-pdq>. Accessed 06/19/2020.
6. Wasserman JD, Novokmet A, Eichler-Jonsson C, et al. Prevalence and functional consequence of TP53 mutations in pediatric adrenocortical carcinoma: a children's oncology group study. J Clin Oncol. 2015;33(6):602-9. doi:10.1200/JCO.2013.52.6863.
7. Shah MH, Goldner WS, Benson III AB, et al. National Comprehensive Cancer Network (NCCN) Guidelines Version 1.2022 – 05/23/2022. Neuroendocrine tumors, available at: [https://www.nccn.org/professionals/physician\\_gls/pdf/neuroendocrine.pdf](https://www.nccn.org/professionals/physician_gls/pdf/neuroendocrine.pdf) Referenced with permission from the NCCN Clinical Practice Guidelines in Oncology (NCCN Guidelines™) for Neuroendocrine and Adrenal tumors V1.2022 – May 23, 2022. ©2022 National Comprehensive Cancer Network, Inc. All rights reserved. The NCCN Guidelines™ and illustrations herein may not be reproduced in any form for any purpose without the express written permission of the NCCN. To view the most recent and complete version of the NCCN Guidelines™, go online to NCCN.org

## Pediatric Melanoma and Other Skin Cancers (PEDONC-15)

- Pediatric melanoma is historically rare but has a steadily rising incidence, especially in adolescents and young adults (AYAs). Staging is assigned using the American Joint Committee on Cancer (AJCC) staging for adult melanoma. Most cases of melanoma arising in children and AYAs (~75%) are localized at diagnosis, and approximately 90% of individuals with pediatric melanoma are amenable to radical excision. The clinical management of adolescents and young adults with melanoma is still challenging and evolving because it is difficult to diagnose, and there is no standard treatment.
- Non-melanoma skin cancers (mostly basal cell carcinoma and squamous cell carcinoma) are extremely rare in pediatric individuals. In many cases, predisposing factors such as prolonged immunosuppression, radiation therapy, chemotherapy, voriconazole use, or a combination of the factors are present, and established age-specific guidelines for management of these skin tumors do not exist.
- Imaging guidelines and treatment approaches are consistent with those used for adults with melanoma and other skin cancers, and these individuals should follow the imaging guidelines in section **Melanomas and Other Skin Cancers (ONC-5)** in the Oncology Imaging Guidelines.

### References

1. Rodriguez-Galindo C, Furman WL, Pappo AS. Rare pediatric tumors. In: Pizzo PA, Poplack DG, eds. Principles and Practice of Pediatric Oncology. 7th edition. Philadelphia, PA: Wolters Kluwer; 2016:946-966.
2. Goldberg JM, Pappo AS, Bishop M. Rare tumors of childhood. In: Orkin SH, Fisher DE, Ginsburg D, Look AT, Lux SE, Nathan DG, eds. Nathan and Oski's Hematology and Oncology of Infancy and Childhood. 8th edition. Philadelphia, PA: Elsevier Saunders; 2015:2123-2145.
3. Swetter SM, Thompson JA, Coit DG, et al. National Comprehensive Cancer Network (NCCN) Guidelines Version 3.2022—April 11, 2022, Melanoma: Cutaneous, available at: [https://www.nccn.org/professionals/physician\\_gls/pdf/cutaneous\\_melanoma.pdf](https://www.nccn.org/professionals/physician_gls/pdf/cutaneous_melanoma.pdf), Referenced with permission from the NCCN Clinical Practice Guidelines in Oncology (NCCN Guidelines™) for Melanoma: Cutaneous V3.2022 4/11/2022. ©2022 National Comprehensive Cancer Network, Inc. All rights reserved. The NCCN Guidelines™ and illustrations herein may not be reproduced in any form for any purpose without the express written permission of the NCCN. To view the most recent and complete version of the NCCN Guidelines™, go online to NCCN.org
4. Senerchia AA, Ribiero KB, Rodriguez-Galindo C. Trends in incidence of primary cutaneous malignancies in children, adolescents, and young adults: a population-based study. *Pediatr Blood Cancer*. 2014;61(2):211-216. doi:10.1002/pbc.24639.
5. Kolandijan NA, Wei C, Burke A, Bedikian AY. Malignant melanoma in teenagers and young adults. *J Pediatr Hematol Oncol*. 2014;36(7):552-558. doi:10.1097/MPH.0000000000000231.
6. Brecht IB, De Paoli A, Bisogno G, et al. Pediatric patients with cutaneous melanoma: A European study, *Pediatr Blood Cancer* 2018;65:e26974. doi:10.1002/pbc.26974.
7. Indini A, Brecht I, Del Vecchio M, et al. Cutaneous melanoma in adolescents and young adults, *Pediatr Blood Cancer* 2018;65:e27292. doi:10.1002/pbc.27292.
8. Kohsravi H, Schmidt B, and Huang JT. Characteristics and outcomes of nonmelanoma skin cancer (NMSC) in children and young adults, *J Am Acad Dermatol* 2015;73:785-790. doi:10.1016/j.aad.2015.08.007.

## Pediatric Salivary Gland Tumors and Thyroid Tumors (PEDONC-16)

### **Pediatric Salivary Gland Tumors**

- The majority of pediatric salivary gland tumors arise in the parotid gland. Approximately 10% to 15% of tumors arise in the submandibular, sublingual, or minor salivary glands.
- Roughly 75% of pediatric salivary gland tumors are benign, most commonly pleomorphic adenoma.
- The most common malignant tumors occurring in the salivary glands are mucoepidermoid carcinoma, adenoid cystic carcinoma, acinic cell carcinoma, undifferentiated carcinoma, and rarely adenocarcinoma.
- American Joint Committee on Cancer (AJCC) staging is used for pediatric as well as adult salivary gland tumors.
- Imaging and treatment guidelines for malignant pediatric salivary gland tumors are consistent with those used for adults with salivary gland tumors, and these individuals should follow the imaging guidelines in section **Salivary Gland Cancers (ONC-4)** in the Oncology Imaging Guidelines.

### **Pediatric Thyroid Tumors**

- Differentiated thyroid cancers (DTC): Papillary, Follicular and Hürthle Cell are the most common childhood thyroid malignancy. Standard treatment is thyroidectomy and radioactive iodine (RAI).
- Imaging and treatment guidelines for malignant pediatric thyroid tumors are consistent with those used for adults with thyroid tumors, and these individuals should follow the imaging guidelines in section **Thyroid Cancers (ONC-6)** in the Oncology Imaging Guidelines.

## References

1. Rodriguez-Galindo C, Furman WL, and Pappo AS. Rare pediatric tumors. In: Pizzo PA, Poplack DG, eds. Principles and Practice of Pediatric Oncology. 7th edition. Philadelphia, PA: Wolters Kluwer; 2016:946-966.
2. Goldberg JM, Pappo AS, and Bishop M. Rare tumors of childhood. In: Orkin SH, Fisher DE, Ginsburg D, Look AT, Lux SE, Nathan DG, eds. Nathan and Oski's Hematology and Oncology of Infancy and Childhood. 8th edition. Philadelphia, PA: Elsevier Saunders; 2015:2123-2145.
3. Pfister DG, Spencer S, Adelstein D, et al. National Comprehensive Cancer Network (NCCN) Guidelines Version 2.2022—April 26, 2022, Head and Neck Cancers, available at: [https://www.nccn.org/professionals/physician\\_gls/pdf/head-and-neck.pdf](https://www.nccn.org/professionals/physician_gls/pdf/head-and-neck.pdf), referenced with permission from the NCCN Clinical Practice Guidelines in Oncology (NCCN Guidelines™) for Head and Neck Cancers V2.2022 4/26/2022. ©2022 National Comprehensive Cancer Network, Inc. All rights reserved. The NCCN Guidelines™ and illustrations herein may not be reproduced in any form for any purpose without the express written permission of the NCCN. To view the most recent and complete version of the NCCN Guidelines™, go online to NCCN.org
4. Chiaravalli S, Guzzo M, Bisogno G, et al. Salivary gland carcinomas in children and adolescents: The Italian TREP project experience. *Pediatr Blood Cancer*. 2014;61(11):1961-1968.
5. Rebours C, Couloigner V, Galmiche L, et al. Pediatric salivary gland carcinomas: diagnostic and therapeutic management. *Laryngoscope*. 2017;127:140-147.
6. Zamani M, Gronhoj C, Jensen JS, et al. Survival and characteristics of pediatric salivary gland cancer: A systematic review and meta-analysis. *Pediatr Blood Cancer*. 2019;66:e27543. doi:10.1002/pbc.27543.
7. Prasad PK, Mahajan P, Hawkins DS, Mostoufi-Moab S, Venkatramani R. Management of pediatric differentiated thyroid cancer: An overview for the pediatric oncologist. *Pediatr Blood Cancer*. 2020;67(6):e28141. doi:10.1002/pbc.28141.
8. Haddad RH, Bischoff L, Bernet V, et al. National Comprehensive Cancer Network (NCCN) Guidelines Version 2.2022 – May 5, 2022 Thyroid carcinoma, available at: [https://www.nccn.org/professionals/physician\\_gls/pdf/thyroid.pdf](https://www.nccn.org/professionals/physician_gls/pdf/thyroid.pdf). Referenced with permission from the NCCN Clinical Practice Guidelines in Oncology (NCCN Guidelines™) for Thyroid carcinoma V2.2022– May 5, 2022 ©2022 National Comprehensive Cancer Network, Inc. All rights reserved. The NCCN Guidelines™ and illustrations herein may not be reproduced in any form for any purpose without the express written permission of the NCCN. To view the most recent and complete version of the NCCN Guidelines™, go online to NCCN.org.

## Pediatric Breast Masses (PEDONC-17)

- Ultrasound (CPT® 76641 and CPT® 76642) is the primary and preferred modality used for evaluation of pediatric breast masses.
- MRI has very limited utility in evaluation of pediatric breast masses prior to biopsy but may be indicated in rare cases for surgical planning when ultrasound is non-diagnostic.
- Pediatric individuals with confirmed breast cancer should be imaged according to section **Breast Cancer (ONC-11)** in the Oncology Imaging Guidelines.

### *Background and Supporting Information*

- Less than 1% of pediatric breast lesions are malignant, and advanced imaging is generally not recommended without histological confirmation of malignancy.
- Mammography has limited utility in pediatric breast mass evaluation due to the high mammographic breast density in this age group, and the risk of the radiation exposure outweighs the benefit of this modality. As a result, mammography is NOT recommended for evaluation of pediatric or adolescent breast masses.
  - ◆ BI-RADS classification may overstate the risk of malignancy or need for biopsy in pediatric individuals.

### *References*

1. Rodriguez-Galindo C, Furman WL, Pappo AS. Rare pediatric tumors. In: Pizzo PA, Poplack DG, eds. Principles and Practice of Pediatric Oncology. 7th edition. Philadelphia, PA: Wolters Kluwer; 2016:946-966.
2. Goldberg JM, Pappo AS, Bishop M. Rare Tumors of Childhood. In: Orkin SH, Fisher DE, Ginsburg D, Look AT, Lux SE, Nathan DG, eds. Nathan and Oski's Hematology and Oncology of Infancy and Childhood. 8th edition. Philadelphia, PA: Elsevier Saunders; 2015:2123-2145.
3. Kaneda HJ, Mack J, Kasales CJ, Schetter S. Pediatric and adolescent breast masses: a review of pathophysiology, imaging, diagnosis, and treatment. AJR Am J Roentgenol. 2013;200(2):W204-W212. doi:10.2214/AJR.12.9560.
4. Koning JL, Davenport KP, Poole PS, Kruk PG, Grabowski JE. Breast Imaging-Reporting and Data System (BI-RADS) classification in 51 excised palpable pediatric breast masses. J Pediatr Surg. 2015;50(10):1746-1750. doi:10.1016/j.jpedsurg.2015.02.062.
5. Siegel MJ, Chung EM. Breast. In: Siegel MJ, ed. Pediatric Sonography. 5th ed. Philadelphia, PA: Wolters Kluwer; 2019:196-210.
6. Siegel MJ, Chung EM. Breast masses in children and adolescents. Applied Radiology. 2017;46(9):12-17.
7. Johnson RH, Anders CK, Litton JK, Ruddy KJ, Bleyer A. Breast cancer in adolescents and young adults. Pediatr Blood Cancer. 2018;65:e27397. doi:10.1002/pmb.27397.
8. Sanders LM, Sharma P, El Madany M, et al. Clinical breast concerns in low-risk pediatric patients: practice review with proposed recommendations. Pediatr Radiol. 2018;48:186-195. doi:10.1007/s00247-017-4007-6.

<b>Histiocytic Disorders (PEDONC-18)</b>
<b>Histiocytic Disorders – General Considerations (PEDONC-18.1)</b>
<b>Langerhans Cell Histiocytosis (LCH) (PEDONC-18.2)</b>
<b>Hemophagocytic Lymphohistiocytosis (HLH) (PEDONC-18.3)</b>
<b>Non-Langerhans Cell Histiocytoses (PEDONC-18.4)</b>

## **Histiocytic Disorders – General Considerations (PEDONC-18.1)**

- The majority of histiocytic disorders occurring in the pediatric population are either Langerhans Cell Histiocytosis (LCH) or Hemophagocytic Lymphohistiocytosis (HLH).
- The Non-Langerhans cell histiocytoses encompass a variety of diseases, and have limited imaging considerations except as specified later in this section.
- Where there are indications for PET/CT in these guidelines, please note that indications and coding for rare circumstances where PET/MRI may be approved are found in **PET Imaging in Pediatric Oncology (PEDONC-1.4)**
- PEDONC-18 applies to individuals of all ages.

## **Langerhans Cell Histiocytosis (LCH) (PEDONC-18.2)**

### **LCH Initial Imaging Studies:**

- Chest x-ray (CXR)
- Abdominal ultrasound (CPT® 76700) with attention to liver and spleen
- Skeletal survey
- MRI Brain without and with contrast (CPT® 70553) for ANY of the following:
  - ◆ Headaches or visual or neurologic disturbances
  - ◆ Polyuria/polydipsia or other endocrine abnormalities
  - ◆ Skull or craniofacial (including jaw) bone involvement
  - ◆ Otorrhea or hearing loss (CT Temporal Bone may be substituted if requested)
  - ◆ Other signs or symptoms suggesting intracranial involvement, including neurodegeneration syndrome
- CTA/MRA Head (CPT® 70496/70544) may be approved as part of operative planning or image guidance
- CT Chest with (CPT® 71260) **or** without contrast (CPT® 71250) for ANY of the following:
  - ◆ Abnormal CXR
  - ◆ Symptoms of pulmonary involvement and normal CXR
- CT Abdomen and/or Pelvis with contrast (CPT® 74177, 74160, or 72193) for ANY of the following, if PET/CT has not been performed:
  - ◆ Abdominal and/or pelvic signs and symptoms
  - ◆ Abdominal and/or pelvic findings on ultrasound
- MRI Abdomen without and with contrast (CPT® 74183) for any of the following:
  - ◆ Elevated liver function tests (usually >5X upper limit of normal)
  - ◆ Abnormalities seen on abdominal ultrasound or CT
- MRI Spine without and with contrast (Cervical-CPT® 72156, Thoracic-CPT® 72157, Lumbar-CPT® 72158) for ANY of the following:
  - ◆ Vertebral lesions seen on skeletal survey
  - ◆ Clinical symptoms (including back pain) suggesting spinal involvement and negative skeletal survey



- Whole-body PET/CT (CPT® 78816) may be approved for any of the following:
  - ◆ At baseline to assess for multisite disease in pediatric individuals (< age 18 years)
  - ◆ Multifocal bone involvement suspected on skeletal survey or other studies
  - ◆ Findings equivocal for multisite involvement on other imaging studies
  - ◆ Bone pain and negative skeletal survey
  - ◆ Involvement of high-risk sites: CNS, liver, spleen or bone marrow
  - ◆ Other clinical symptoms suggesting multisite disease
  - ◆ If a PET/CT is performed, additional diagnostic CTs are not generally supported except in the scenario of pulmonary LCH.
- Whole-body Tc-99m bone scan (CPT® 78306) can be approved in lieu of PET for the same indications if PET is unavailable

### **LCH Treatment Response:**

- Both PET/CT and CT with contrast or MRI without and with contrast **only** for simultaneous treatment response evaluation with specific documentation showing that both are necessary (i.e. not for purpose of acquiring a PET/MRI)
- CT and/or MRI and/or PET/CT (if modality showed disease at initial diagnosis):
  - ◆ After 6 weeks of treatment **and** after 12 weeks of treatment for those with persistent measurable disease
- Following the initial phase, treatment response evaluation of **involved sites** with CT with contrast or MRI with and without contrast, every ~3 months while receiving active treatment and at completion of therapy.
  - ◆ Shorter interval imaging can be approved for documented signs or symptoms concerning for disease progression
- At the end of planned therapy:
  - ◆ Chest x-ray (CXR)
  - ◆ Abdominal ultrasound (CPT® 76700)
  - ◆ Skeletal survey
  - ◆ Repeat of all additional imaging studies positive at initial workup (except PET)
- PET during active treatment for recurrent pediatric cancer only in rare circumstances when results are likely to result in a treatment change, including a change from active treatment to surveillance.

### **LCH Surveillance Imaging:**

- Surveillance imaging is determined by areas of disease involvement.
  - ◆ Bone involvement
    - Single site bone disease
      - CT or MRI contrast as requested of involved bony areas at 6 and 12 months after completion of therapy
    - Multifocal bone disease
      - CT or MRI contrast as requested of involved bony areas at 6,12, 18, and 24 months after completion of therapy
    - PET/CT (CPT® 78815 or CPT® 78816) may be approved for CT or MRI inconclusive for recurrence.
    - Skull or craniofacial (including jaw) bone involvement should be imaged according to CNS involvement section below.

- Pulmonary involvement
  - ◆ CT Chest with (CPT® 71260) **or** without contrast (CPT® 71250) every 6 months for the first 2 years post completion of therapy for any of the following:
    - Individuals with a history of pulmonary involvement
    - Individuals with new respiratory or chest symptoms
    - New findings on CXR
- CNS involvement
  - ◆ MRI Brain without and with contrast (CPT® 70553) at 6 weeks, and then every 6 months for 2 years after completion of all therapy for previously documented measurable intracranial lesions
    - If negative at that time, continued surveillance is indicated at 4, 7, and 10 years after completion of all planned therapy
    - If residual measurable intracranial lesions are present at 6 months, imaging can be repeated every 3 months until negative or unchanged on two consecutive studies, at which time the schedule in the previous bullet should begin
  - ◆ MRI Brain without and with contrast (CPT® 70553) for documented hypothalamic-pituitary dysfunction every 6 months for 2 years and at 4, 7, and 10 years after completion of all planned therapy
    - MRI at any time for worsening neurologic symptoms
  - ◆ Intraspinial lesions should be imaged according to the same guidelines as brain imaging using MRI without and with contrast of all involved spine levels
- Liver involvement
  - ◆ Individuals with a history of liver involvement may have ONE of the following every 6 months for 2 years after completion of all therapy:
    - Ultrasound Abdomen (CPT® 76700)
    - CT Abdomen with contrast (CPT® 74160)
- MRI Abdomen with and without contrast (CPT® 74183) Suspected recurrence or inconclusive findings on any surveillance imaging
  - ◆ All imaging studies supported for initial workup may be approved, including whole-body PET/CT (CPT® 78816)

### ***Background and Supporting Information***

- This guideline may be used for all ages of individuals.
- LCH includes a heterogeneous group of disorders formerly known by other names, including histiocytosis X, eosinophilic granuloma, Letterer-Siwe Disease, Hand-Schuller-Christian Disease, and diffuse reticuloendotheliosis. LCH has a widely variable clinical presentation, ranging from single indolent lesions to disseminated multisystem disease.
- Most common sites of involvement are skin, bones, liver, lung, and pituitary, though other sites are possible.
- Individuals with localized or single site disease are often treated only with local therapies or observed, and should be imaged according to surveillance guidelines
- Individuals receiving systemic therapy will usually undergo treatment for ~12 months. Treatment response is assessed using any modalities showing disease at initial diagnosis after ~6 weeks of treatment.
- Once PET/CT shows no remaining FDG-avid lesions, additional PET imaging is not indicated
- Skull or craniofacial (including jaw) bone involvement at diagnosis are at higher risk

- for CNS recurrence
- CNS LCH has a particularly high rate of refractory and recurrent disease, and requires longer imaging surveillance
- Liver involvement
  - ◆ Persistent liver involvement is rare, and imaging after completion of LCH therapy will be highly individualized depending on degree of liver dysfunction and plans for supportive therapy or liver transplant

### **Hemophagocytic Lymphohistiocytosis (HLH) (PEDONC-18.3)**

- As imaging for this condition is usually done on an urgent basis, ANY or ALL of the following may be approved for the initial evaluation of HLH include:
  - ◆ Ultrasound Abdomen (CPT® 76700)
  - ◆ CT Abdomen and/or Pelvis (contrast as requested)
  - ◆ MRI Abdomen (CPT® 74183) and/or Pelvis (CPT® 72197) without and with contrast
  - ◆ Chest x-ray
  - ◆ CT Chest with contrast (CPT® 71260)
  - ◆ MRI Brain without and with contrast (CPT® 70553)
  - ◆ CTA/MRA Head (CPT® 70496/CPT® 70544) may be approved as part of operative planning or image guidance
  - ◆ CT Sinus without or with contrast (CPT® 70486 or CPT® 70487) if clinical suspicion for sinus disease
- Whole-body PET/CT (CPT® 78816) for the purpose of identifying a site for tissue diagnosis of a primary source of infection or malignancy if conventional imaging has been completed and is unrevealing
  - ◆ If a malignancy is identified as the inciting factor for HLH, additional imaging decisions for that malignancy should be based on the appropriate diagnosis-specific guidelines

### ***Background and Supporting Information***

- There are no standard imaging studies required for the diagnosis and initial evaluation of HLH. Most cases are diagnosed with a combination of physical findings, laboratory testing, and bone marrow evaluation. Advanced imaging studies may be necessary to assess organ dysfunction as HLH commonly affects the liver, spleen, and bone marrow, and less commonly the kidneys, lungs, and brain
- It is NOT required to perform ultrasound or plain film in a stepwise fashion if CT or MRI is planned as individuals with HLH can deteriorate rapidly
- There is no established standard role for PET in the diagnosis or treatment response evaluation of HLH
  - ◆ Secondary HLH is very difficult to treat if the primary cause is not concurrently treated

## **Non-Langerhans Cell Histiocytoses (PEDONC-18.4)**

### **Juvenile Xanthogranuloma (JXG):**

- Skin and/or cervical nodes:
  - ◆ CT with contrast of appropriate area
- Systemic JXG with multi-organ involvement:
  - ◆ MRI Brain (CPT® 70553) **and/or** Orbits (CPT® 70543) without and with contrast
  - ◆ CT Neck (CPT® 70491), Chest (CPT® 71260), **and/or** Abdomen (CPT® 74160) with contrast
  - ◆ CTA/MRA Head (CPT® 70496/CPT® 70544) may be approved as part of operative planning or image guidance
- There is no established role for PET in the diagnosis or treatment of JXG

### **Rosai-Dorfman Disease (RDD):**

- RDD Initial Imaging Studies:
  - ◆ MRI Brain (CPT® 70553) and/or Orbits (CPT® 70543) without and with contrast
  - ◆ CTA/MRA Head (CPT® 70496/CPT® 70544) may be approved as part of operative planning or image guidance
  - ◆ CT Neck (CPT® 70491), Chest (CPT® 71260) and/or Abdomen/Pelvis (CPT® 74177) with contrast
  - ◆ CT Sinus without or with contrast (CPT® 70486 or CPT® 70487) if clinical suspicion for sinus disease
  - ◆ Whole-body PET/CT (CPT® 78816) after histologic confirmation of diagnosis
- RDD Treatment Response:
  - ◆ Treatment response imaging can be approved after 2-3 cycles of systemic therapy during active treatment using any modalities showing disease at diagnosis, including PET/CT.
    - Once PET/CT is negative, conventional imaging with other modalities that revealed disease at presentation may be approved for subsequent restaging at completion of chemotherapy and/or radiation and/or after surgical resection.
- RDD Surveillance Imaging:
  - ◆ Surveillance imaging can be approved every 3 months for the first year after completion of treatment, then every 6 months using any modalities showing disease at initial diagnosis excluding PET-CT.
    - PET/CT is not supported for routine surveillance of RDD but can be approved if conventional imaging is inconclusive for suspected recurrence.

## **Erdheim-Chester Disease (ECD):**

- ECD Initial Imaging Studies:
  - ◆ MRI Brain (CPT® 70553) **and/or** Orbits (CPT® 70543) without and with contrast
  - ◆ CTA/MRA Head (CPT® 70496/70544) may be approved as part of operative planning or image guidance
  - ◆ Nuclear bone scan (See: **Modality General Considerations (PEDONC-1.3)**)
  - ◆ Whole-body PET/CT (CPT® 78816)
  - ◆ CT Neck (CPT® 70491), Chest (CPT® 71260) **and/or** Abdomen/Pelvis (CPT® 74177) with contrast
  - ◆ CTA or MRA of Chest (CPT® 71275 or CPT® 71555) **or** Abdomen (CPT® 74175 or CPT® 74185) to evaluate vascular tree involvement
  - ◆ Cardiac MRI without and with contrast (CPT® 75561)
  - ◆ CT Sinus without or with contrast (CPT® 70486 or CPT® 70487) if clinical suspicion for sinus disease
- ECD Treatment Response:
  - ◆ Treatment response imaging every 3 months during active treatment using any modalities showing disease at initial diagnosis, including PET/CT
  - ◆ Once PET/CT shows no remaining FDG-avid lesions, additional PET imaging is only indicated when conventional imaging studies are inconclusive and acute treatment decisions will be made based on PET results.
- ECD Surveillance Imaging:
  - ◆ CT **and/or** MRI **and/or** Nuclear bone scan **and/or** CTA **and/or** MRA **and/or** Cardiac MRI (if modality showed disease at initial diagnosis) every 3 months for the first year after completion of treatment and then every 6 months
  - ◆ PET/CT if conventional imaging is inconclusive for suspected recurrence.

## ***Background and Supporting Information***

- Non-Langerhans Cell histiocytoses includes diagnoses such as juvenile xanthogranuloma (JXG), sinus histiocytosis with lymphadenopathy (Rosai-Dorfman Disease, RDD), and Erdheim-Chester Disease (ECD)
- In general, these are localized cutaneous or nodal disease without need for regular advanced imaging, but important exceptions are listed in this section.
- Juvenile Xanthogranuloma (JXG):
  - ◆ Generally involves only skin or cervical nodes, and involutes spontaneously
- Rosai-Dorfman Disease (RDD):
  - ◆ Characterized by bulky adenopathy (usually cervical) with frequent systemic involvement
  - ◆ There is no established role for PET in the diagnosis or treatment of RDD
  - ◆ Because of the paucity of evidence for PET, PET/CT should not be used to replace tissue confirmation for any clinical scenario in RDD
  - ◆ There is no established role for routine surveillance imaging of asymptomatic individuals after treatment for RDD

- Erdheim-Chester Disease (ECD):
  - ◆ An aggressive histiocytic disorder with overall poor prognosis that is characterized by long bone involvement with frequent spread to multiple organs
  - ◆ Most individuals will receive systemic therapy
  - ◆ Once PET/CT shows no remaining FDG-avid lesions, additional PET imaging is not indicated unless conventional imaging studies are inconclusive and acute treatment decisions will be made based on PET results.
  - ◆ PET/CT is not supported for routine surveillance of ECD

## References

1. McClain KL, Allen CE, Hicks MJ. Histiocytic diseases. In: Pizzo PA, Poplack DG, eds. Principles and Practice of Pediatric Oncology. 7th ed. Philadelphia, PA: Wolters Kluwer; 2016:617-627.
2. Degar BA, Fleming MD, Rollins BJ, et al. Histiocytoses. In: Orkin SH, Fisher DE, Ginsburg D, Look AT, Lux SE, Nathan DG, eds. Nathan and Oski's Hematology and Oncology of Infancy and Childhood. 8th ed. Philadelphia, PA: Elsevier Saunders; 2015:2100-2122.
3. Haupt R, Minkov M, Astigarraga I, et al. Langerhans cell histiocytosis (LCH): guidelines for diagnosis, clinical work-up, and treatment for patients till the age of 18 years. *Pediatr Blood Cancer*. 2013;60(2):175-184. doi:10.1002/pbc.24367.
4. Chandrakasan S, Filipovich AH. Hemophagocytic Lymphohistiocytosis: advances in pathophysiology, diagnosis, and treatment. *J Pediatr*. 2013;163(5):1253-1259. doi:10.1016/j.jpeds.2013.06.053.
5. Phillips M, Allen C, Gerson P, et al. Comparison of FDG-PET scans to conventional radiography and bone scans in management of Langerhans cell histiocytosis. *Pediatr Blood Cancer*. 2009;52(1):97-101. doi:10.1002/pbc.21782.
6. Chellapandian D, Shaiki F, van den Bos C, et al. Management and outcome of patients with langerhans cell histiocytosis and single-bone CNS-risk lesions: a multi-institutional retrospective study. *Pediatr Blood Cancer*. 2015;62(12):2162-2166. doi:10.1002/pbc.25645.
7. Allen CE, Ladisch S, McClain KL. How I treat Langerhans cell histiocytosis. *Blood*. 2015;126(1):26-35. doi:10.1182/blood-2014-12-569301.
8. Schram AM, Berliner N. How I treat Hemophagocytic lymphohistiocytosis in the adult patient. *Blood*. 2015;125(19):2908-2914. doi:10.1182/blood-2015-01-551622.
9. Weitzman S, Jaffe R. Uncommon histiocytic disorders: the non-Langerhans cell histiocytoses. *Pediatr Blood Cancer*. 2005;45(3):256-264. doi:10.1002/pbc.20246.
10. Diamond EL, Dagna L, Hyman DM, et al. Consensus guidelines for the diagnosis and clinical management of Erdheim-Chester disease. *Blood*. 2014;124(4):483-492. doi:10.1182/blood-2014-03-561381.
11. Go RS, Jacobsen E, Baiocchi R, et. al. National Comprehensive Cancer Network (NCCN) Guidelines Version 1.2022 – May 20, 2022. Histiocytic Neoplasms, available at: [https://www.nccn.org/professionals/physician\\_gls/pdf/histiocytic\\_neoplasms.pdf](https://www.nccn.org/professionals/physician_gls/pdf/histiocytic_neoplasms.pdf) Referenced with permission from the NCCN Clinical Practice Guidelines in Oncology (NCCN Guidelines™) for Histiocytic Neoplasms V1.2022 – May 20, 2022. ©2022 National Comprehensive Cancer Network, Inc. All rights reserved. The NCCN Guidelines™ and illustrations herein may not be reproduced in any form for any purpose without the express written permission of the NCCN. To view the most recent and complete version of the NCCN Guidelines™, go online to NCCN.org.
12. Salama HA, Jazieh AR, Alhejazi AY, et. al. Highlights of the management of adult histiocytic disorders: Langerhans cell histiocytosis, Erdheim-Chester disease, Rosai-Dorfman disease, and hemophagocytic lymphohistiocytosis. *Clinical Lymphoma, Myeloma & Leukemia*. 2020;21(1):e66-75. doi:10.1016/j.dml.2020.08.007.
13. Goyal G, Young JR, Koster MJ, et. al. The Mayo Clinical Histiocytosis Working Group consensus statement for the diagnosis and evaluation of adult patients with histiocytic neoplasms: Erdheim-Chester disease, Langerhans cell histiocytosis, and Rosai-Dorfman disease. *Mayo Clin Proc*. 2019;94(10):2054-2071. doi:10.1016/j.mayocp.2019.02.023.
14. Allen CE, Merad M, McClain KL. Langerhans-Cell histiocytosis. *N Engl J Med*. 2018;379:856-68. doi:10.1056/NEJMra1607548.
15. Ablu O, Jacobsen E, Picarsic J, et. al. consensus recommendations for the diagnosis and clinical management of Rosai-Dorfman-Destombes disease. *Blood*. 2018;131(26):2877-2890. doi:10.1182/blood-2018-03-839753.
16. Ferrell J, Sharp S, Kumar A, Jordan M, Picarsic J, Nelson A. Discrepancies between F-18-FDG PET/CT findings and conventional imaging in Langerhans cell histiocytosis. *Pediatr Blood Cancer*. 2021;68(4):e28891. doi:10.1002/pbc.28891.
17. Campbell KM, Shulman DS, Grier HE, DuBois SG. Role of bone marrow biopsy for staging new patients with Ewing sarcoma: A systematic review. *Pediatr Blood Cancer*. 2021 Feb;68(2):e28807. doi: 10.1002/pbc.28807. Epub 2020 Nov 21. PMID: 33219750.

## **Long Term Pediatric Cancer Survivors (PEDONC-19)**

**Long Term Pediatric Cancer Survivors – General Considerations (PEDONC-19.1)**

**Cardiotoxicity and Echocardiography (PEDONC-19.2)**

**Second Malignant Neoplasms (SMN) (PEDONC-19.3)**

**Osteonecrosis in Long Term Cancer Survivors (PEDONC-19.4)**

**CNS vascular changes in pediatric cancer survivors following CNS radiation (PEDONC-19.5)**

## **Long Term Pediatric Cancer Survivors – General Considerations (PEDONC-19.1)**

- This section applies to individuals who have passed the end of the surveillance imaging period for their specific cancer, or 5 years after completion of therapy, whichever occurs first
- As these are long term survivors, many individuals falling under this guideline section will have reached adult age. However, these guidelines relate specifically to late effects of childhood cancer treatment and should be applied to all long term childhood cancer survivors regardless of current age
- The Children’s Oncology Group has published comprehensive guidelines for the management of long-term childhood cancer survivors, and these are available at: <http://www.survivorshipguidelines.org>
- A summary of cancer treatment should be available for all individuals in this category and should generally include, at minimum:
  - ◆ Type of cancer and stage
  - ◆ Dates of diagnosis, recurrence, cancer-related surgeries, beginning and end dates of chemotherapy, radiotherapy, and/or stem cell transplant
  - ◆ Protocol number used for treatment and cumulative chemotherapy drug dose exposures
  - ◆ Cumulative radiation dose, fraction number, modality, and field exposure
- Annual detailed history and complete physical examination is a critical component of cancer survivorship care and along with laboratory testing serves as the primary method of screening for the majority of late effects
- Advanced imaging for asymptomatic screening is not routinely indicated except as specified in this section
- Imaging requests related to new clinical signs or symptoms in a long term cancer survivor not explicitly covered in this section should be reviewed according to the guideline for the individual’s cancer type or the relevant non-malignant clinical problem



## Cardiotoxicity and Echocardiography (PEDONC-19.2)

- Screening echocardiography (CPT® 93306, CPT® 93307, or CPT® 93308) for life after exposure to anthracycline chemotherapy, cardiotoxic immunotherapy, or cardiac exposure to radiotherapy

SCREENING ECHOCARDIOGRAM INDICATIONS			
Age at time of Exposure	Cumulative Doxorubicin Equivalent Dose	Cumulative radiation dose to cardiac muscle	Echocardiogram frequency
All ages	None	None	None
0-0.99 years	≥250 mg/m <sup>2</sup>	None	Annual
	0-249 mg/m <sup>2</sup>	Any dose	Annual
	0-249 mg/m <sup>2</sup>	None	Every 2 years
1-4.99 years	≥250 mg/m <sup>2</sup>	Any dose	Annual
	0-249 mg/m <sup>2</sup>	15+ Gy	Annual
	None	0-14.99 Gy	Every 2 years
		35+ Gy	Annual
		15-34.99 Gy	Every 2 years
		0-14.99 Gy	Every 5 years
5+ years	≥250 mg/m <sup>2</sup>	Any dose	Every 2 years
	0-249 mg/m <sup>2</sup>	15+ Gy	Every 2 years
		0-14.99 Gy	Every 5 years
	None	35+ Gy	Every 2 years
		15-34.99 Gy	Every 5 years
		0-14.99 Gy	None
All ages with known ventricular dysfunction			Annual

- Stress echocardiography is not indicated as a screening study for anthracyclines cardiotoxicity in the absence of coronary artery disease symptoms. See: **Stress Testing with Imaging – Indications (CD-1.4)** for imaging guidelines.
- Female cancer survivors who are pregnant or planning to become pregnant:
  - ◆ If any of the following are present, echocardiogram is recommended as a baseline exam and in the 3<sup>rd</sup> trimester, and as clinically indicated for symptoms (see: **Pregnancy – Maternal Imaging (CD-11.4)** in the Cardiology Imaging Guidelines) if ANY of the following are present:
    - Anthracycline or cardiotoxic chemotherapy/immunotherapy exposure
    - Chest radiotherapy

### Background and Supporting Information

- Exposure to cardiotoxic anthracycline chemotherapy agents is common in pediatric oncology due to the high success rate of this drug class in the treatment of pediatric cancers.
- Cardiac risk is assessed based on the age of the individual at the time of treatment initiation, the cumulative drug exposure expressed as doxorubicin equivalent mg/m<sup>2</sup>, and the presence or absence of radiotherapy exposure to cardiac muscle.

## **Second Malignant Neoplasms (SMN) (PEDONC-19.3)**

### **SMN—Breast Cancer:**

Clinical breast exam every 6 months supplemented with:

- MRI Breast (CPT® 77049) annually and annual mammogram beginning at age 25 or 8 years after completion of radiotherapy (whichever occurs later- screening breast MRI is not supported prior to age 25) for individuals who received therapeutic radiation exposure in the following fields while they were under 30 years of age:
  - ◆ Chest (thorax)
  - ◆ Whole lung
  - ◆ Mediastinal
  - ◆ Axilla
  - ◆ Mini-mantle, mantle, or extended mantle
  - ◆ Total (TLI) or subtotal (SLTI) lymphoid irradiation
  - ◆ Total body irradiation (TBI)

### **MN – CNS Tumors:**

- Routine surveillance of asymptomatic individuals with normal neurologic exams is not supported by evidence, with the exception of NF1 and NF2 below:
  - ◆ MRI Brain without and with contrast (CPT® 70553) can be approved every 2 years after completion of radiotherapy for individuals with NF1 or NF2
- MRI Brain without and with contrast (CPT® 70553) for any individual with history of brain radiotherapy and new neurologic symptoms, including simple headache
- MRI Cervical (CPT® 72156), Thoracic (CPT® 72157), and Lumbar Spine (CPT® 72158) without and with contrast for any individual with history of spine radiotherapy and new neurologic symptoms including change in quality of pain
  - ◆ MRI Spine can be performed with contrast only (Cervical-CPT® 72142, Thoracic-CPT® 72147, Lumbar-CPT® 72149) if being performed immediately following a contrast-enhanced MRI Brain
- MRI Brain without and with contrast (CPT® 70553) annually for individuals with history of brain radiotherapy and persistent neurologic symptoms
- MRI Cervical (CPT® 72156), Thoracic (CPT® 72157), and Lumbar Spine (CPT® 72158) without and with contrast annually for individuals with history of spine radiotherapy and persistent neurologic symptoms
  - ◆ MRI Spine can be performed with contrast only (Cervical-CPT® 72142, Thoracic-CPT® 72147, Lumbar-CPT® 72149) if being performed immediately following a contrast-enhanced MRI Brain

### **SMN—Colorectal Cancer**

- No advanced imaging is currently recommended. See: **Background and Supporting Information** section for recommended surveillance

### **Background and Supporting Information**

- SMN—Breast Cancer:
  - ◆ Clinical breast exam every 6 months supplemented with advanced imaging
- SMN-CNS Tumors:
  - ◆ These are associated with radiation exposure to the brain and with neurofibromatosis
  - ◆ Routine surveillance of asymptomatic individuals with normal neurologic exams is not supported by evidence, with the exception of NF1 and NF2 listed above
- SMN—Colorectal Cancer:
  - ◆ Colonoscopy is recommended every 5 years beginning at age 30 or 5 years after radiation exposure (whichever is later) for individuals with  $\geq 30$  Gy radiation exposure to the following fields:
    - Thoracic, Lumbar, Sacral, or Whole Spine
    - Abdomen
    - Pelvis
    - Total body irradiation (TBI)
  - Colonoscopy is also recommended every 5 years beginning at age 30 or 5 years after radiation exposure (whichever is later) for individuals with:
  - Personal history of ulcerative colitis, GI malignancy, adenomatous polyps, or hepatoblastoma
  - Familial polyposis
    - Family history of colorectal cancer or polyps in a first degree (parent or sibling) relative
  - While the American Cancer Society recently added computed tomographic colonography (CTC) (AKA “Virtual Colonoscopy”) as an acceptable option for colorectal cancer screening of average-risk adults, the National Comprehensive Cancer Network and United States Preventive Services Task Force concluded that data was too premature to warrant its use in screening. Colonoscopy remains the preferred screening modality for survivors at highest risk of colorectal cancer

### **Osteonecrosis in Long Term Cancer Survivors (PEDONC-19.4)**

Osteonecrosis is associated with corticosteroid, chemotherapy, and radiation exposure during treatment for ALL, NHL, and allogeneic HSCT in pediatrics. Osteonecrosis occurs primarily in hips, knees, and ankles and is frequently multifocal.

Osteoradionecrosis of the jaw can occur in individuals receiving radiotherapy to the mandible or maxilla; those receiving  $\geq 40$  Gy are at highest risk. Although unusual, it can also occur in any bone without symptoms. It is rare in other disease types.

- Plain films of symptomatic areas are indicated prior to advanced imaging.
- Routine bone density screening using DEXA or Quantitative CT screening has not been well normalized in the pediatric population, but imaging can be approved for those with symptoms to suggest bone density issues
  - ◆ DEXA or Quantitative CT screening is generally not recommended until age 18 unless a specific intervention will be planned based on the imaging results.

- Serial advanced imaging is not indicated in osteonecrosis without specific documentation regarding how the advanced imaging will change current individual management
  - ◆ When advanced imaging is necessary for acute management decisions, MRI without contrast of the affected joint(s) can be approved.
  - ◆ Surveillance imaging of asymptomatic individuals to detect osteonecrosis has not been shown to impact individual outcomes, and it is not standard to alter treatment based on imaging findings alone without symptoms.
    - Follow up MRI of incidentally discovered osteonecrosis findings in asymptomatic individuals has not been shown to impact individual outcomes and is not necessary
- See: **Acute Lymphoblastic Leukemia (ALL) (PEDONC-3.2)** for information on imaging osteonecrosis in ALL individuals during active treatment.

### **CNS vascular changes in pediatric cancer survivors following CNS radiation (PEDONC-19.5)**

Children receiving cranial radiation are at increased risk of cerebrovascular complications, including: hemorrhagic and ischemic stroke, moyamoya, occlusive vasculopathy, and cavernomas. These complications may occur months to years after radiation exposure.

- MRI Brain without and with contrast (CPT® 70553) and MRA Head (CPT® 70544, 70545, or 70546) for all individuals of any age with new neurologic symptoms or headache and a history of cranial irradiation.
- MRI Brain without and with contrast (CPT® 70553) and MRA Head (CPT® 70544, 70545, or 70546) may be approved annually for 10 years post treatment in individuals with a history of cranial irradiation and any of the following additional risk factors:
  - ◆ Down Syndrome, Sickle cell disease, or Neurofibromatosis 1 or 2
  - ◆ Parasellar or suprasellar tumors (i.e. craniopharyngioma)
  - ◆ Radiation dose >50 Gy
  - ◆ Radiation field involving Circle of Willis

### ***References***

1. Landier W, Armenian SH, Meadows AT, et al. Late effects of childhood cancer and its treatment. In: Pizzo PA, Poplack DG, eds. Principles and Practice of Pediatric Oncology. 7th ed. Philadelphia, PA: Wolters Kluwer; 2016:1173-1196.
2. Vrooman L, Diller L, and Kenney LB. Childhood cancer survivorship. In: Orkin SH, Fisher DE, Ginsburg D, Look AT, Lux SE, Nathan DG, eds. Nathan and Oski's Hematology and Oncology of Infancy and Childhood. 8th ed. Philadelphia, PA: Elsevier Saunders; 2015:2397-2434.
3. Children's Oncology Group. Long-term follow up guidelines for survivors of childhood, adolescent and young adult cancers, version 5.0. Monrovia, CA: Children's Oncology Group; October 2018; Available on-line: [www.survivorshipguidelines.org](http://www.survivorshipguidelines.org)
4. Ryerson AB, Border WL, Wasilewski-Masker K, et al. Assessing anthracycline-treated childhood cancer survivors with advanced stress echocardiography. *Pediatr Blood Cancer*. 2015;62(3):502-508. doi:10.1002/pbc.25328.
5. Tieu MT, Cigsar C, Ahmed S, et al. Breast cancer detection among young survivors of pediatric Hodgkin lymphoma with screening magnetic resonance imaging. *Cancer*. 2014;120(16):2507-2513. doi:10.1002/cncr.28747.
6. Lange JM, Takashima JR, Peterson SM, Kalapurakal JA, Green DM, Breslow NE. Breast cancer in female survivors of Wilms tumor: a report from the national Wilms tumor late effects study. *Cancer*. 2014;120(23):3722-3730. doi:10.1002/cncr.28908.

7. Bevers TB, Helvie M, Bonaccio E, et al. National Comprehensive Cancer Network (NCCN) Guidelines Version 1.2022—June 2, 2022, Breast Cancer Screening and Diagnosis, available at: [https://www.nccn.org/professionals/physician\\_gls/pdf/breast-screening.pdf](https://www.nccn.org/professionals/physician_gls/pdf/breast-screening.pdf). Referenced with permission from the NCCN Clinical Practice Guidelines in Oncology (NCCN Guidelines™) for Breast Cancer Screening and Diagnosis V1.2022 06/02/2022. ©2022 National Comprehensive Cancer Network, Inc. All rights reserved. The NCCN Guidelines™ and illustrations herein may not be reproduced in any form for any purpose without the express written permission of the NCCN. To view the most recent and complete version of the NCCN Guidelines™, go online to NCCN.org.
8. Recht M, Mostoufi-Moab S, McFadden J, et al. Bone health in pediatric hematology-oncology. In: American Society of Pediatric Hematology/Oncology Annual Meeting. Chicago; 2014.
9. Bhatia S, Armenian SH, Armstrong GT, et al. Collaborative research in childhood cancer survivorship: the current landscape. *J Clin Oncol*. 2015;33(27):3055-3064. doi:10.1200/JCO.2014.59.8052.
10. Chavhan GB, Babyn PS, Nathan PC, Kaste SC. Imaging of acute and subacute toxicities of cancer therapy in children. *Pediatr Radiol*. 2016;46(1):9-20. doi:10.1007/s00247-015-3454-1.
11. Karol SE, Mattano LA, Yang W, et al. Genetic risk factors for the development of osteonecrosis in children under age 10 treated for acute lymphoblastic leukemia. *Blood Journal*. 2016;127(5):558-564. doi:10.1182/blood-2015-10-673848.
12. Marcucci G, Beltrami G, Tamburini A, et al. Bone health in childhood cancer: review of the literature and recommendations for the management of bone health in childhood cancer survivors. *Ann Oncol*. 2019;30:908-920. doi:10.1093/annonc/mdz120.
13. Sanders LM, Sharma S, El Madany M, King AB, Goodman KS, Sanders AE. Clinical breast concerns in low-risk pediatric patients: practice review with proposed recommendations. *Pediatr Radiol*. 2018(48):186–195. doi:10.1007/s00247-017-4007-6.
14. Murphy ES, Xie H, Merchant TE, Yu JS, Chao ST, Suh JH. Review of cranial radiotherapy-induced vasculopathy. *J Neurooncol*. 2015;122(3):421-9. doi:10.1007/s11060-015-1732-2. Epub 2015 Feb 12.
15. Baumgartner JE, Ater JL, Ha CS, et. al. Pathologically proven cavernous angiomas of the brain following radiation therapy for pediatric brain tumors. *Pediatr Neurosurg*. 2003;39(4):201-7. doi:10.1159/000072472.
16. Di Giannatale A, Morana G, Rossi A, et. al. Natural history of cavernous malformations in children with brain tumors treated with radiotherapy and chemotherapy. *J Neurooncol*. 2014;117(2):311-20. doi:10.1007/s11060-014-1390-9. Epub 2014 Feb 11.
17. Bowers DC, Liu Y, Leisenring W, et. al. Late-occurring stroke among long-term survivors of childhood leukemia and brain tumors: a report from the Childhood Cancer Survivor Study. *J Clin Oncol*. 2006;24:5277–5282.
18. Morris B, Partap S, Yeom K, Gibbs IC, Fisher PG, King AA. Cerebrovascular disease in childhood cancer survivors: a Children's Oncology Group report. *Neurology*. 2009;73:1906–1913
19. Laitt RD, Chambers EJ, Goddard PR, Wakeley CJ, Duncan AW, Foreman NK. Magnetic resonance imaging and magnetic resonance angiography in long term survivors of acute lymphoblastic leukemia treated with cranial irradiation. *Cancer*. 1995;76:1846–1852
20. Gastelum E, Sear K, Hills N, et. al. Rates and characteristics of radiographically detected intracerebral cavernous malformations after cranial radiation therapy in pediatric cancer patients. *J Child Neurol*. 2015;30(7):842–849. doi:10.1177/0883073814544364.
21. ACR-ASNR-SPR Practice Parameter for the Performance and Interpretation of Cervicocerebral Computed Tomography (CTA). (Resolution 42). 2020.
22. Rao SS, El Abiad JM, Puvanesarajah V, Levin AS, Jones LC, Morris CD. Osteonecrosis in pediatric cancer survivors: epidemiology, risk factors, and treatment. *Surgical Oncology*. 2019;28:214-221. doi:10.1016/j.suronc.2019.02.001.
23. Nordstrom M, Felton E, Sear K, et. al. Large vessel arteriopathy after cranial radiation therapy in pediatric brain tumor survivors. *J Child Neurol*. 2018;33(5):359-366. doi:10.1177/0883073818756729.

# Policy History and Instructions for Use

---

## Guideline

---

### Policy History and Instructions for Use

# Policy History and Instructions for Use

## Policy History and Instructions for Use V1.0.2023

### Instructions for Use

This Medical Policy provides assistance in interpreting United HealthCare Services, Inc. standard benefit plans. When deciding coverage, the federal, state (Ohio Administrative Code [OAC]) or contractual requirements for benefit plan coverage must be referenced as the terms of the federal, state (OAC) or contractual requirements for benefit plan coverage may differ from the standard benefit plan. In the event of a conflict, the federal, state (OAC) or contractual requirements for benefit plan coverage govern.

Before using this policy, please check the federal, state (OAC) or contractual requirements for benefit plan coverage. United HealthCare Services, Inc. reserves the right to modify its Policies and Guidelines as necessary. This Medical Policy is provided for informational purposes. It does not constitute medical advice.

United HealthCare Services, Inc. uses InterQual® for the primary medical/surgical criteria, and the American Society of Addiction Medicine (ASAM) for substance use, in administering health benefits. If InterQual® does not have applicable criteria, United HealthCare Services, Inc. may also use United HealthCare Services, Inc.'s Medical Policies, Coverage Determination Guidelines, and/ or Utilization Review Guidelines that have been approved by the Ohio Department for Medicaid Services. The United HealthCare Services, Inc.'s Medical Policies, Coverage Determination Guidelines, and Utilization Review Guidelines are intended to be used in connection with the independent professional medical judgment of a qualified health care provider and do not constitute the practice of medicine or medical advice.

### Policy History/Revision Information

Date	Summary of Changes
XX/XX/202X	
XX/XX/202X	